

Surgical Treatment of NSCLC

Multidisciplinary approach at special cases

D. Filippou MD, PhD
Cardiothoracic Surgeon
Head of
Cardiothoracic Department

A. Kleontas BSc, MD, MSc
Cardiothoracic Surgeon

4th SYMPOSIUM
LUNG CANCER:
FROM DIAGNOSIS
TO TREATMENT

ΟΑ ΧΟΡΗΓΗΘΟΥΝ
16 ΜΟΡΙΑ
ΣΥΝ ΕΚΔΟΜΕΝΗΣ
ΙΑΤΡΙΚΗΣ
ΕΚΠΑΙΔΕΥΣΗΣ
(CME-CPD)

> **HOTEL NIKOPOLIS ΘΕΣΣΑΛΟΝΙΚΗ 29-30 ΣΕΠΤΕΜΒΡΙΟΥ 2017**

ΟΡΓΑΝΩΣΗ ΥΠΟ ΤΗΝ ΑΙΓΙΔΑ ΓΡΑΜΜΑΤΕΙΑ ΣΥΝΕΔΡΙΟΥ

ΕΛΛΗΝΙΚΟ ΟΓΚΟΛΟΓΙΚΟ ΙΝΣΤΙΤΟΥΤΟ
ΥΠΟΣΤΗΡΙΞΗΣ ΑΣΘΕΝΩΝ

ΙΑΤΡΙΚΟ ΔΙΑΒΑΛΚΑΝΙΚΟ
ΘΕΣΣΑΛΟΝΙΚΗΣ

BINO Balkanian Investigation
Network Of Oncology

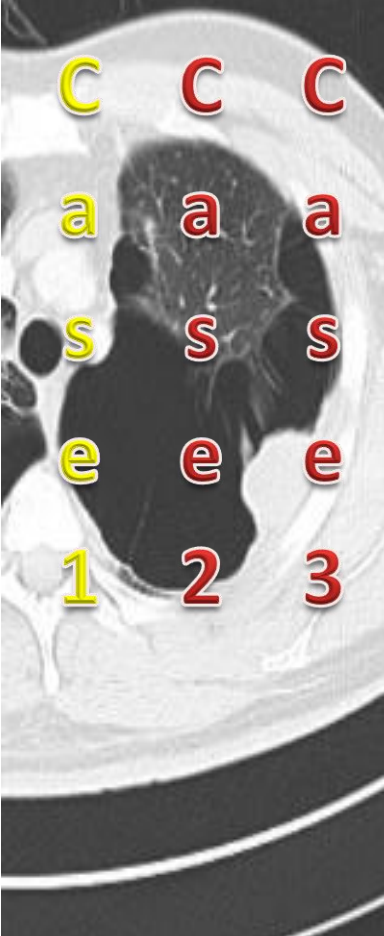GK

Tel.: 210 6887553
Fax: 210 6887555
E-mail: info@okg.gr
Site: www.okg.gr



Case 1

Male 39 y



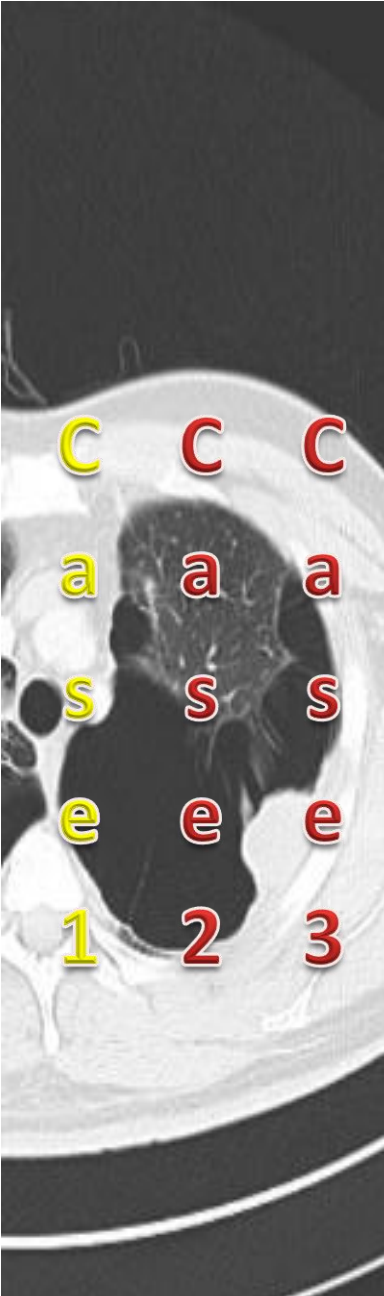
Chief Complain:

- Cholecystitis
- Tumor at LUL

Personal Medical History:

- Heavy smoker (40p/y)
- Pilot

Case 1



InterBalkan
255022

Ηλικία κατά την εξέταση: 39 years old

26/3/1978

Gantry: 0°

Time: 4117 ms

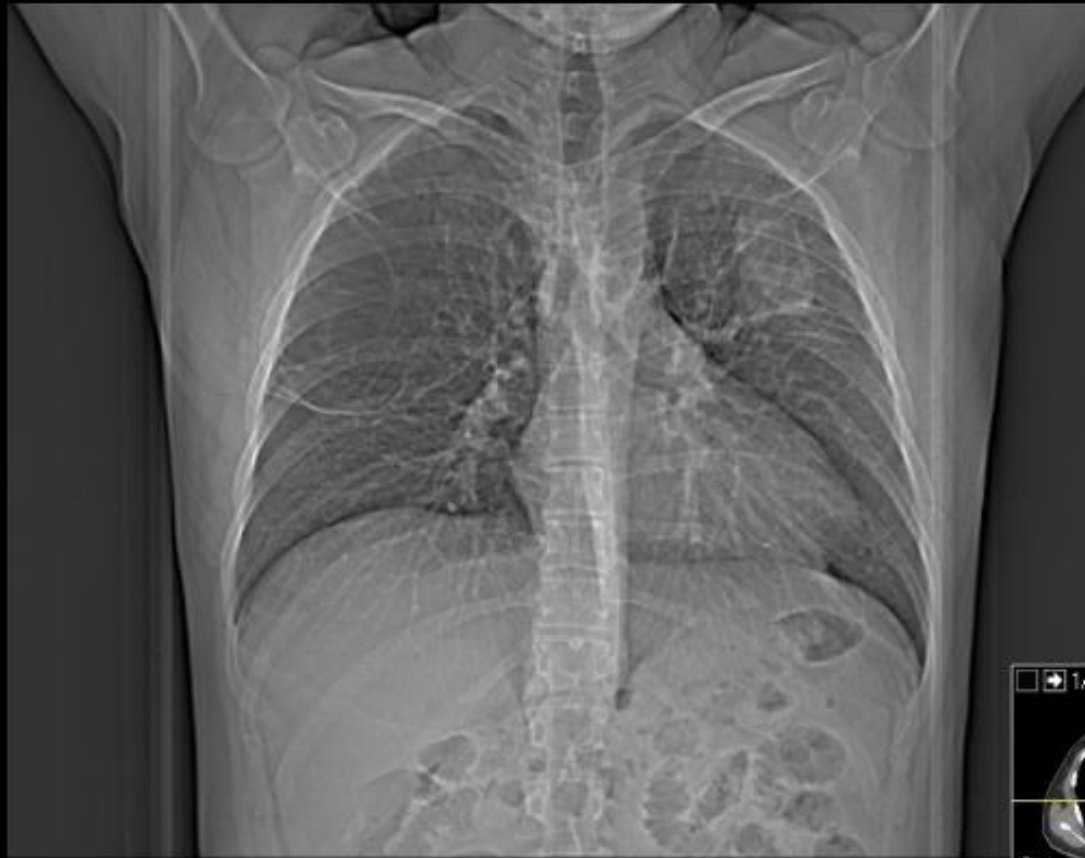Couch: 441

Pos: HFS

C: 50,0, W: 350,0

WINDOW1 1/8

Age: 39 years old



F: T20f

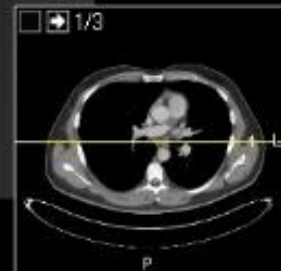
35 mA

120 kV

Image no: 1

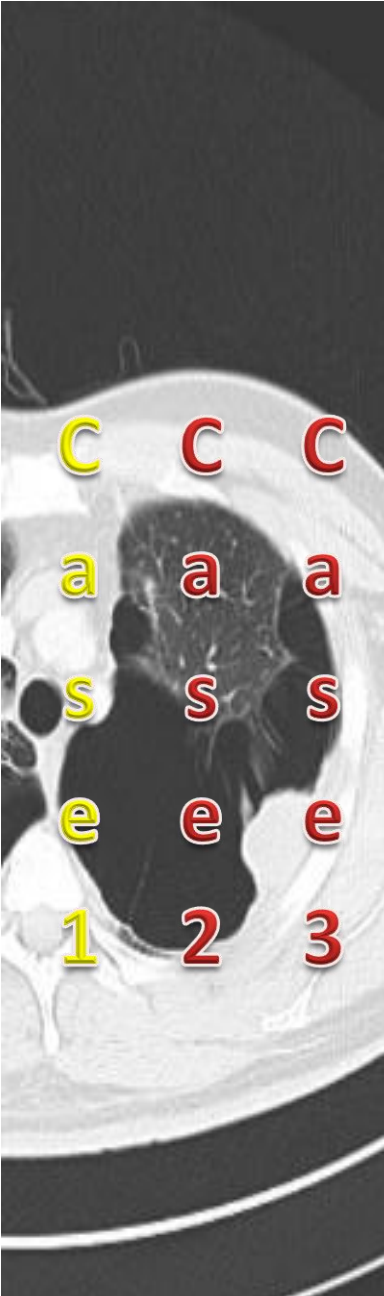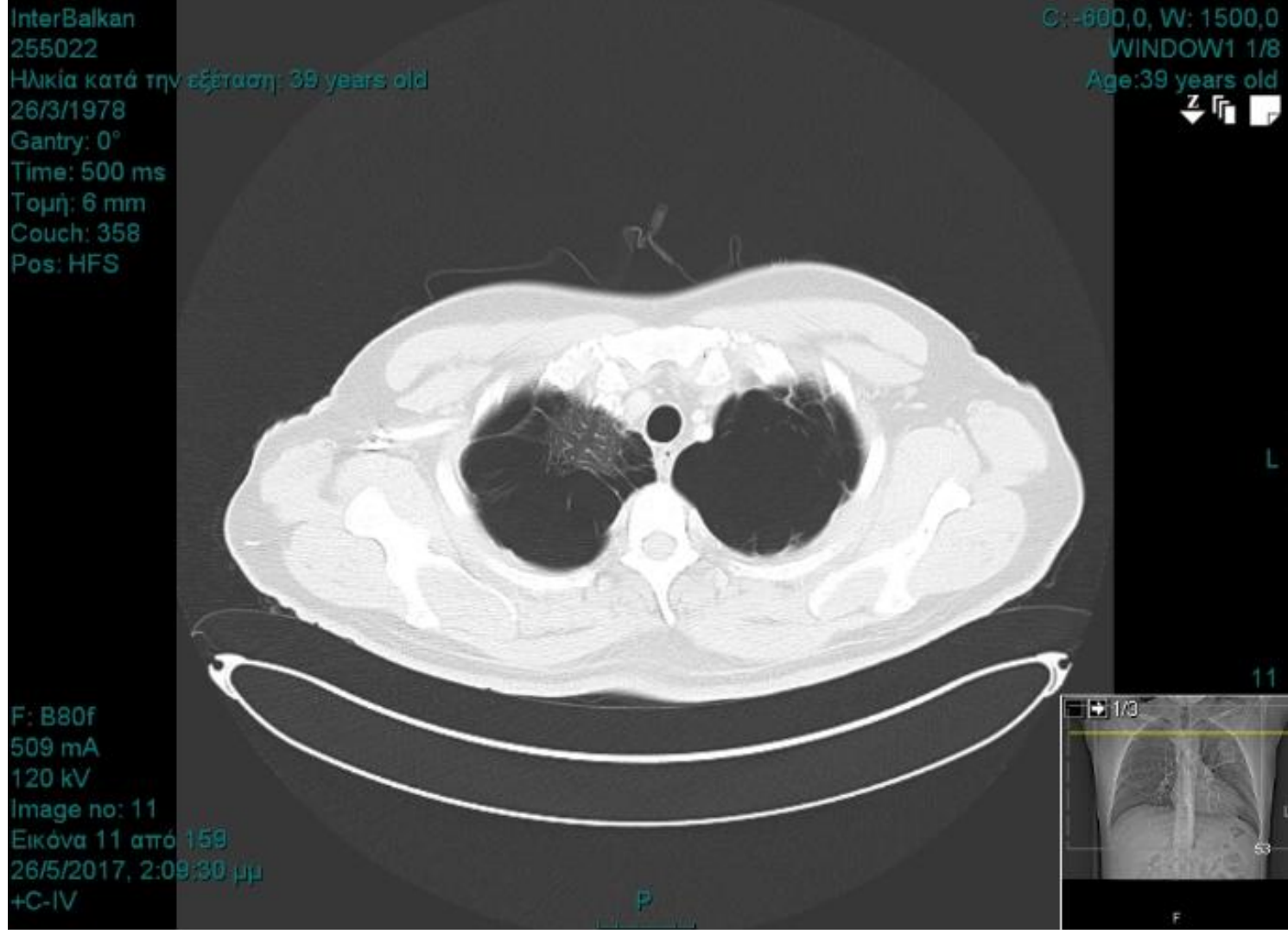
Εικόνα 1 από 6

26/5/2017, 2:08:20 μμ



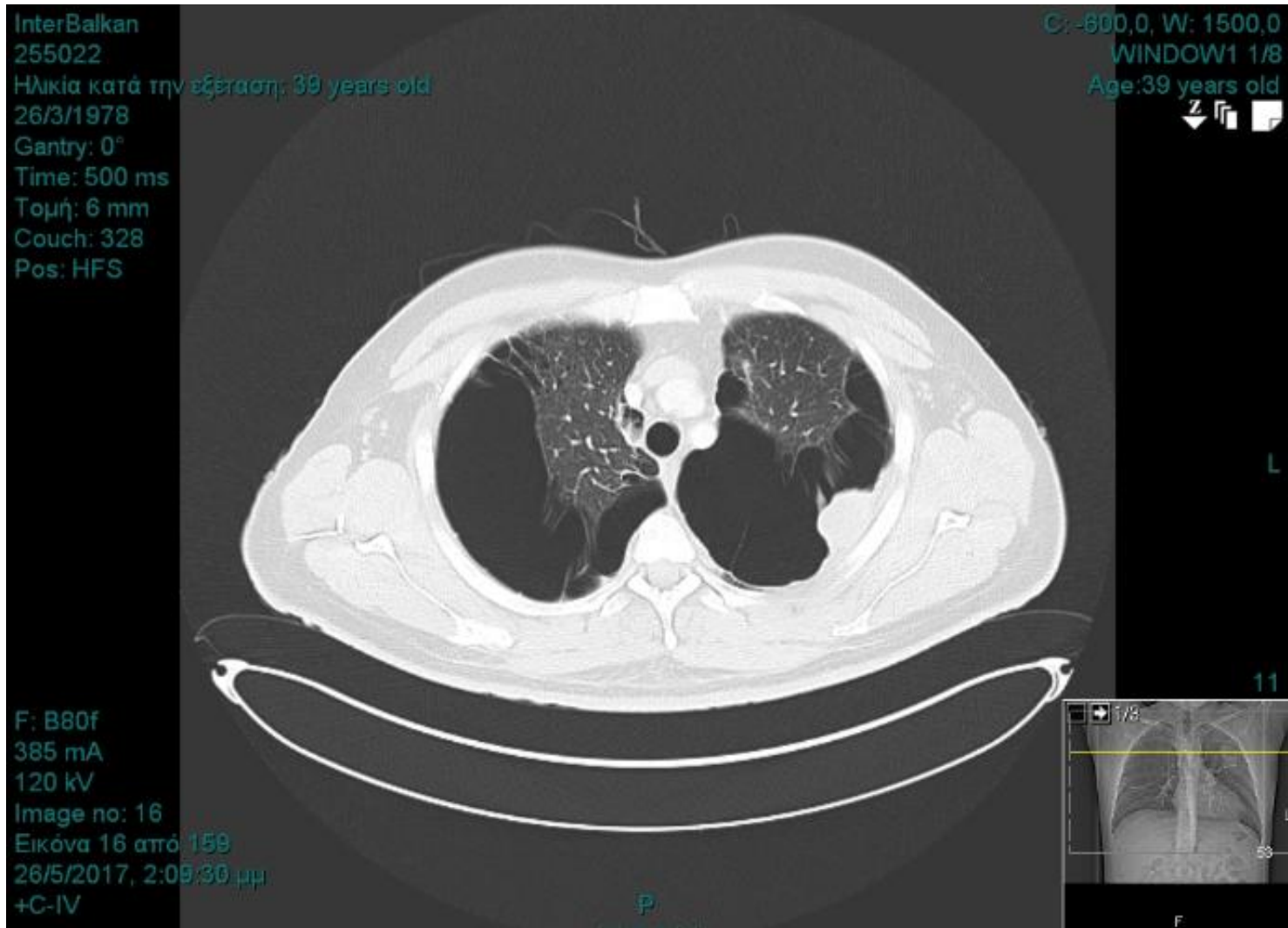
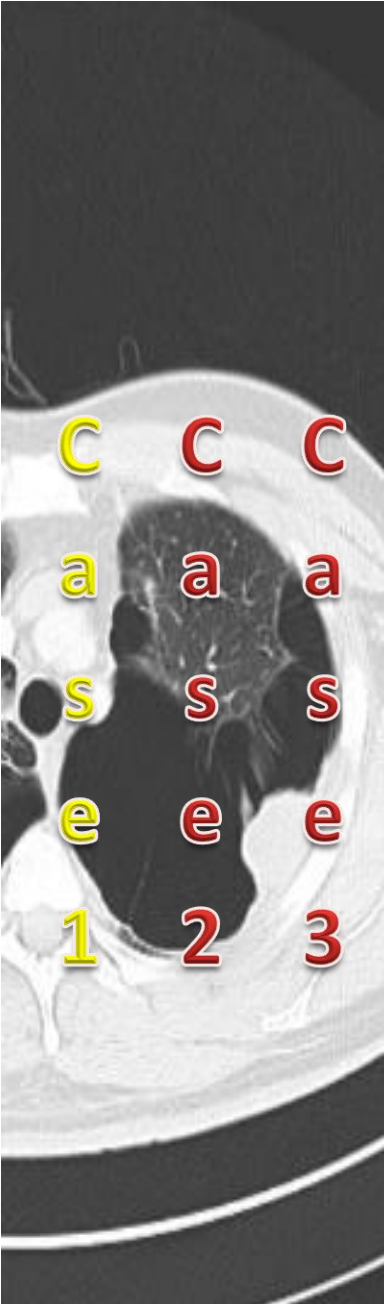
PreOp Chest X-ray (F)

Case 1



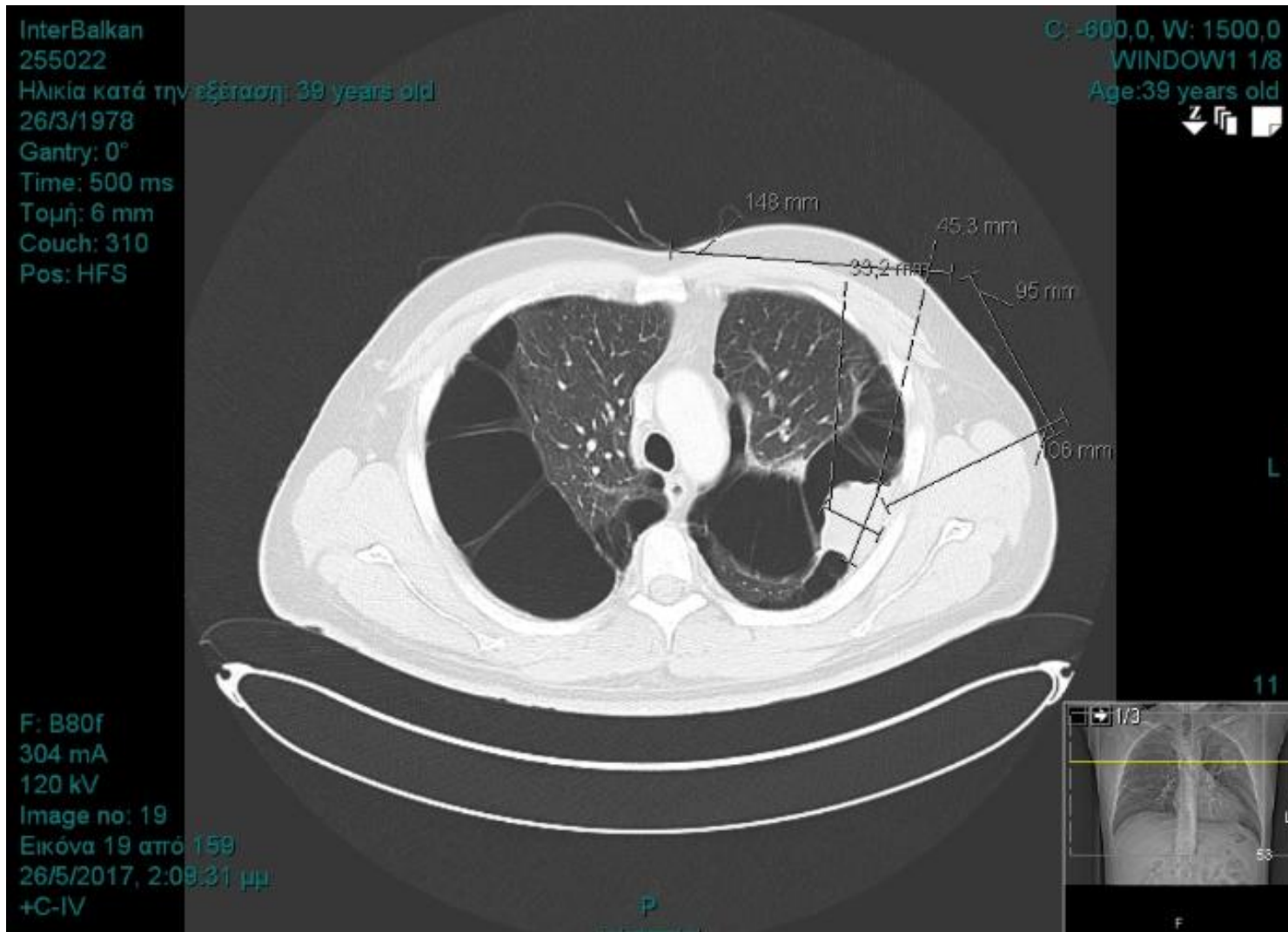
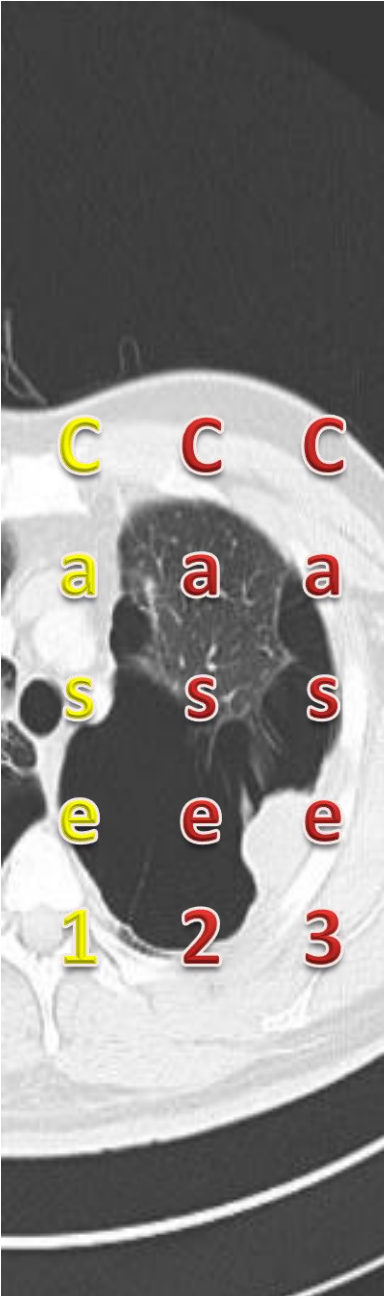
PreOp Chest CT Scan

Case 1



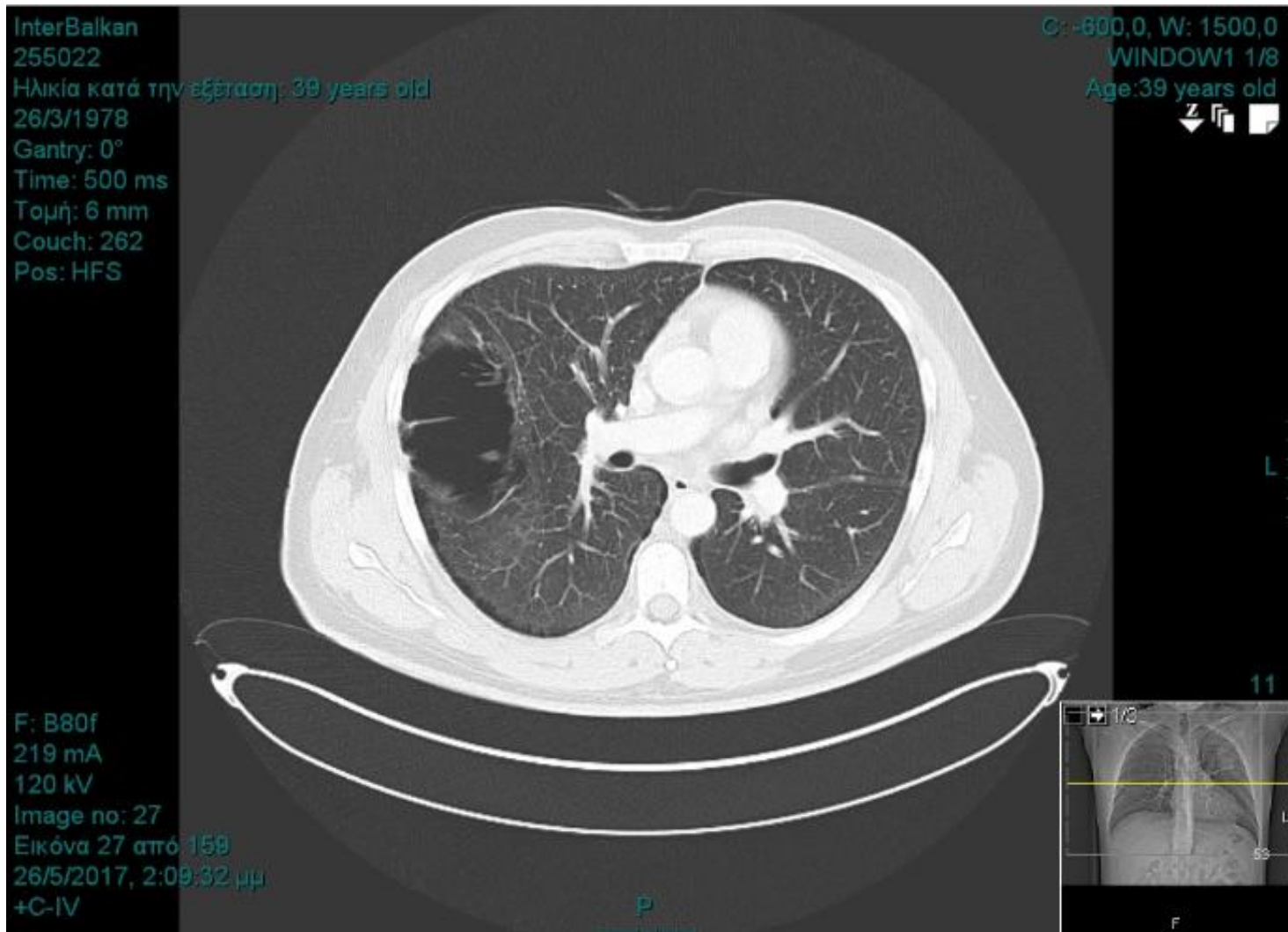
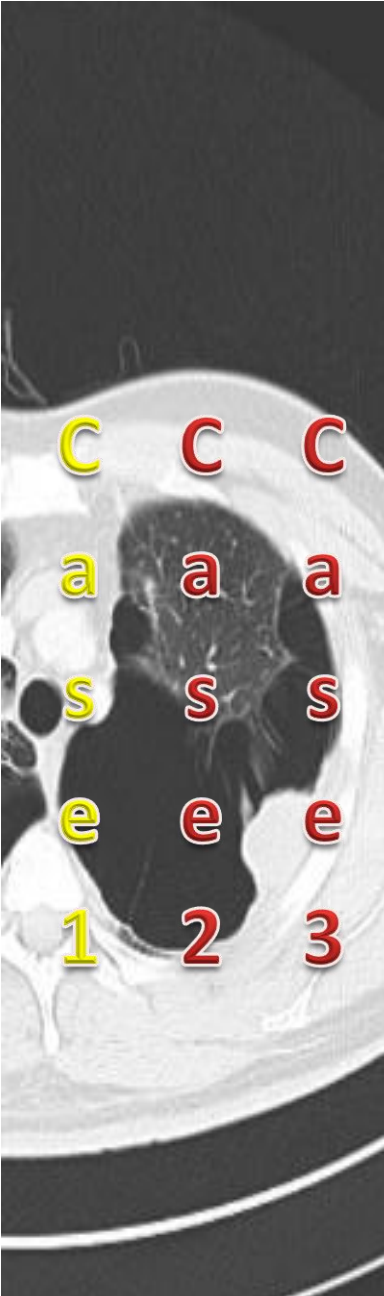
PreOp Chest CT Scan

Case 1



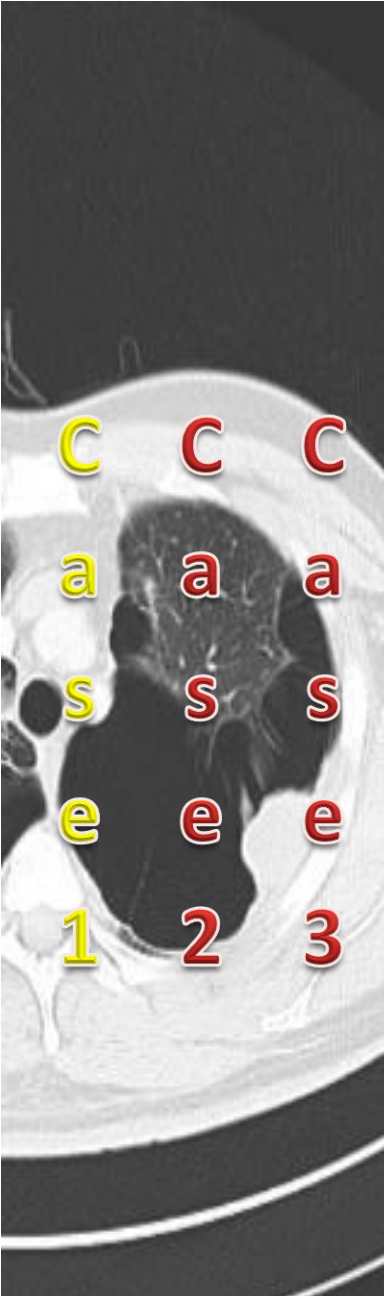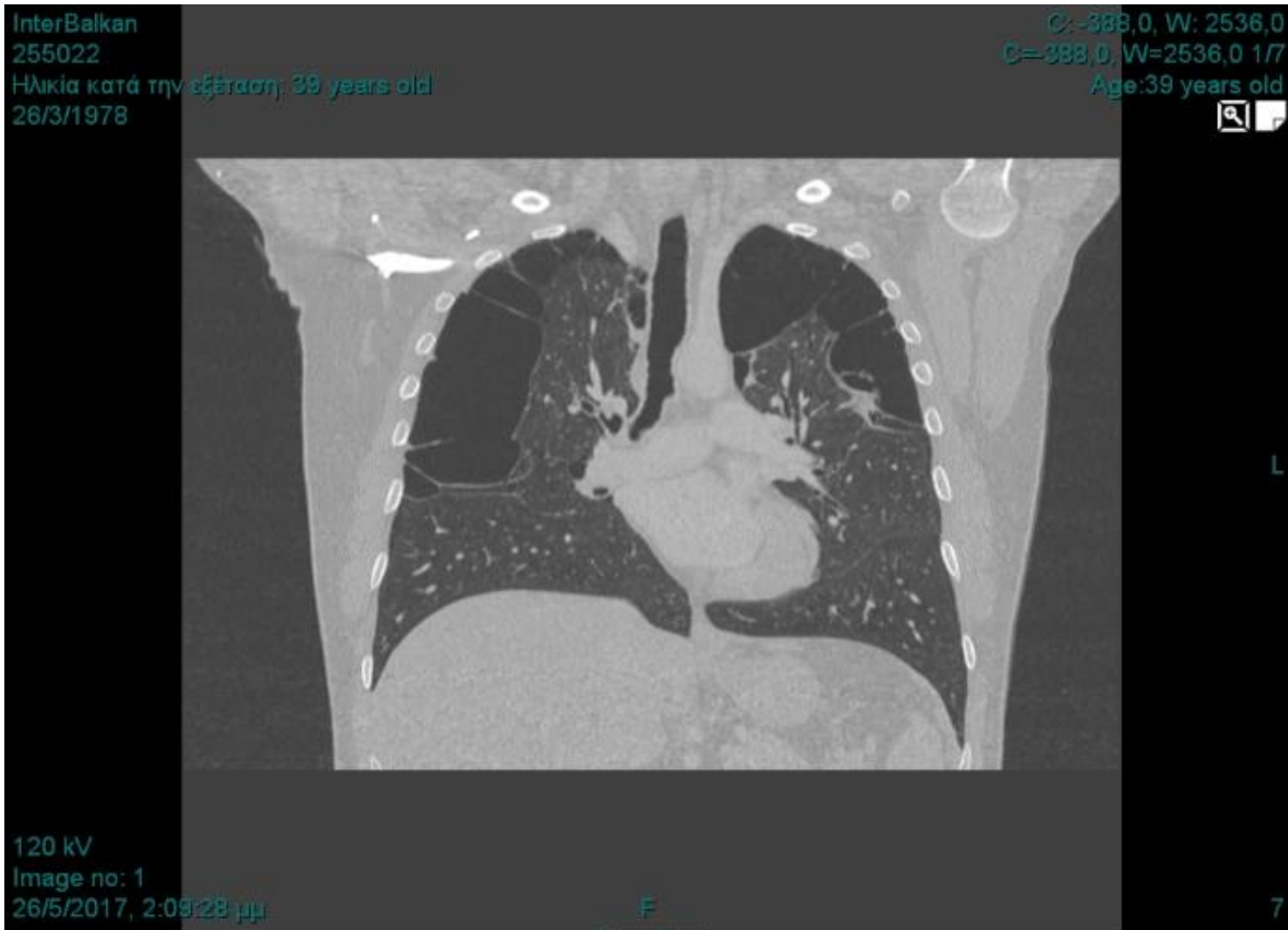
PreOp Chest CT Scan

Case 1



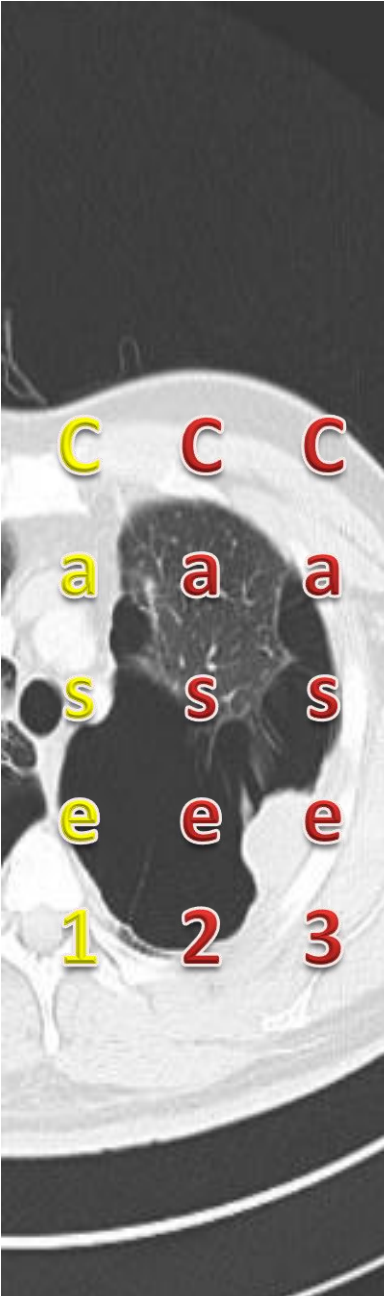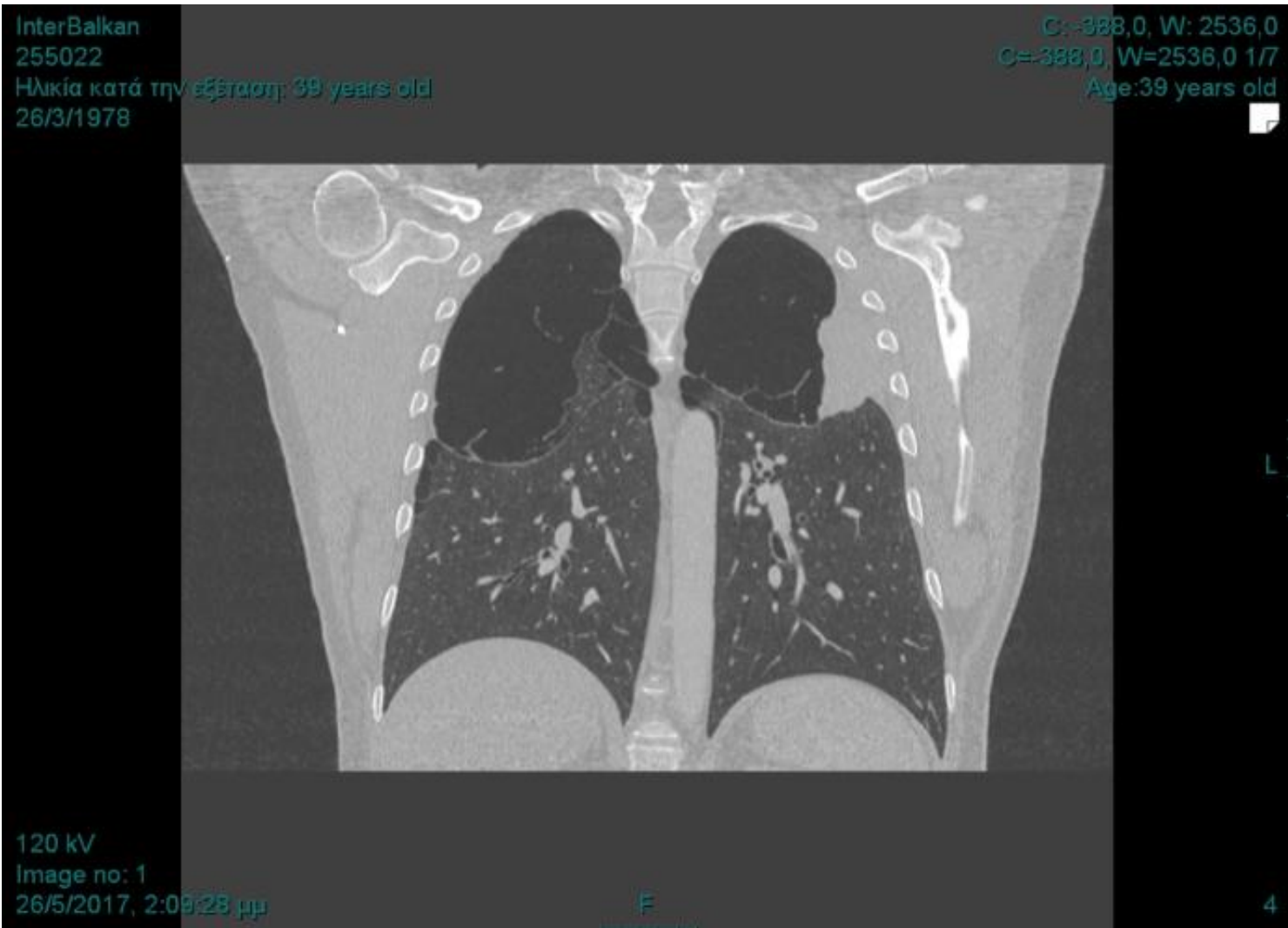
PreOp Chest CT Scan

Case 1



PreOp Chest CT Scan

Case 1



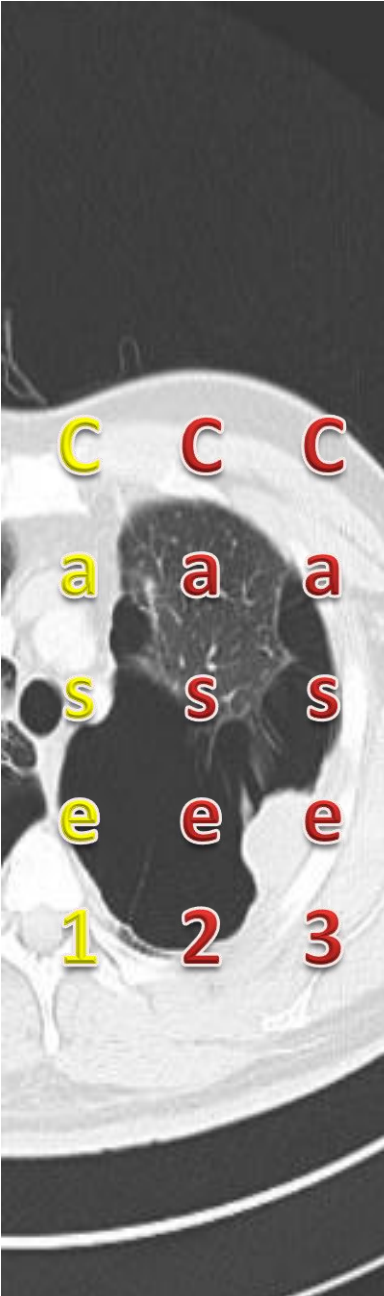
PreOp Chest CT Scan

Case 1

CT guided FNA biopsy



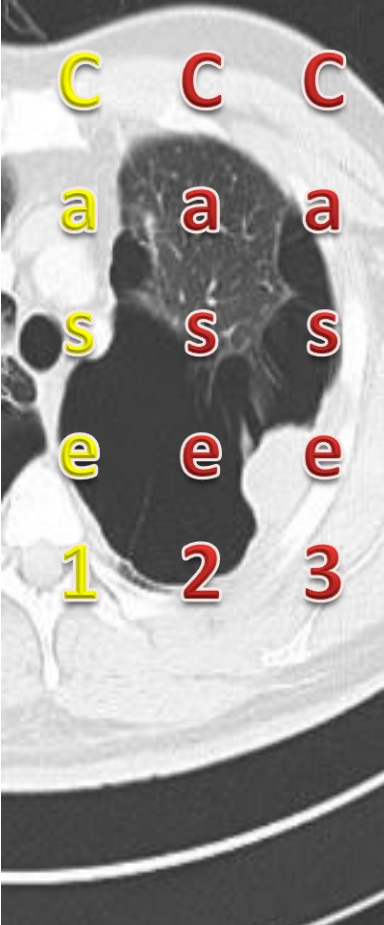Squamous NSCLC



Case 1

Treatment strategy

1. LUL lobectomy
2. LUL lobectomy & bullectomy
3. Bullectomy right & LUL lobectomy
4. Induction RT & LUL lobectomy
5. Induction CT/RT & LUL lobectomy



Case 1

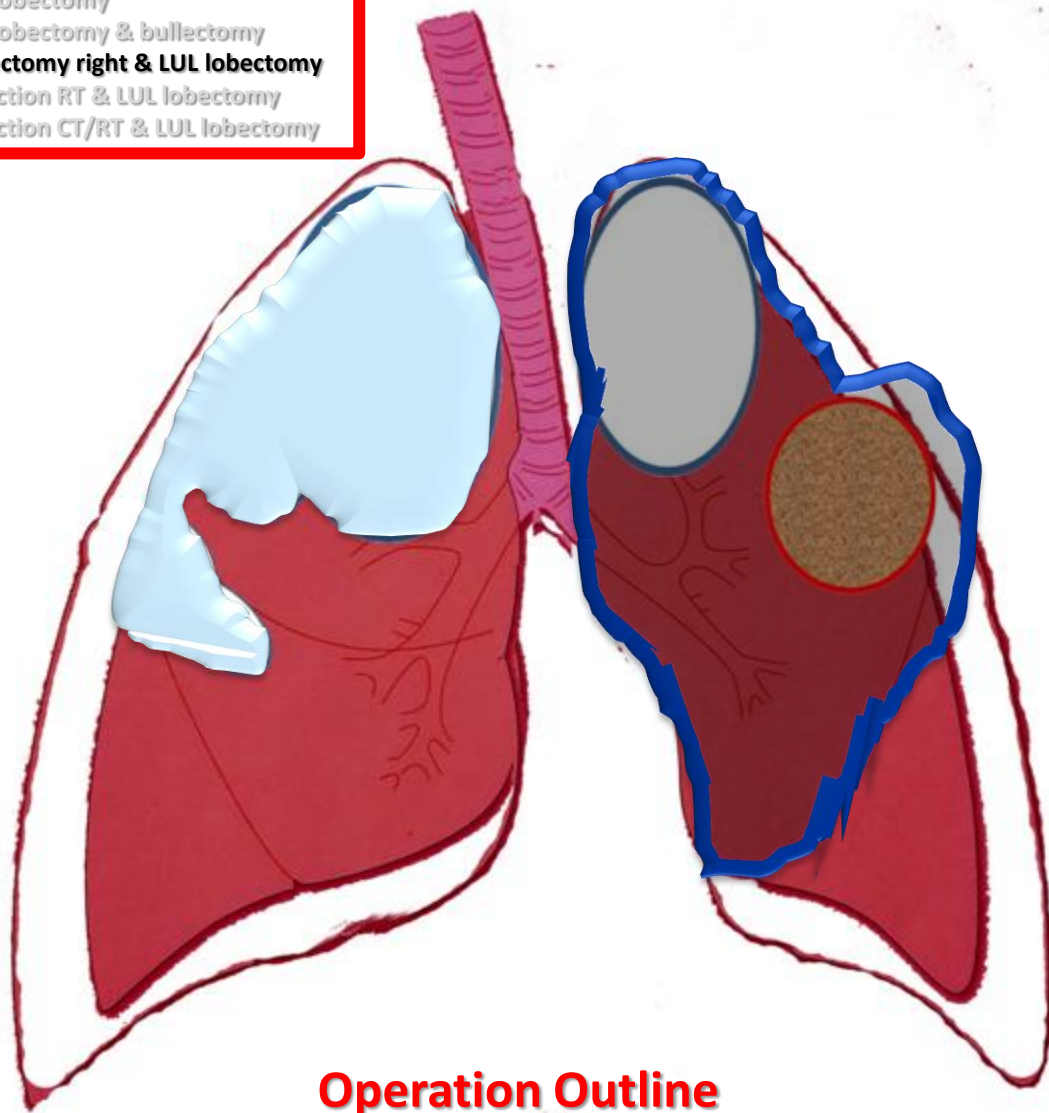
Treatment strategy

1. LUL lobectomy
2. LUL lobectomy & bullectomy
3. **Bullectomy right & LUL lobectomy**
4. Induction RT & LUL lobectomy
5. Induction CT/RT & LUL lobectomy



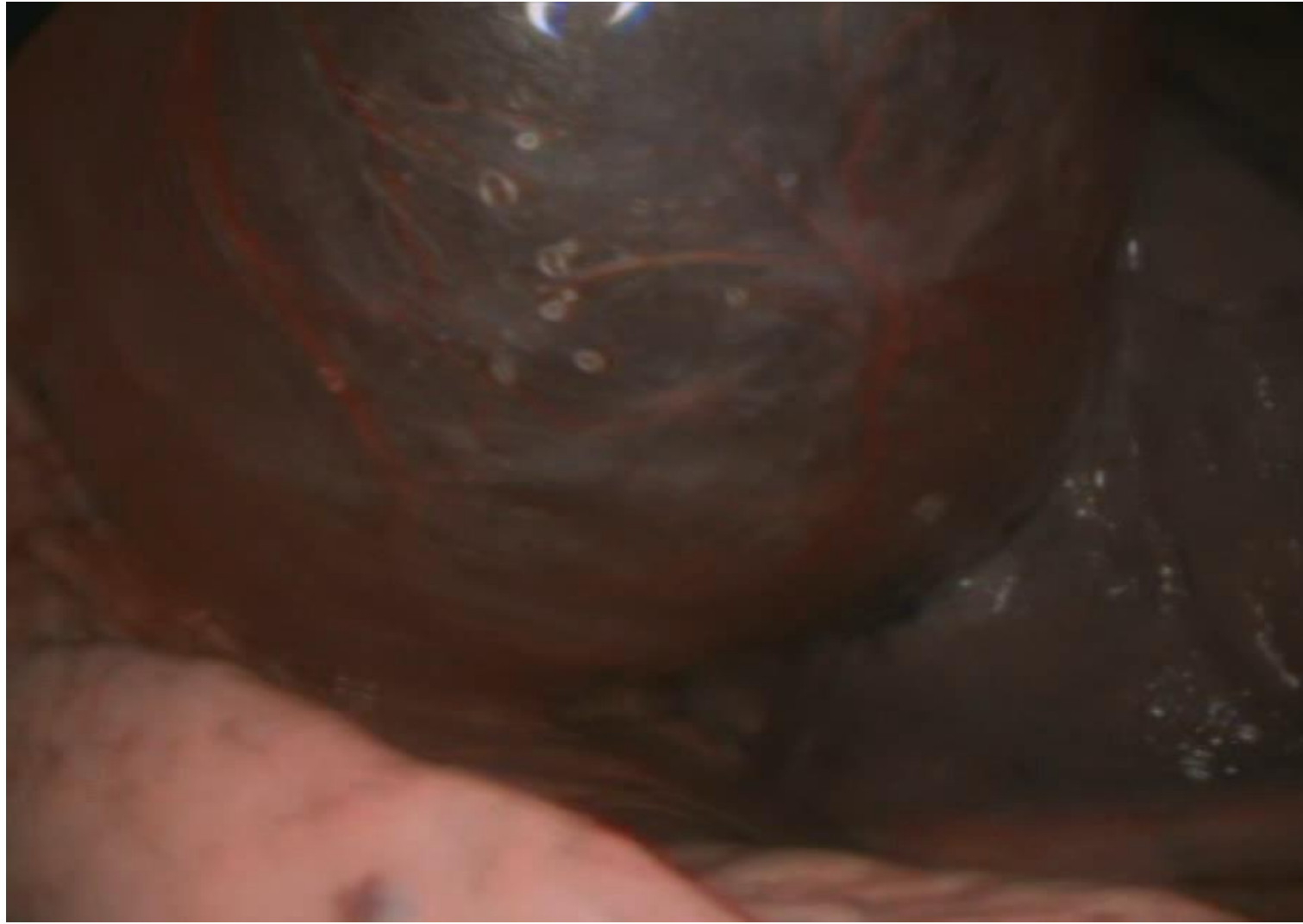
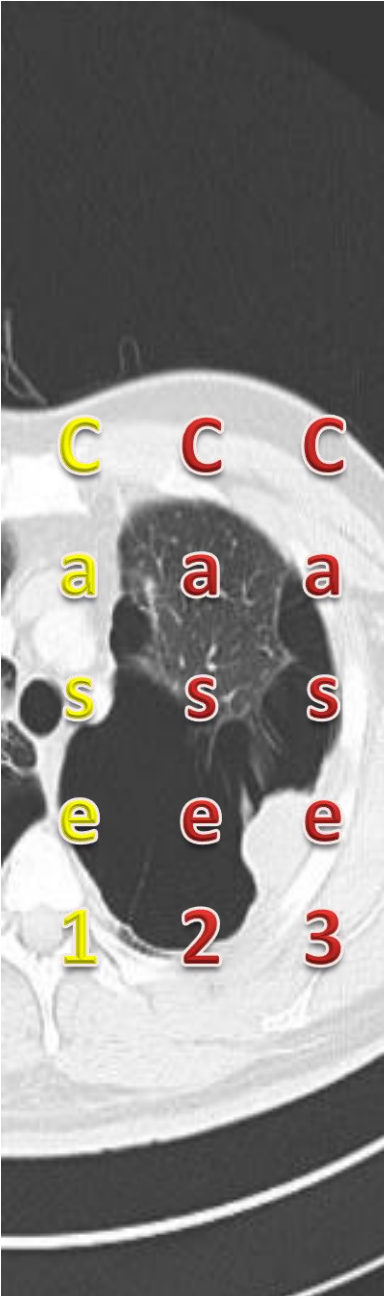
Case 1

1. LUL lobectomy
2. LUL lobectomy & bullectomy
3. **Bullectomy right & LUL lobectomy**
4. Induction RT & LUL lobectomy
5. Induction CT/RT & LUL lobectomy



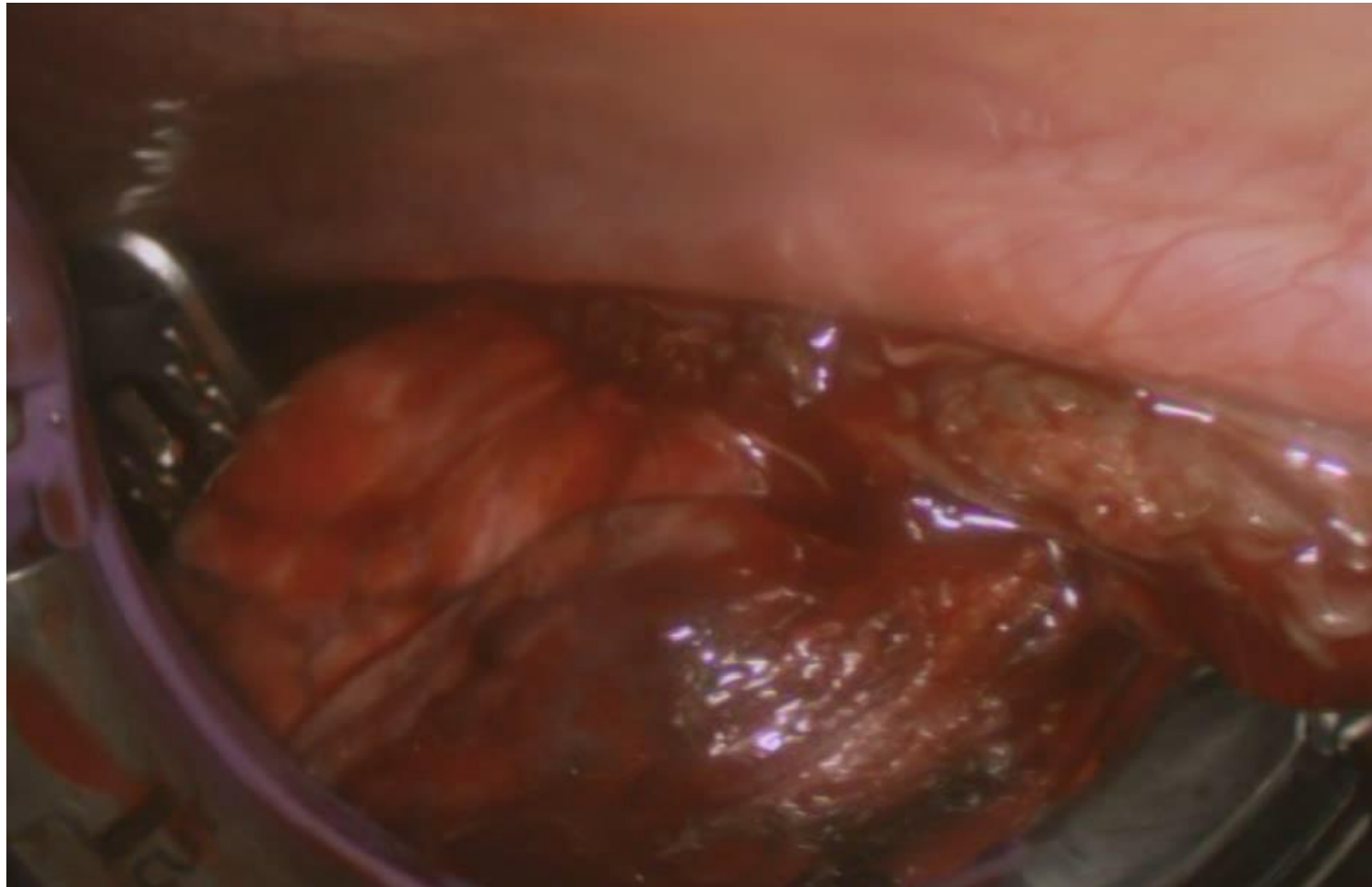
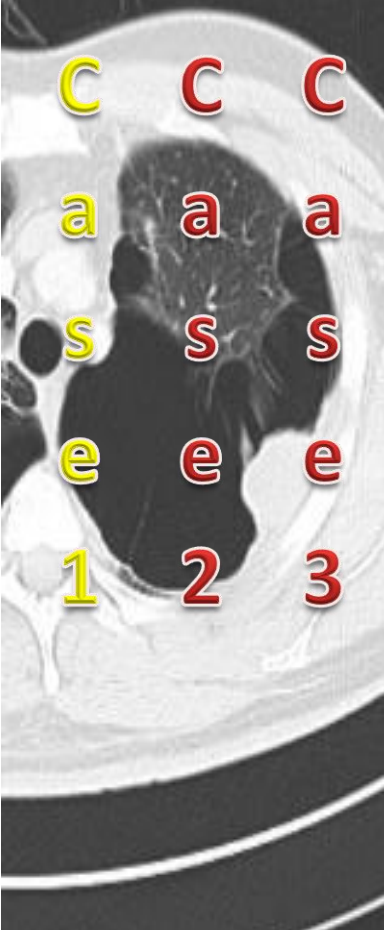Operation Outline

Case 1



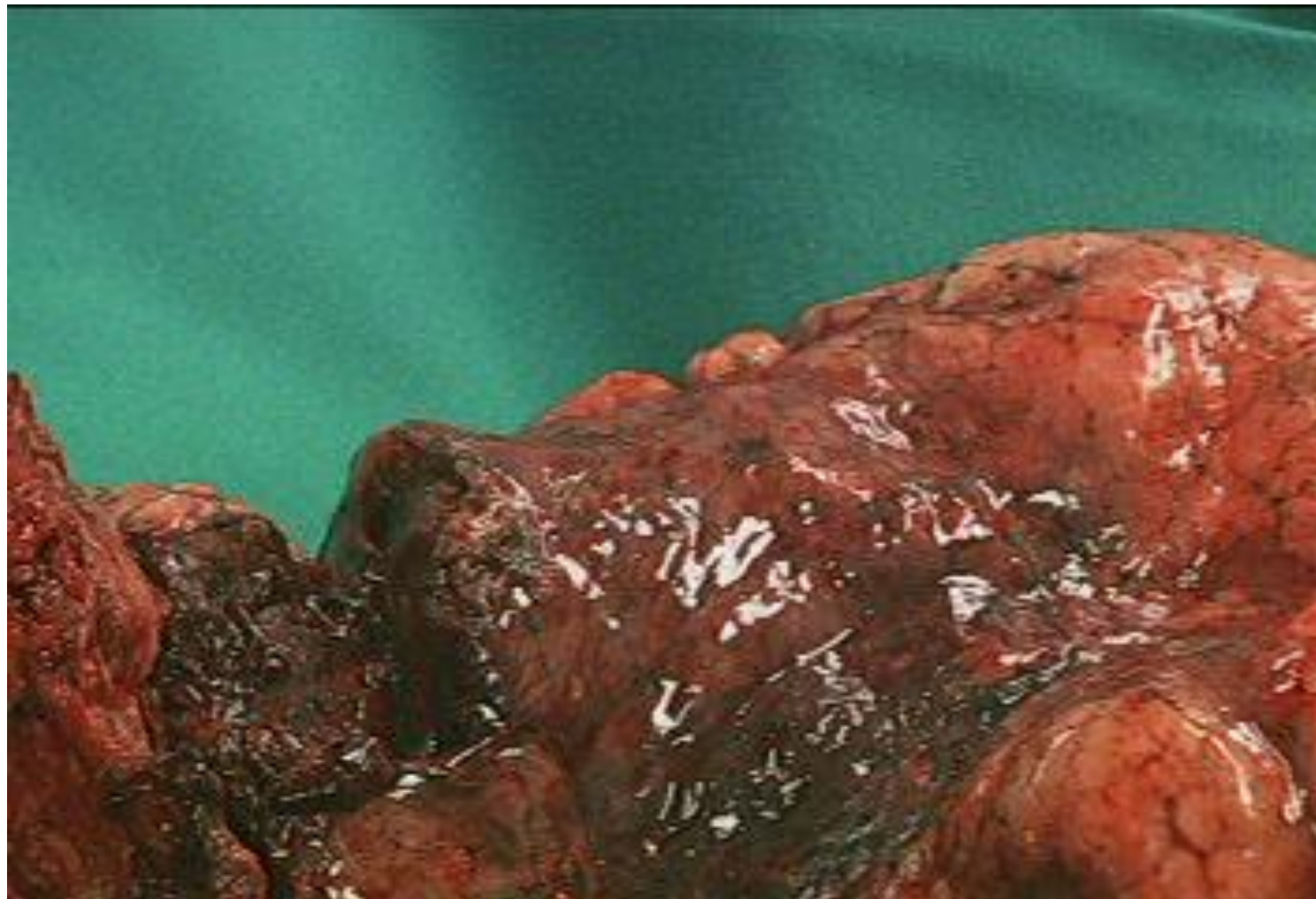
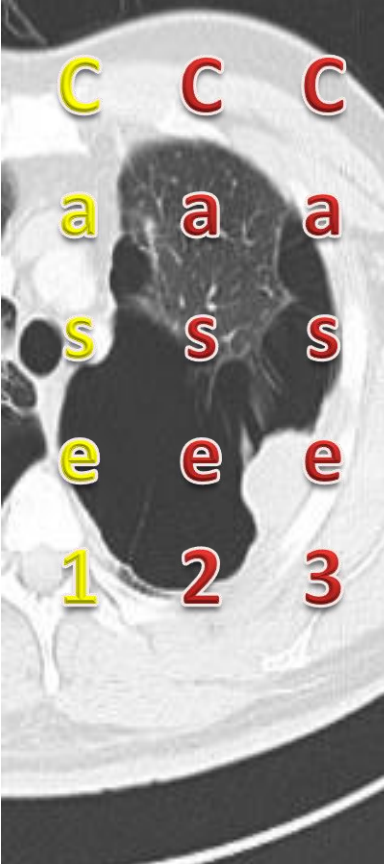Right Bullectomy

Case 1



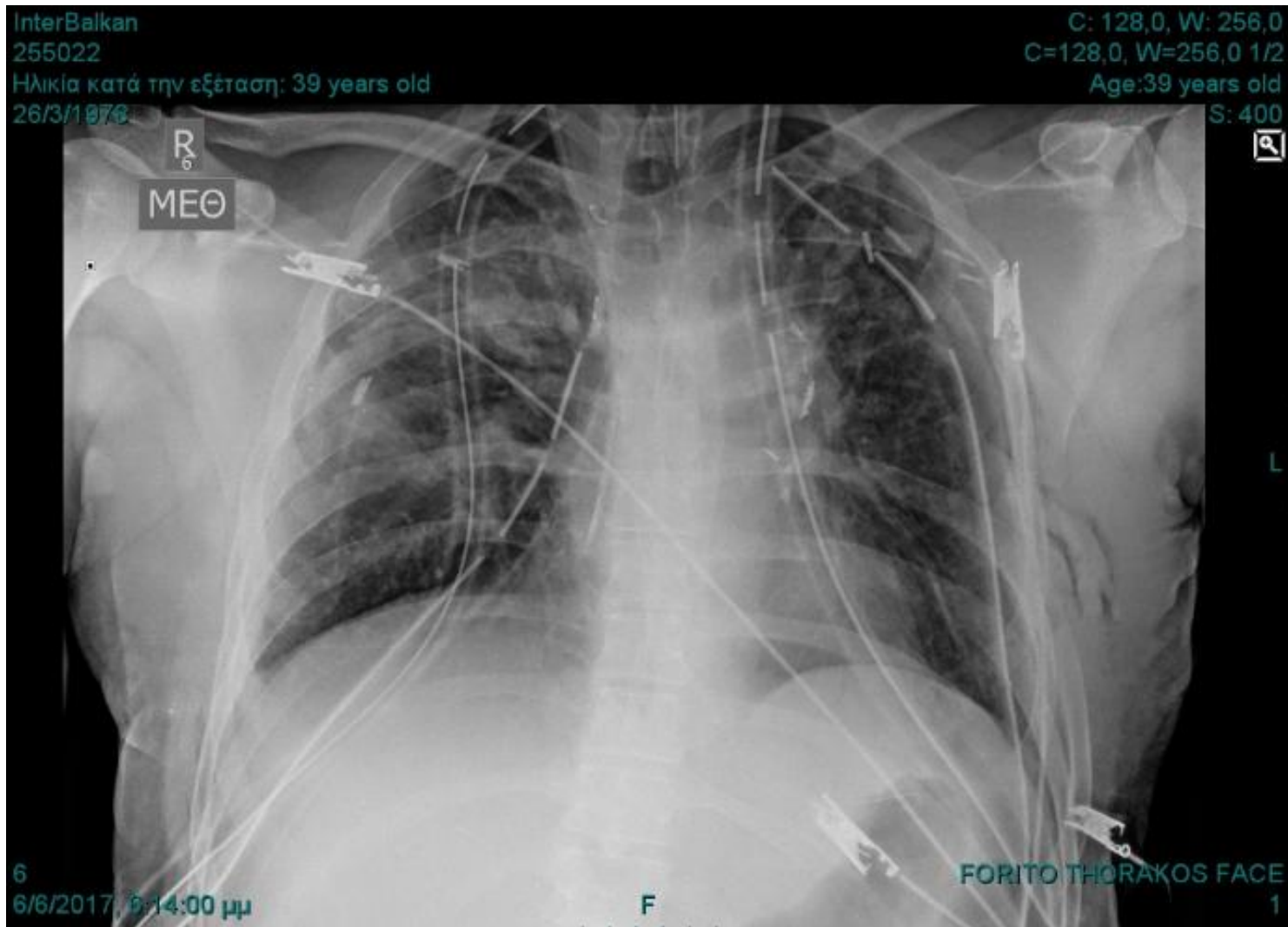
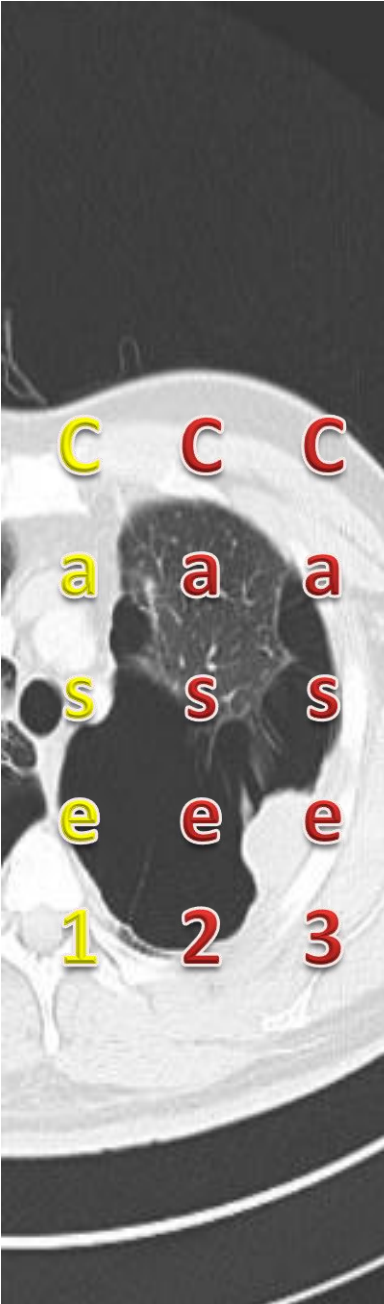
Right Bullectomy

Case 1



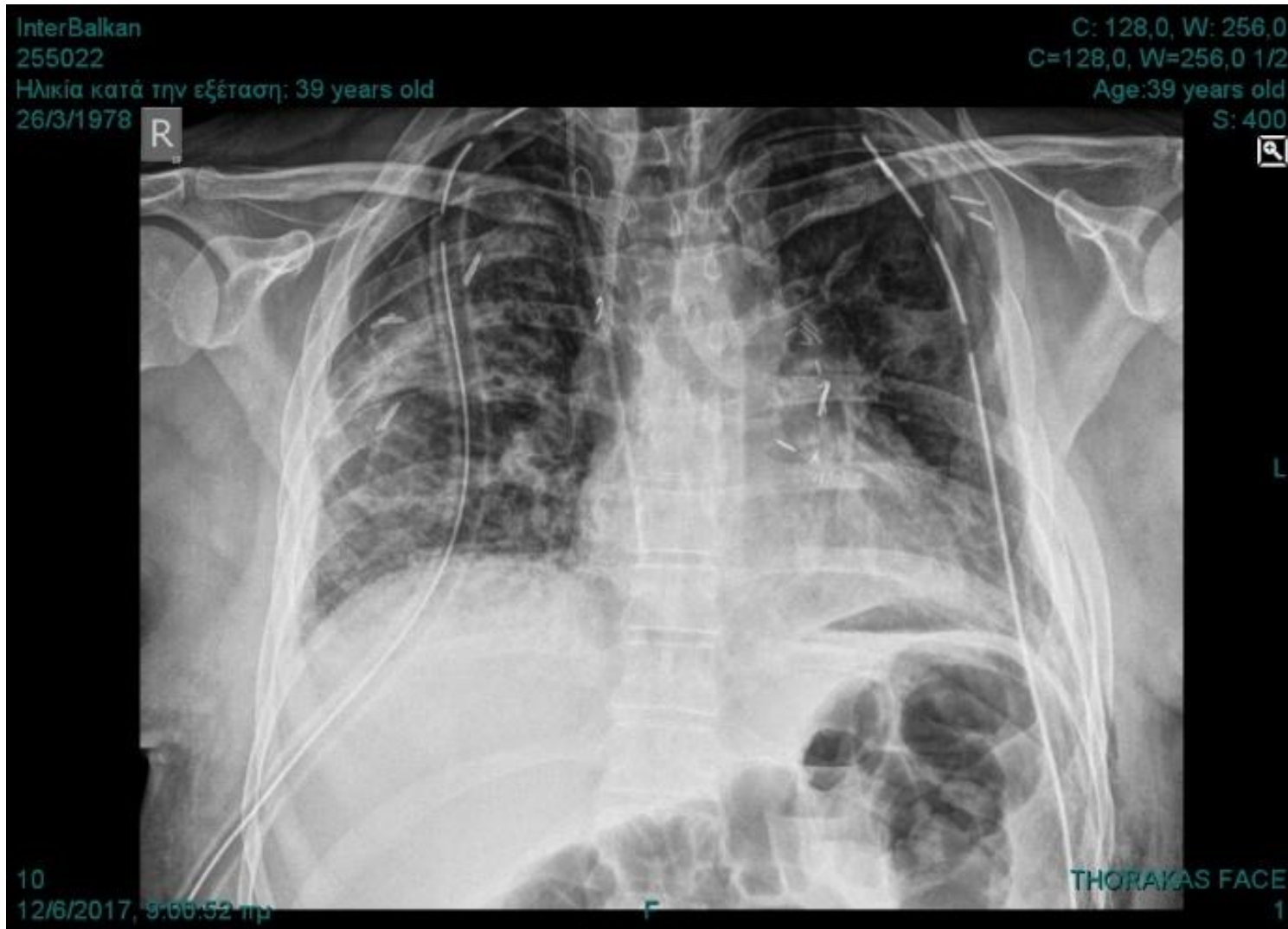Right Bullectomy

Case 1



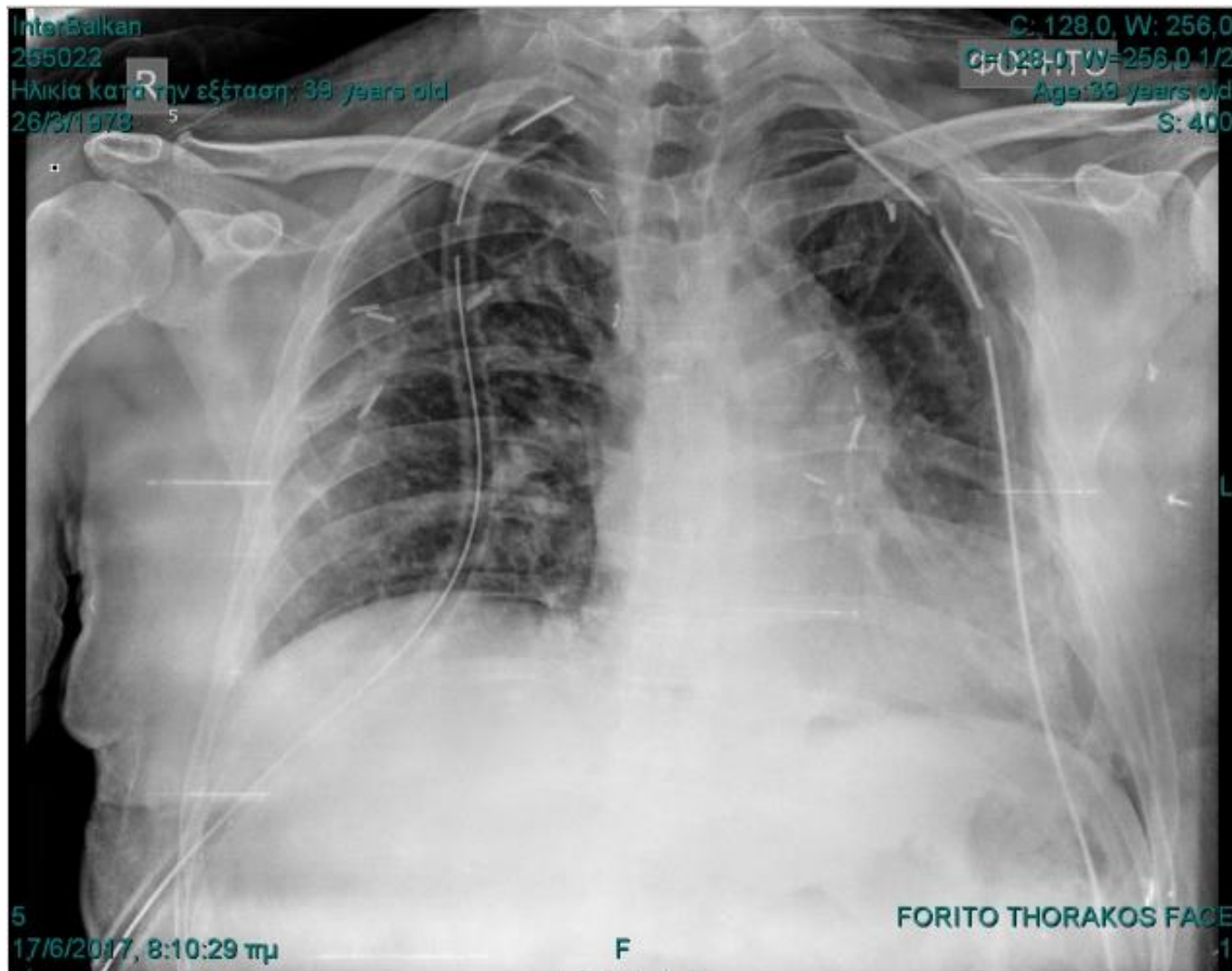
postOp Chest X-ray (F)

Case 1



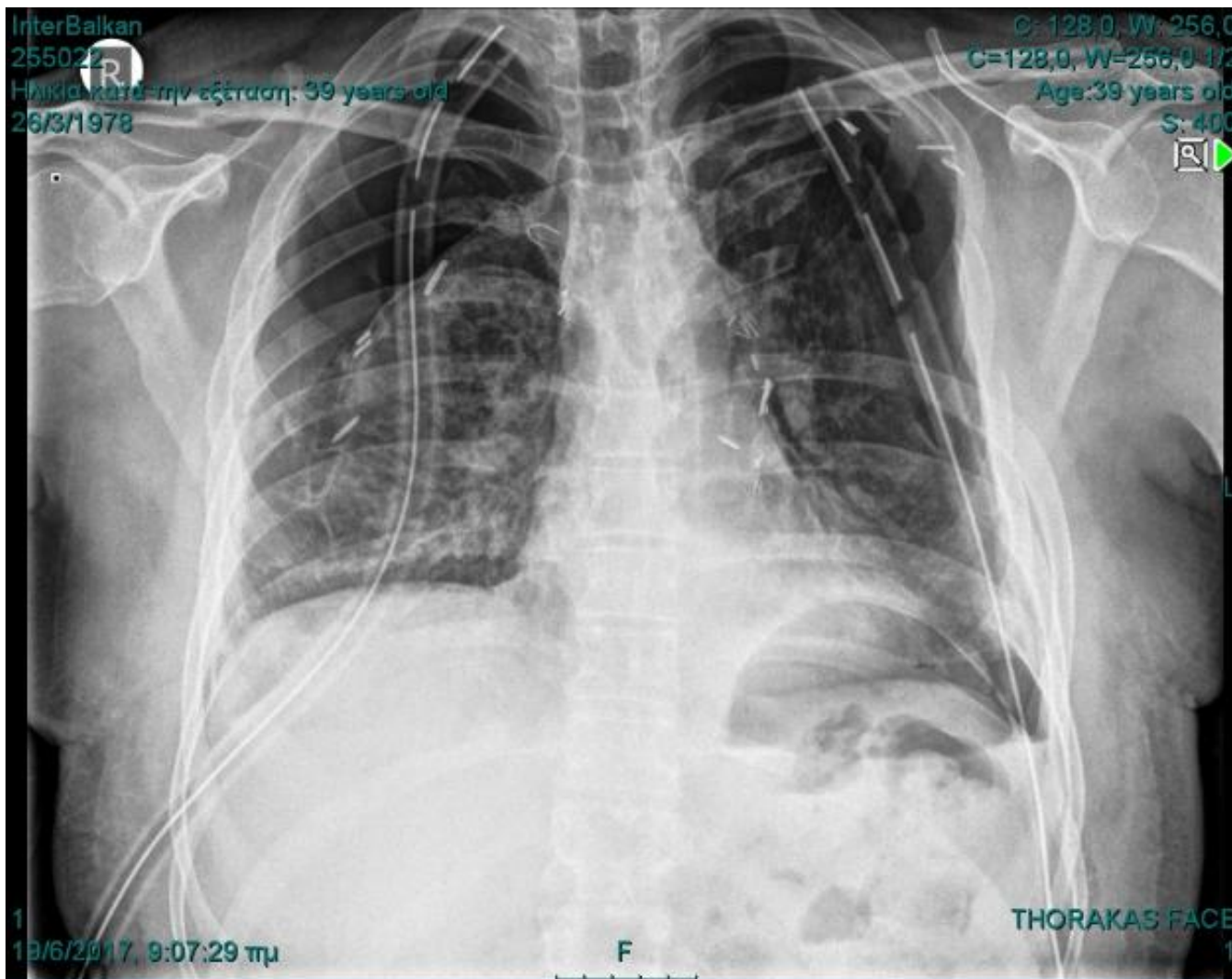
(6th postOp) Chest X-ray (F)

Case 1



(11th postOp) Chest X-ray (F)

Case 1

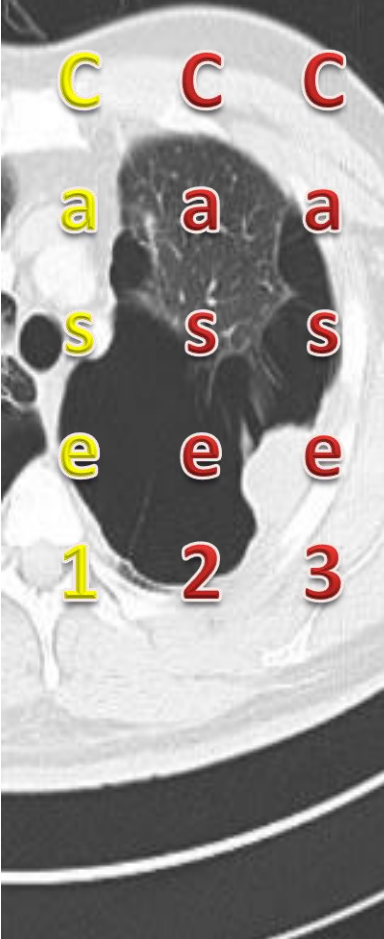

(13th postOp) Chest X-ray (F)

Case 1

Prolonged air leak bilateral

1. Reoperation
2. Pleurodesis unilateral/bilateral
3. VATS pleurodesis
4. Discharge with Heimlich valve



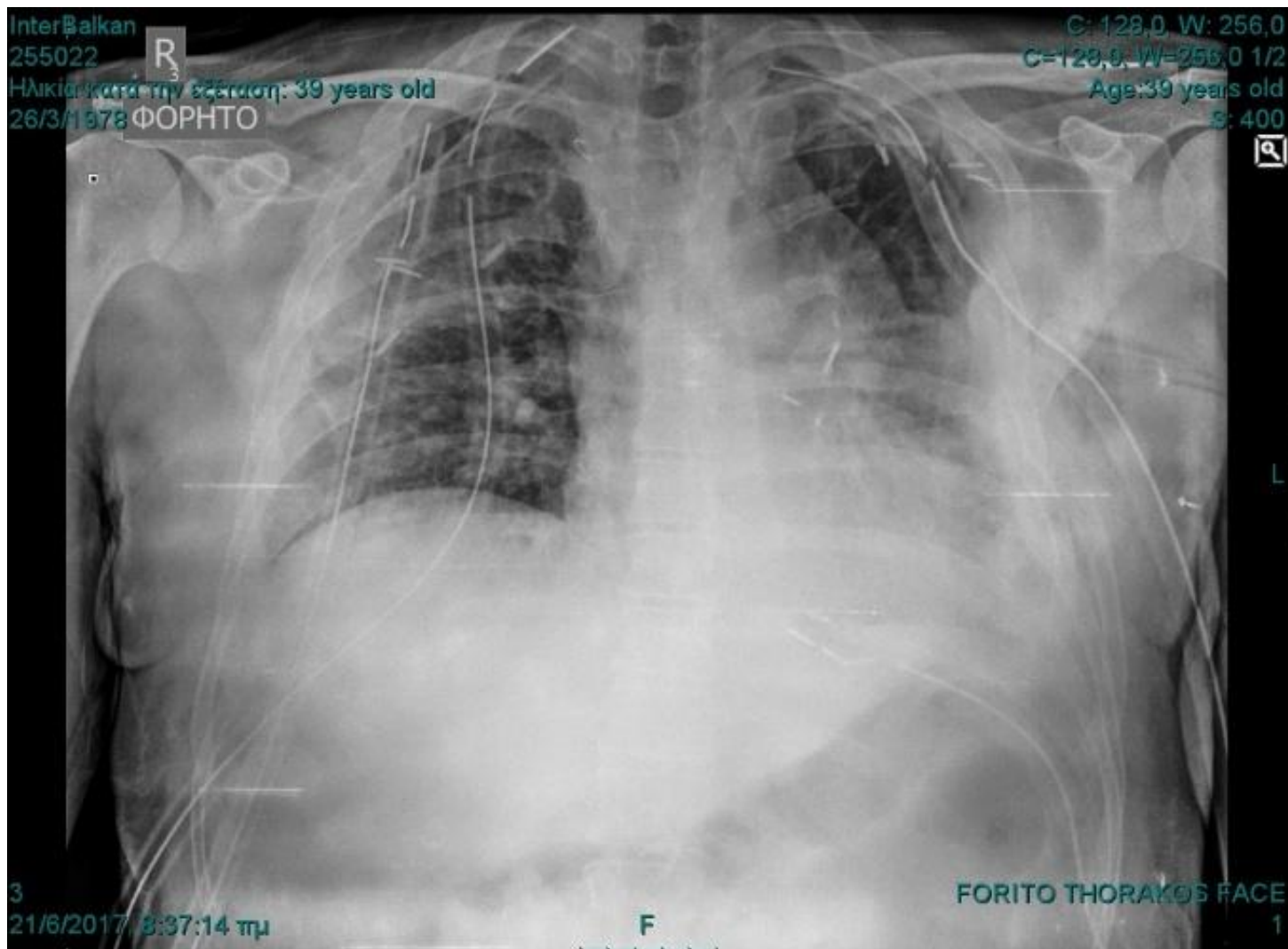Case 1

Prolonged air leak bilateral

1. Reoperation
2. Pleurodesis unilateral/bilateral
3. **VATS pleurodesis**
4. Discharge with Heimlich valve

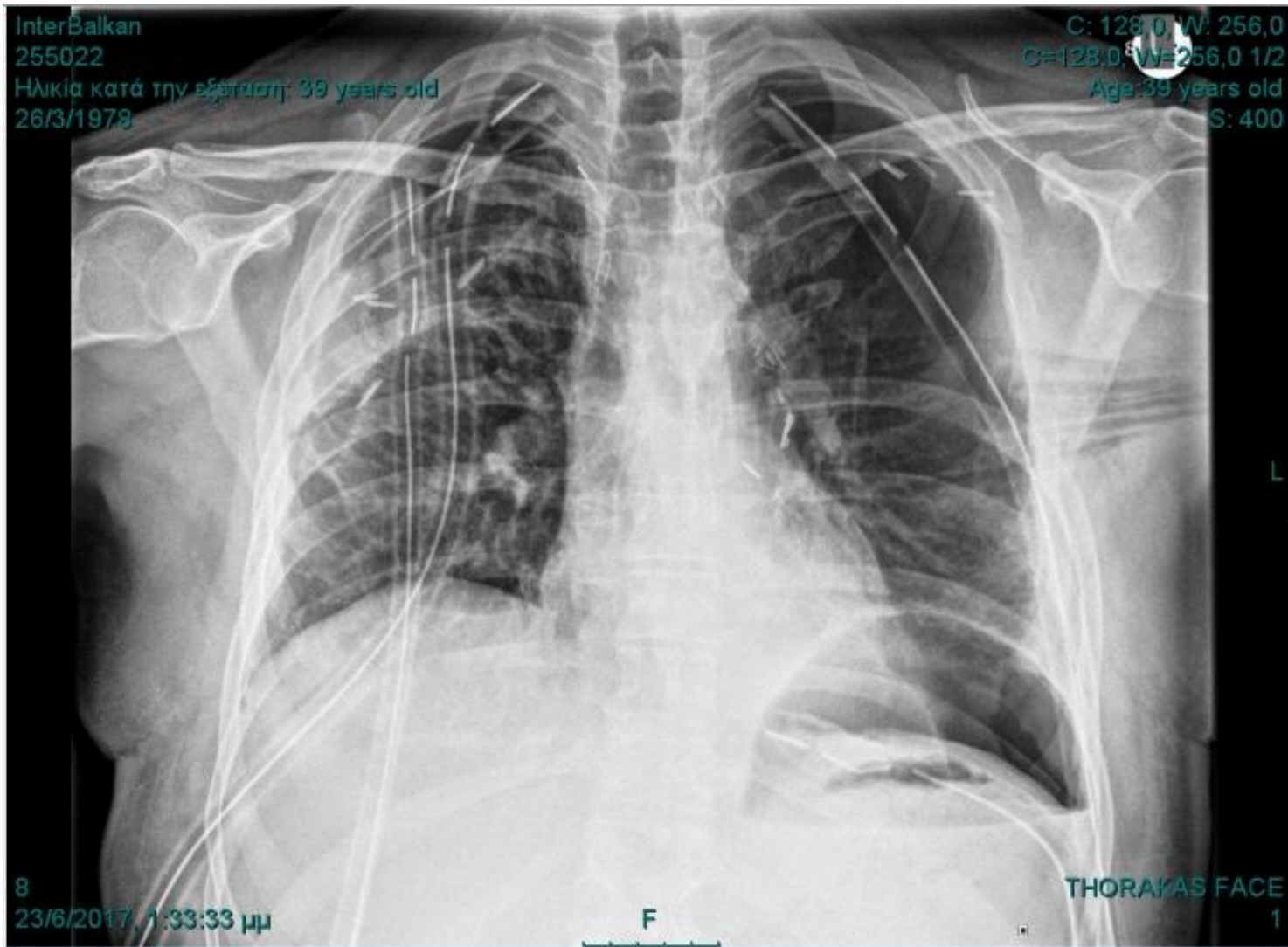


Case 1

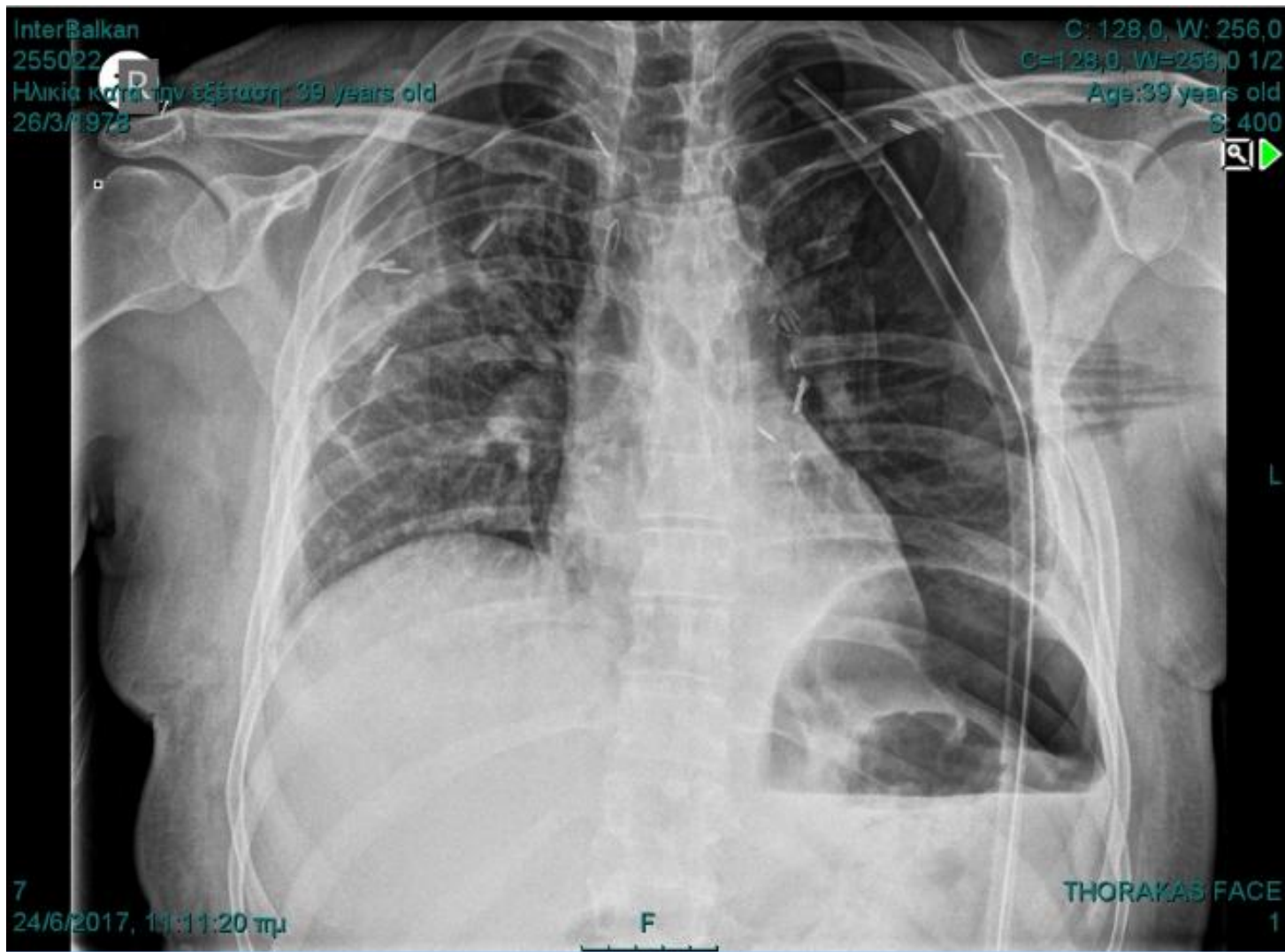


(15th postOp) Chest X-ray (F)

Case 1

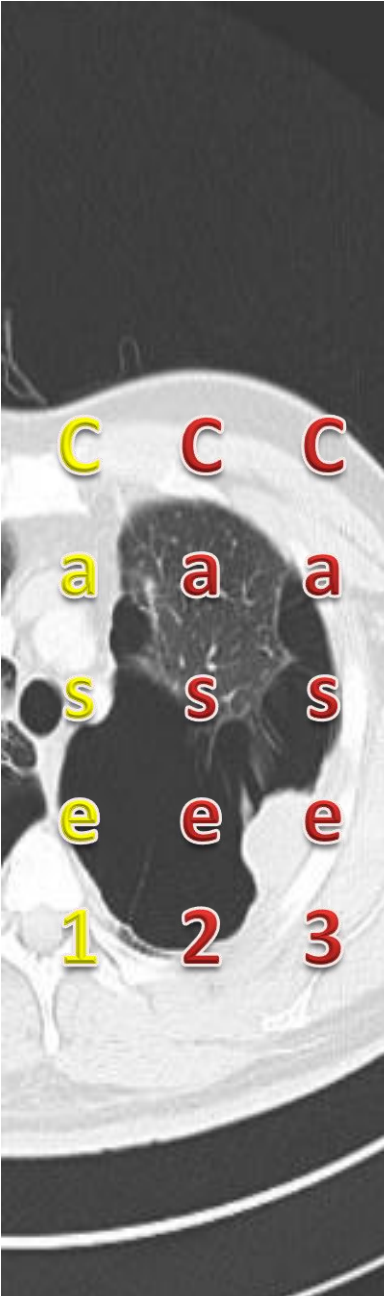


Case 1



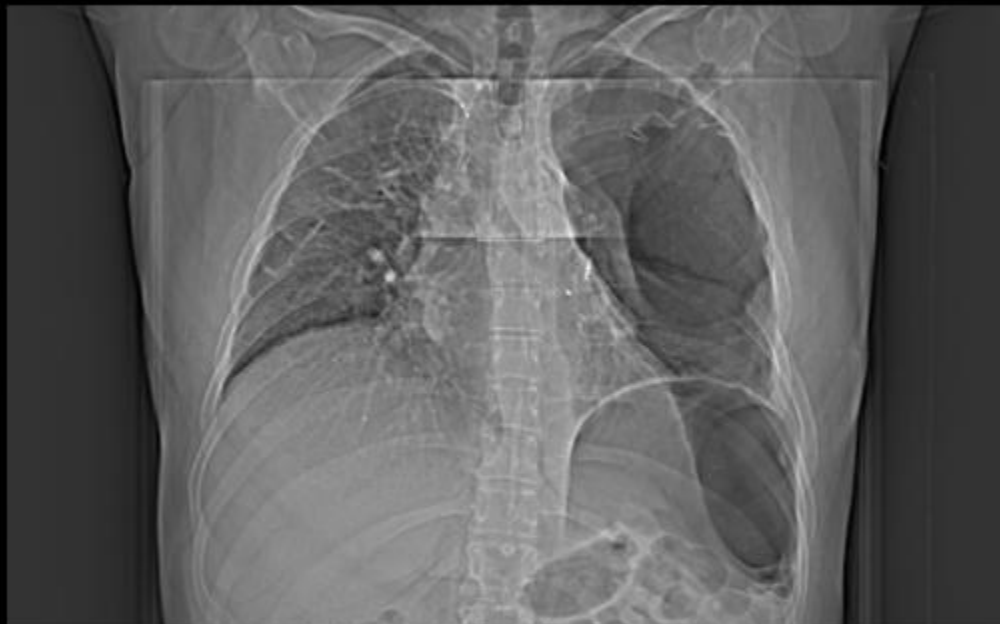(18th postOp) Chest X-ray (F)

Case 1

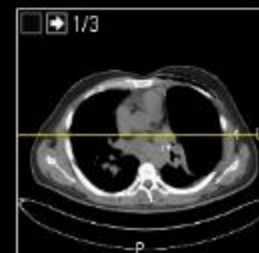


InterBalkan
6002176
Ηλικία κατά την εξέταση: 39 years old
26/3/1978
Gantry: 0°
Time: 3258 ms
Couch: -717,5
Pos: HFS

C: 50,0, W: 350,0
WINDOW1 1/8
Age:39 years old



F: T20f
35 mA
120 kV
Image no: 1
Εικόνα 1 από 4
13/7/2017, 10:24:44 πμ



(30th postOp) Chest X-ray (F)

Case 1

Histology

Squamous NSCLC

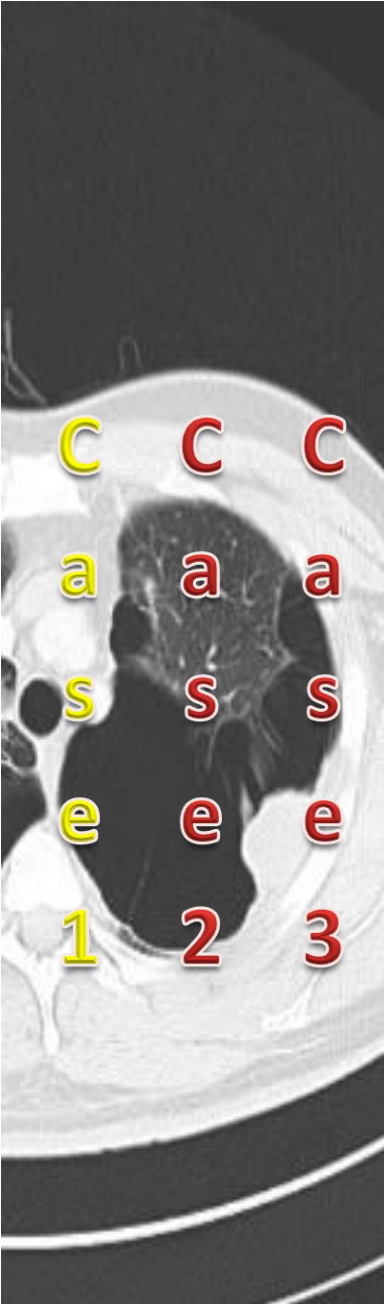
Low grade

LNR (N1): 0/8

No chest wall invasion

pT3N0M0

IIb stage

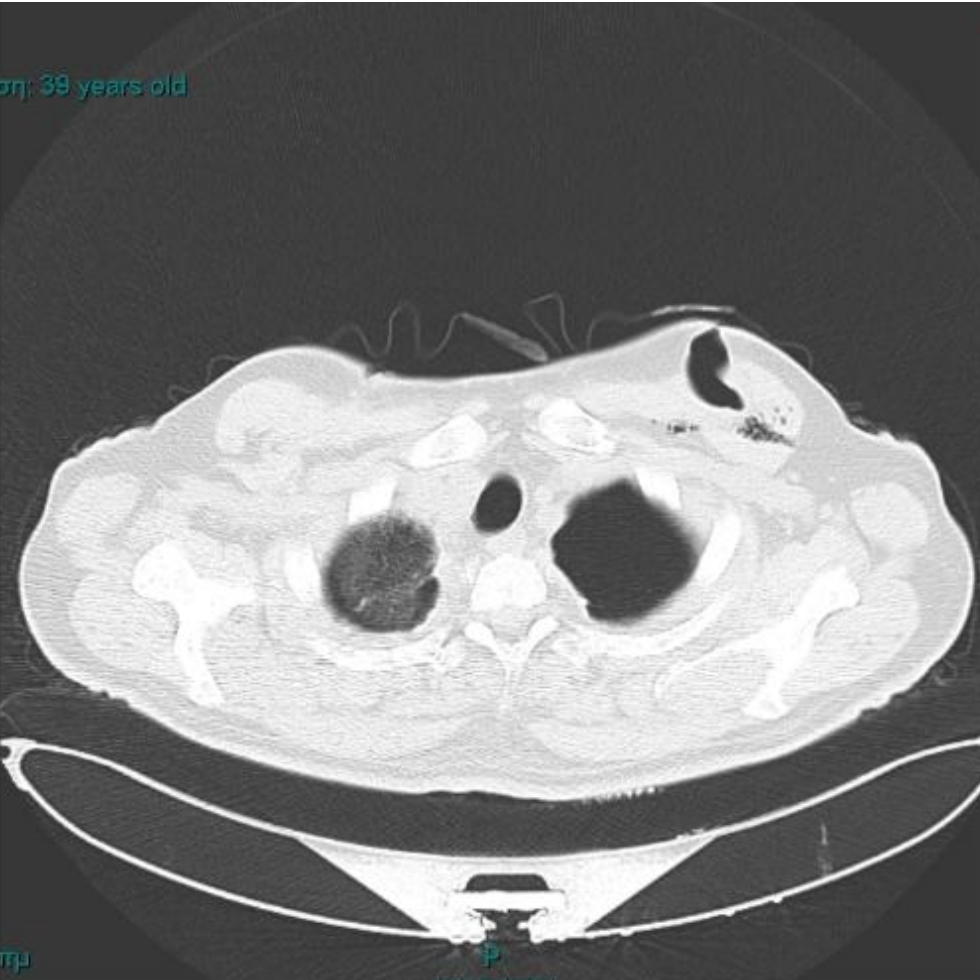

Case 1



InterBalkan
6002176
Ηλικία κατά την εξέταση: 39 years old
26/3/1978
Gantry: 0°
Time: 500 ms
Τομή: 6 mm
Couch: -757,5
Pos: HFS

F: B80f
511 mA
100 kV
Image no: 8
Εικόνα 8 από 100
13/7/2017, 10:25:22 πμ


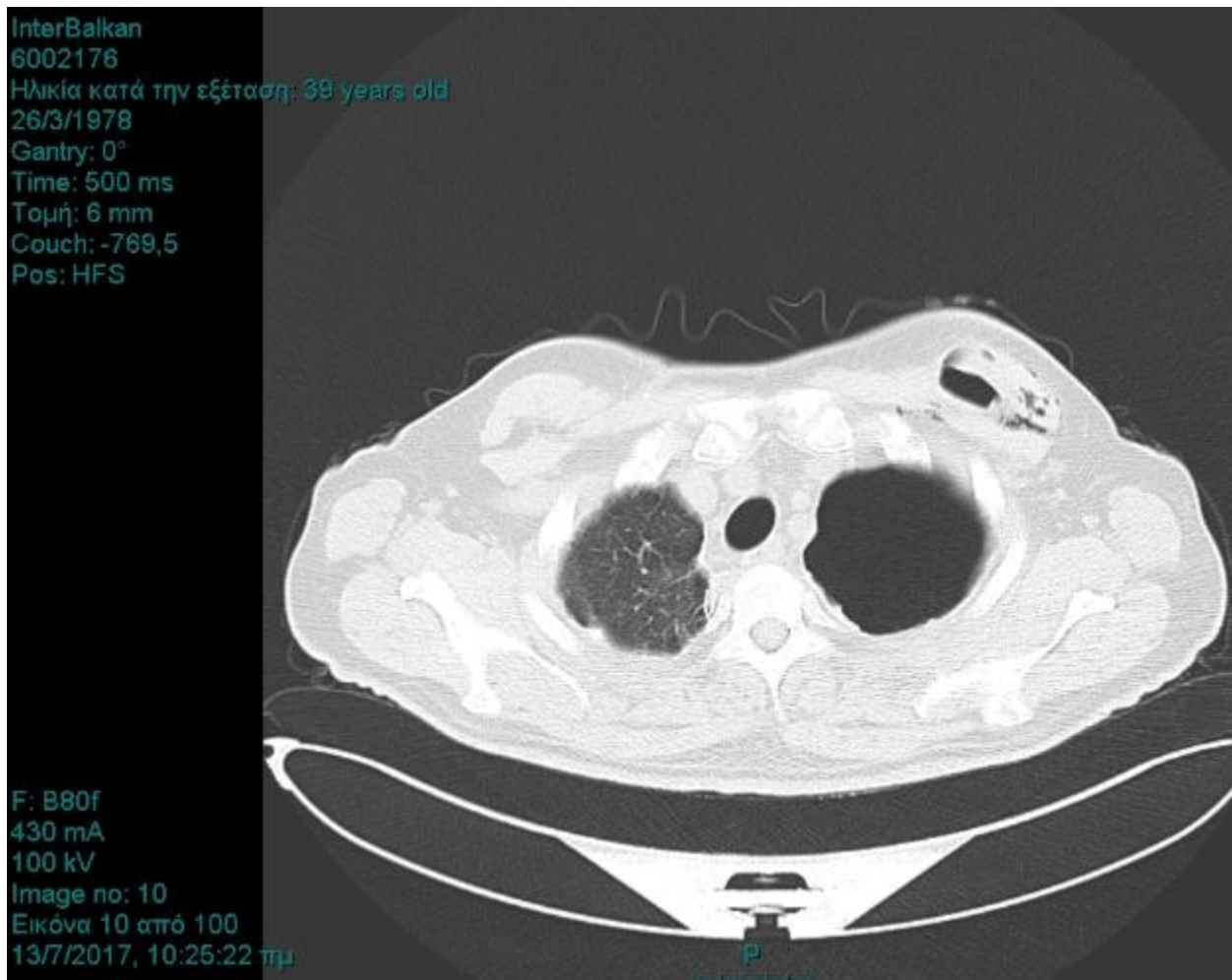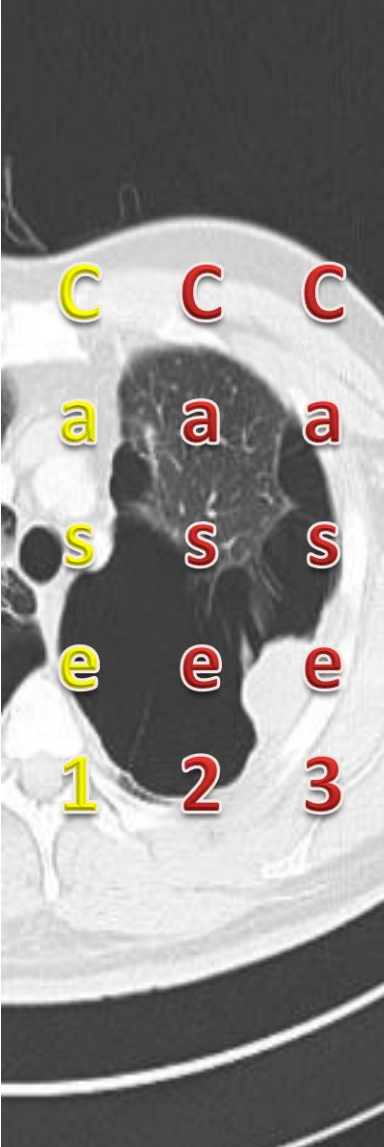


C: -600,0, W: 1500,0
WINDOW1 1/8
Age: 39 years old

A small inset image in the bottom right corner shows a different view of the chest CT scan, possibly a sagittal or coronal view, with a yellow box highlighting a specific area.

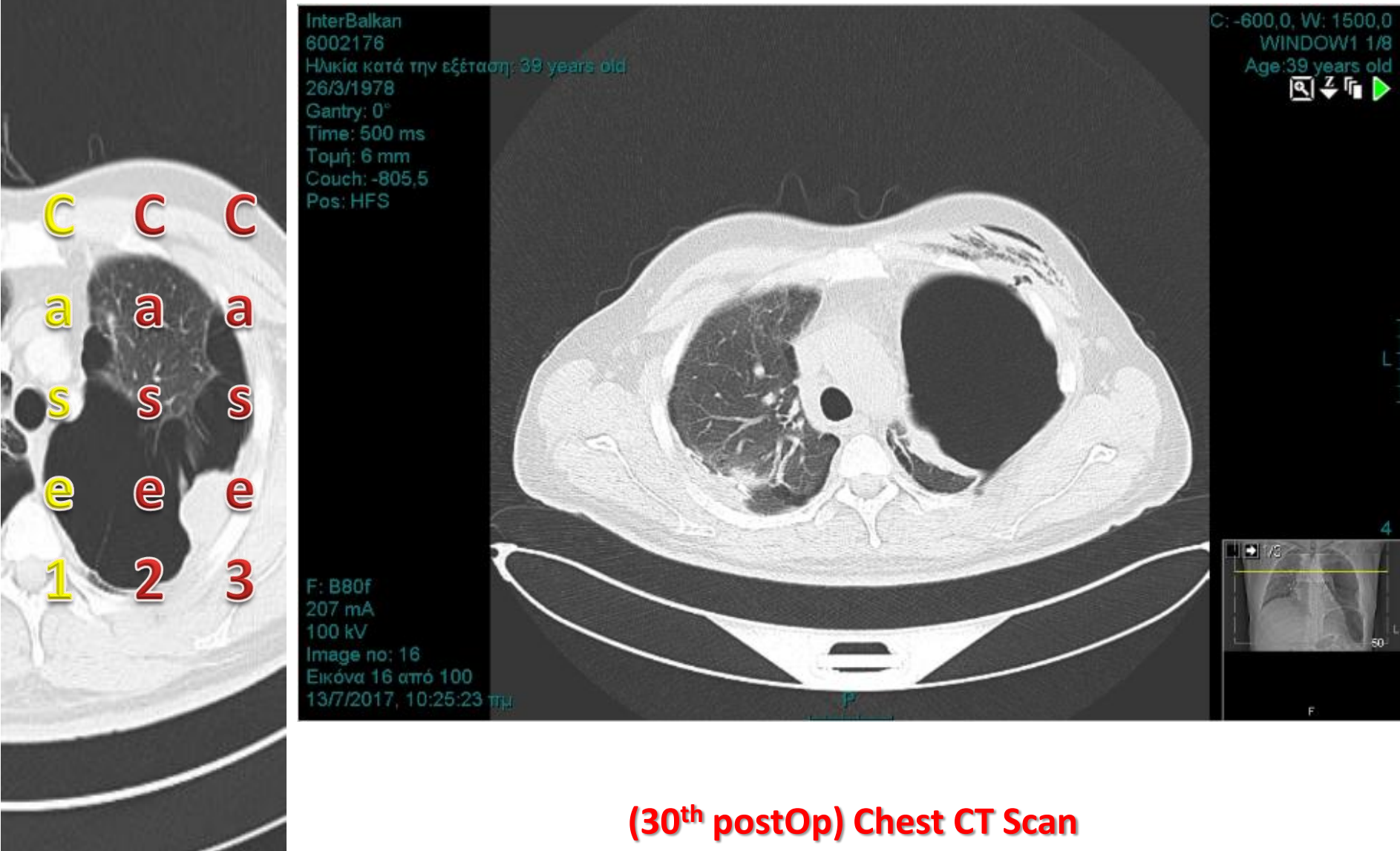
(30th postOp) Chest CT Scan

Case 1



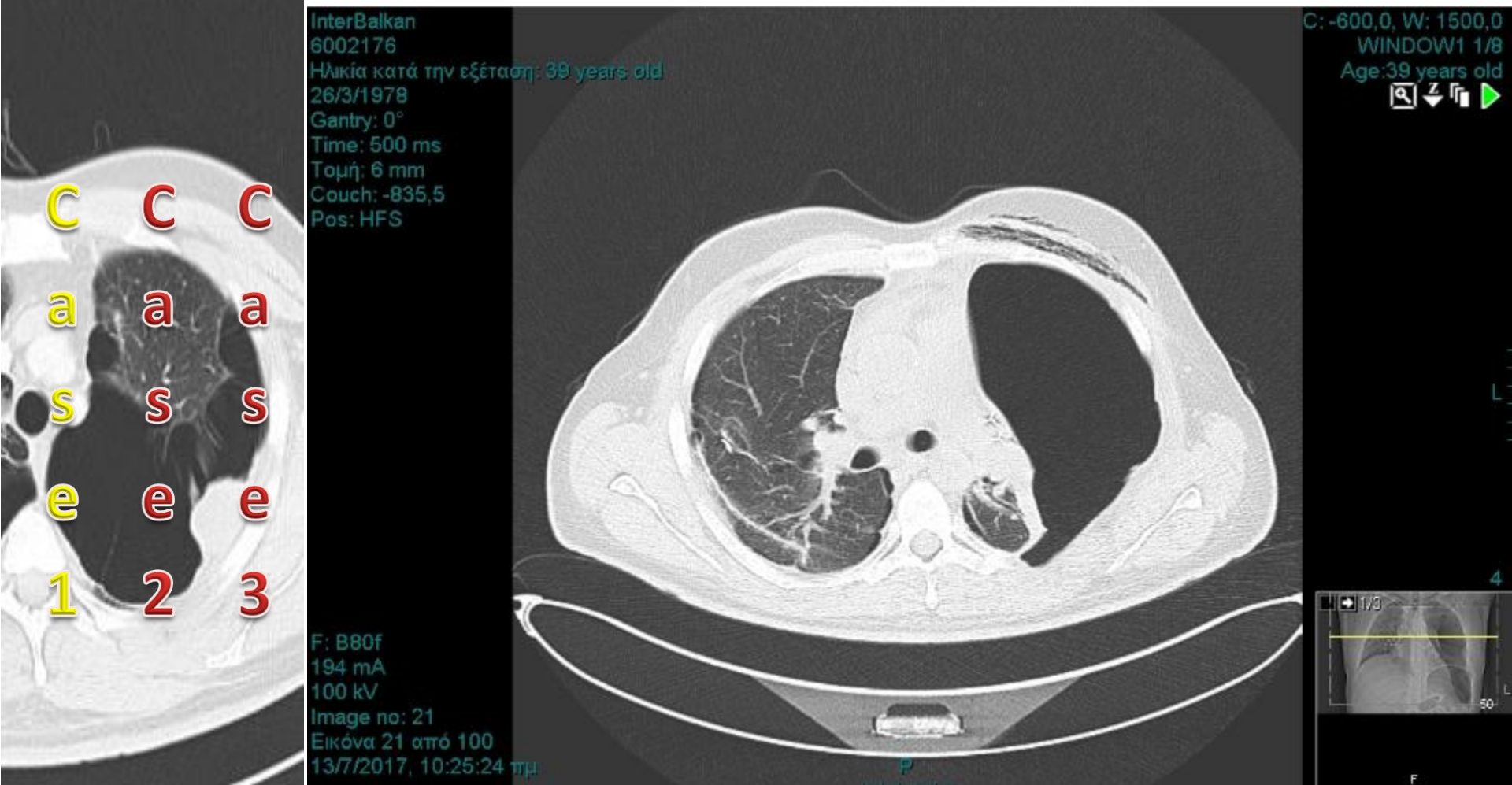(30th postOp) Chest CT Scan

Case 1



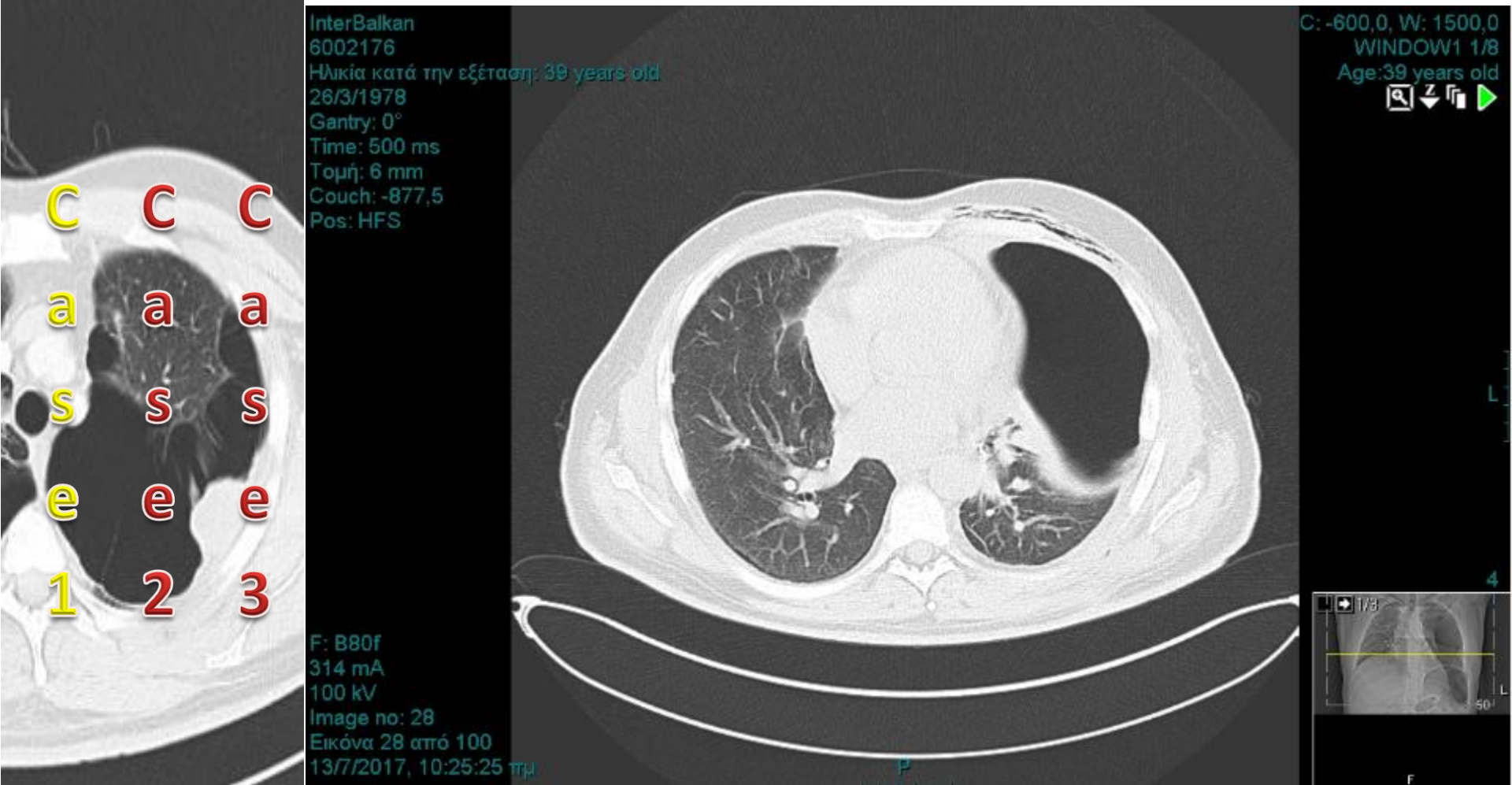(30th postOp) Chest CT Scan

Case 1



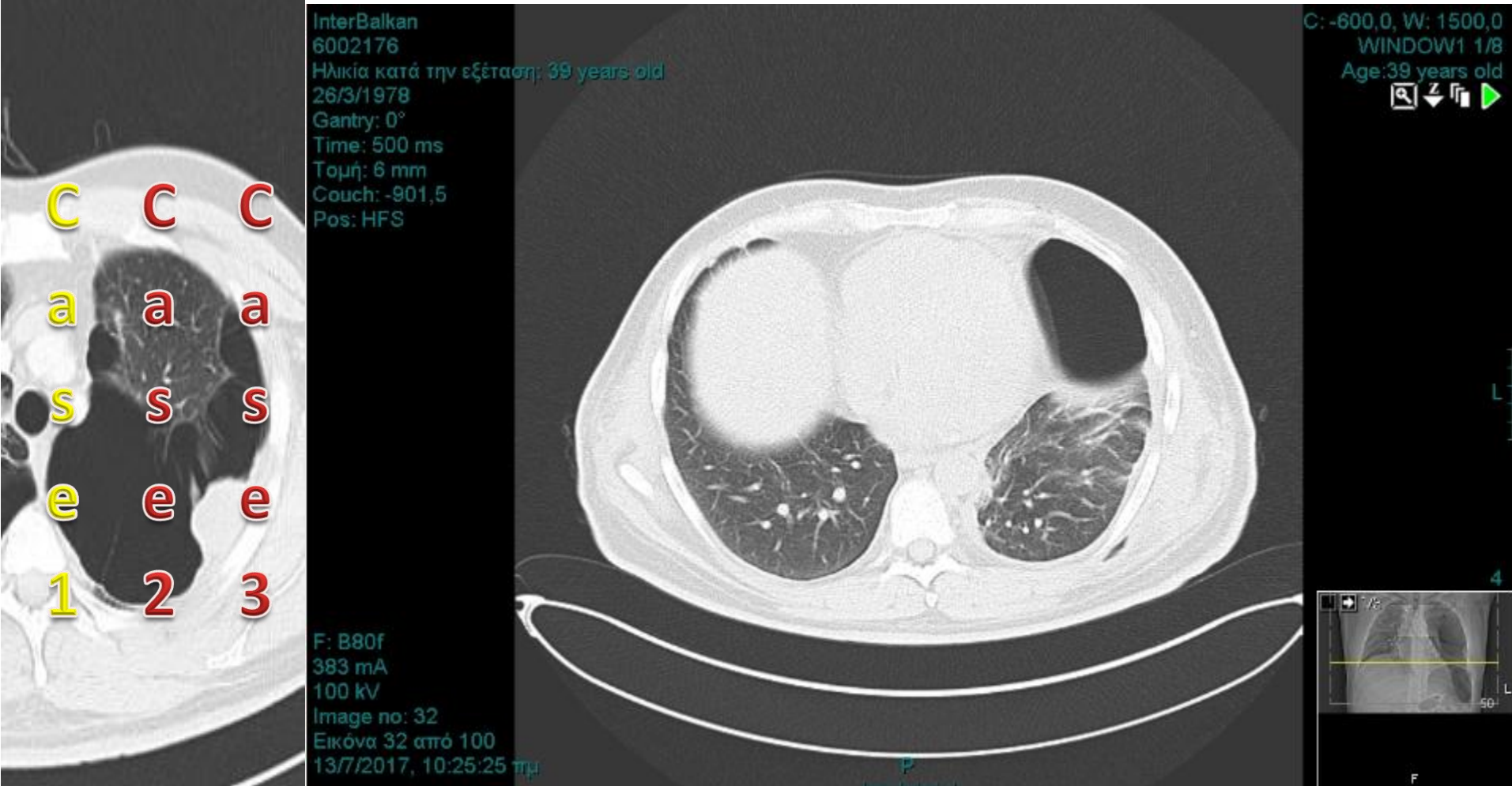(30th postOp) Chest CT Scan

Case 1



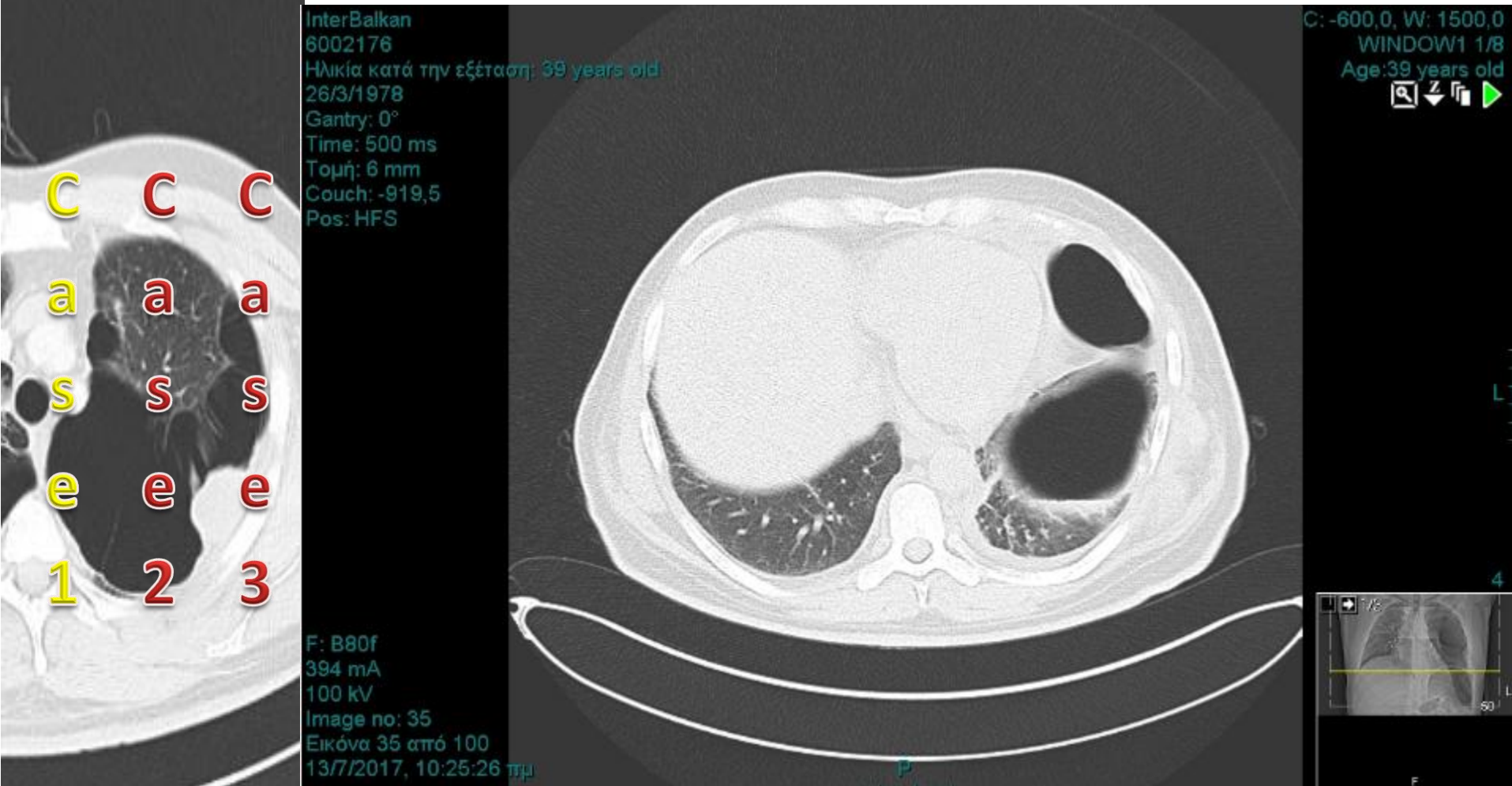
(30th postOp) Chest CT Scan

Case 1



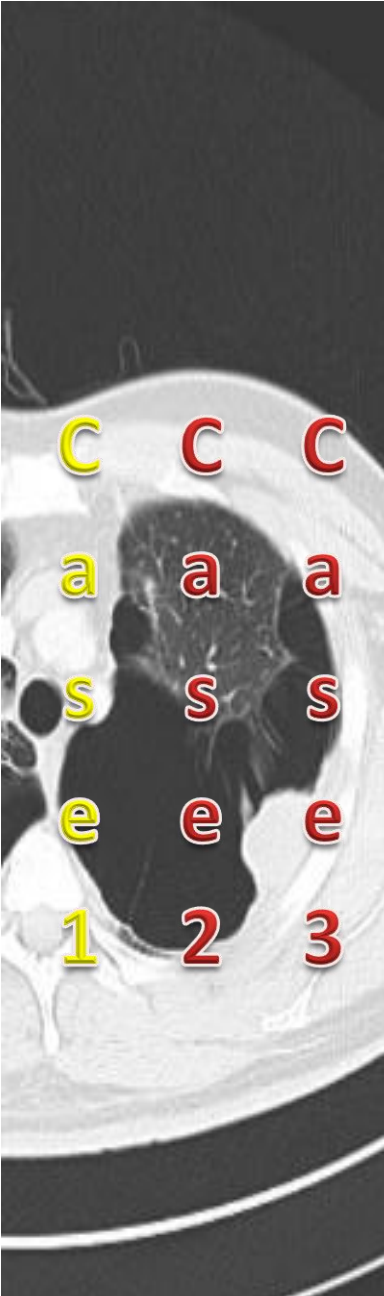
(30th postOp) Chest CT Scan

Case 1



(30th postOp) Chest CT Scan

Case 1



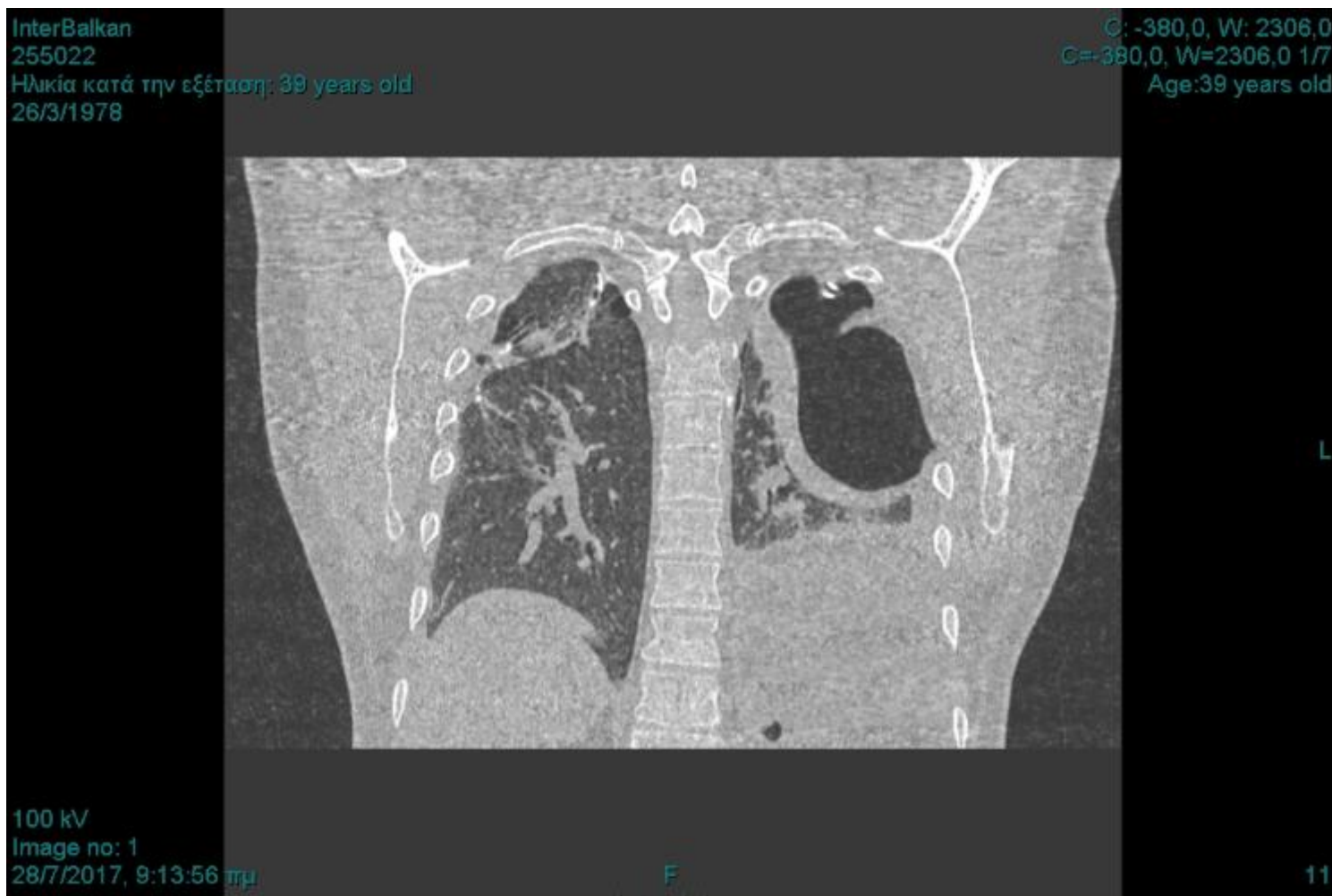
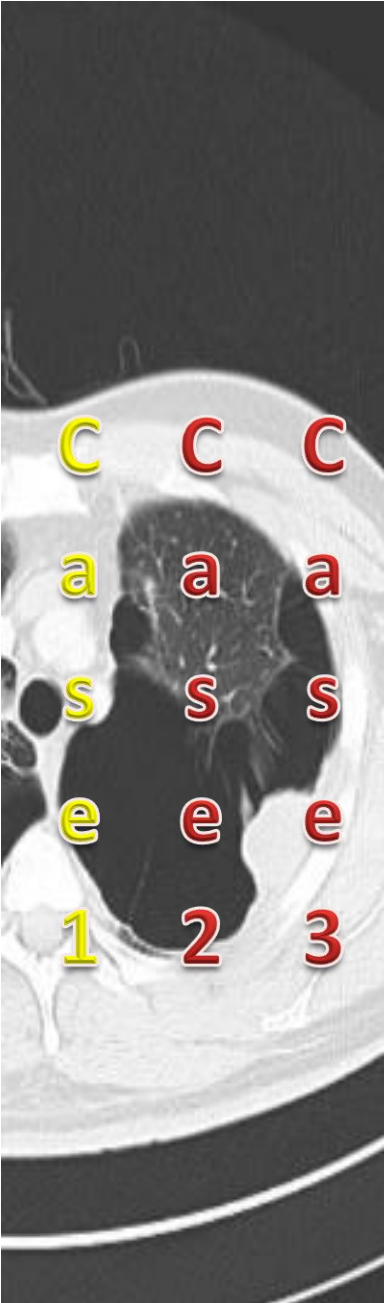
Adjuvant Chemo

(1st cycle)

Carboplatin

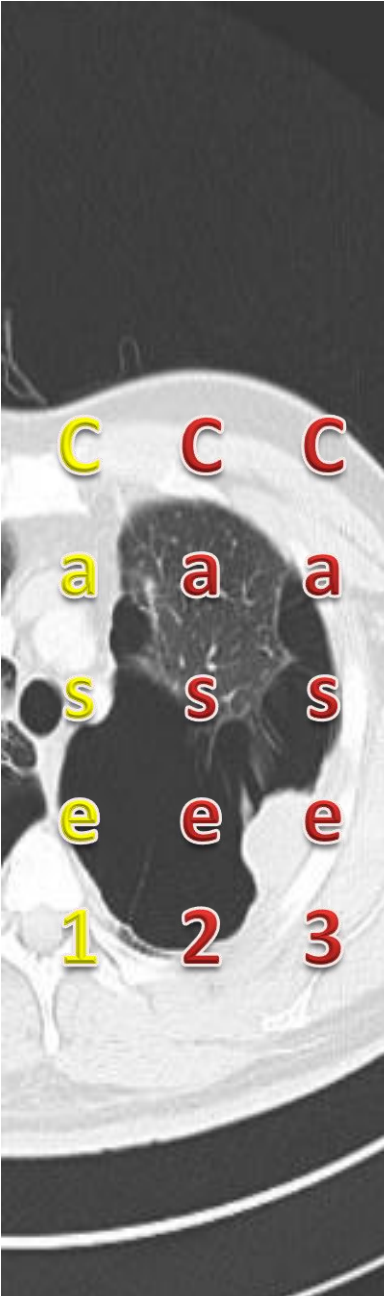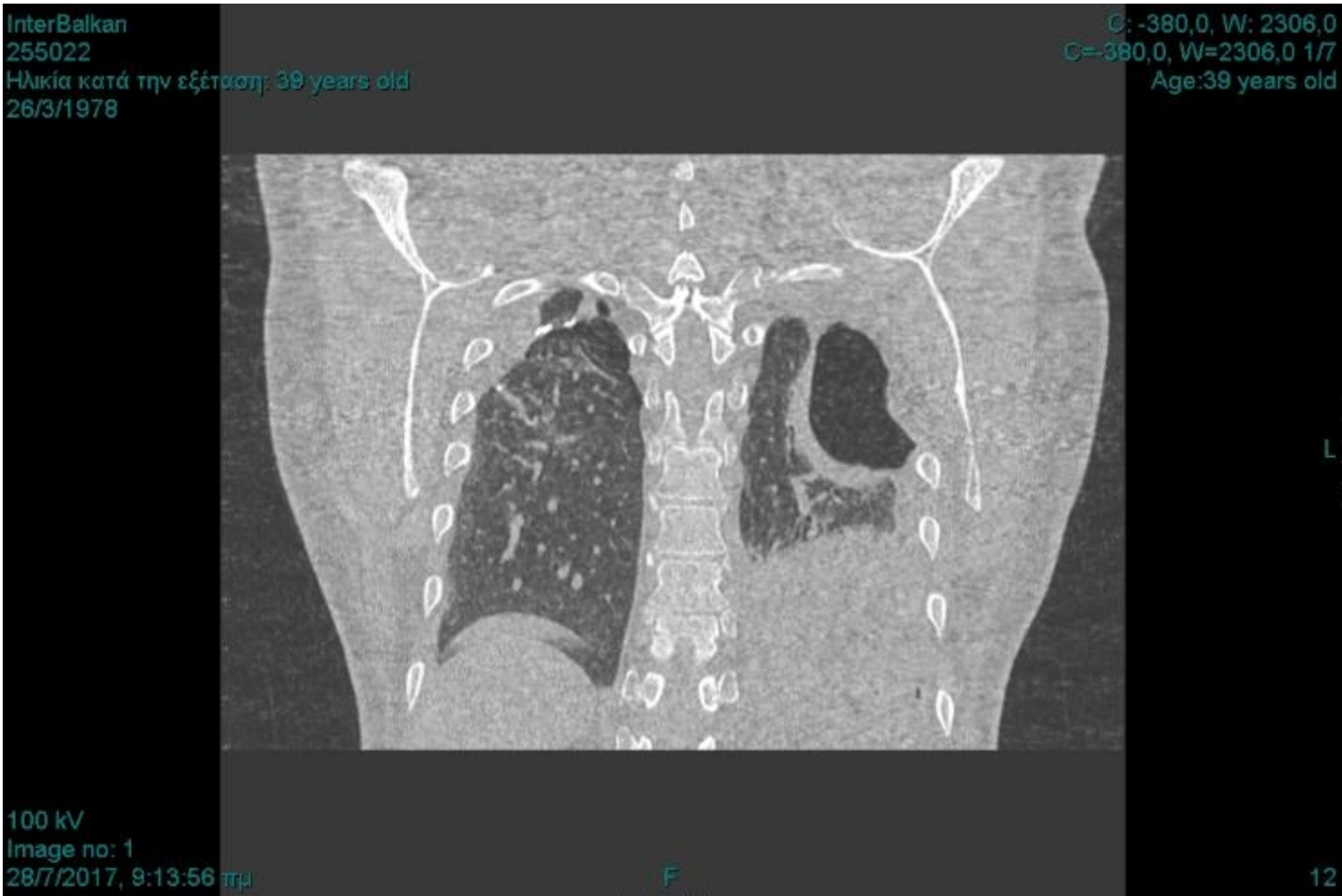
Pemetrexed

Case 1



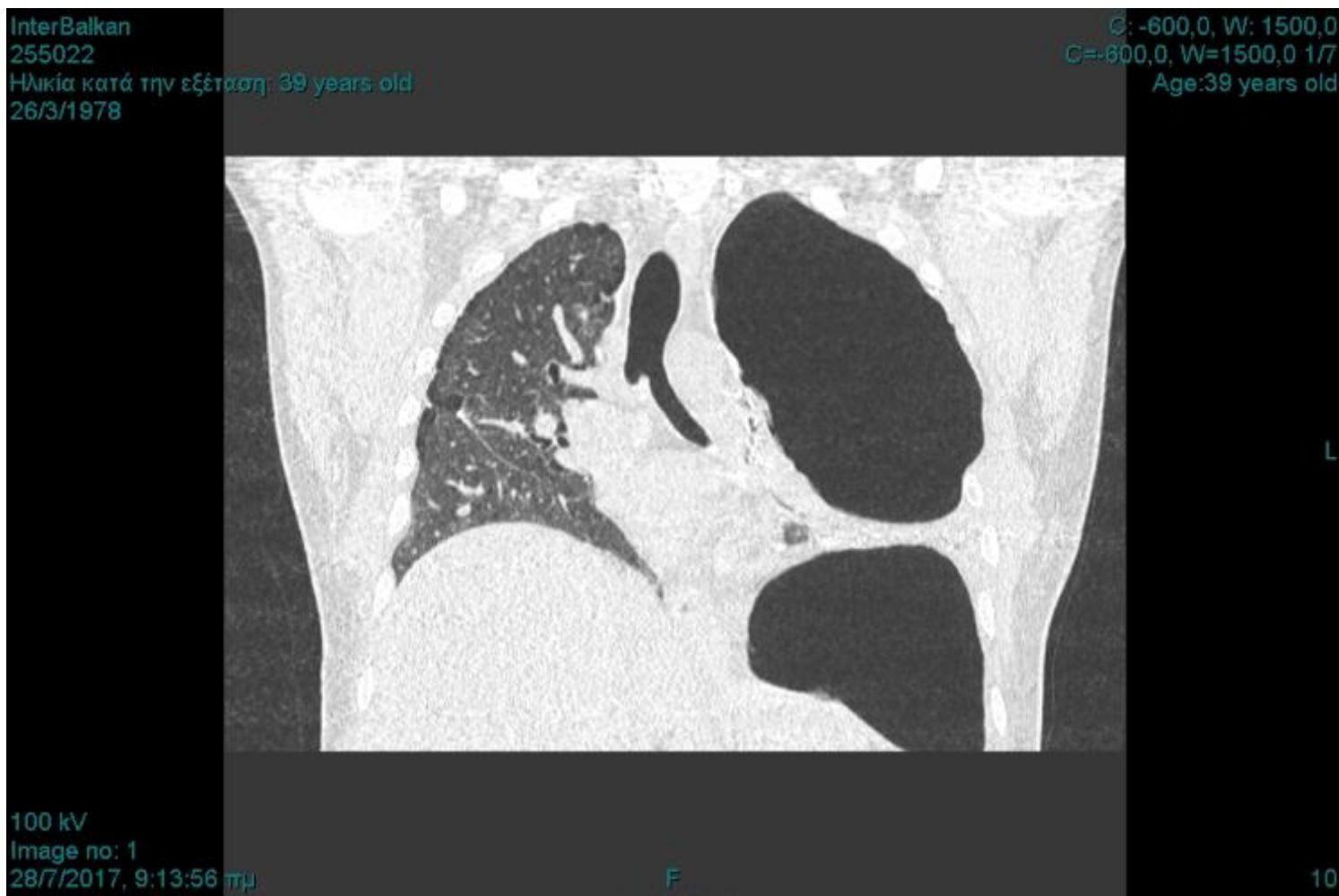(55th postOp) Chest CT Scan

Case 1



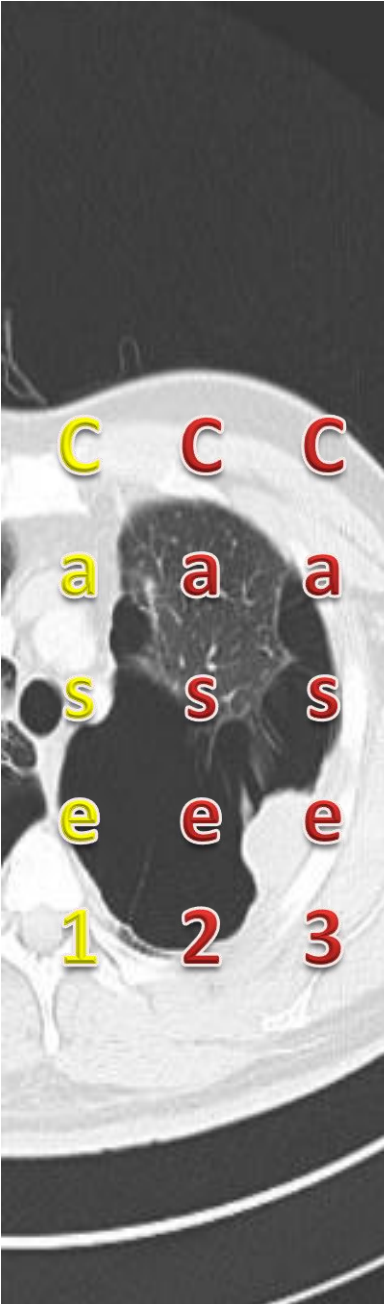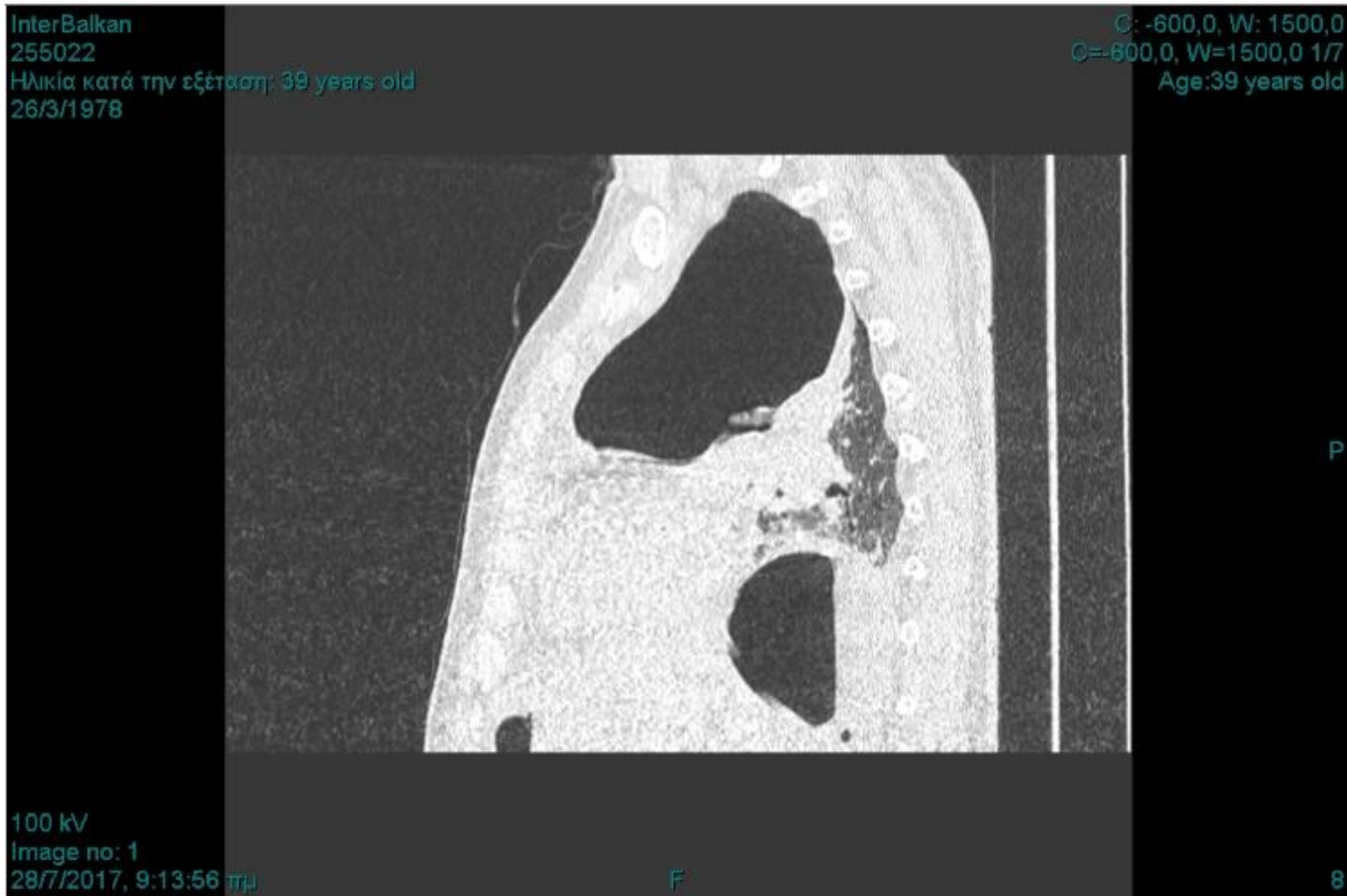
(55th postOp) Chest CT Scan

Case 1



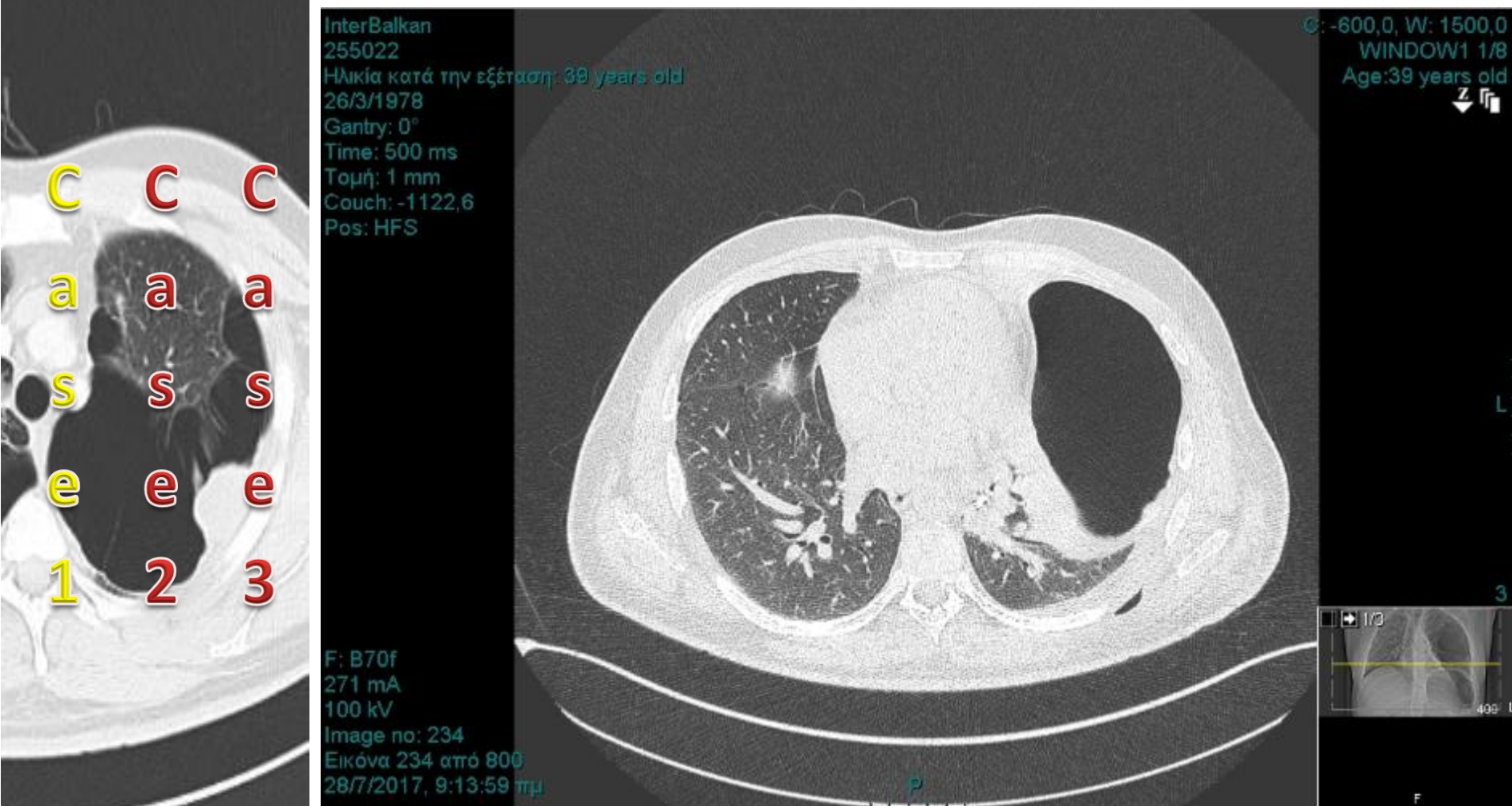(55th postOp) Chest CT Scan

Case 1



(55th postOp) Chest CT Scan

Case 1



(55th postOp) Chest CT Scan

Case 1

Air space (pocket)

1. Reoperation
2. Chest tube insertion
3. VATS exploration
4. Watch & see



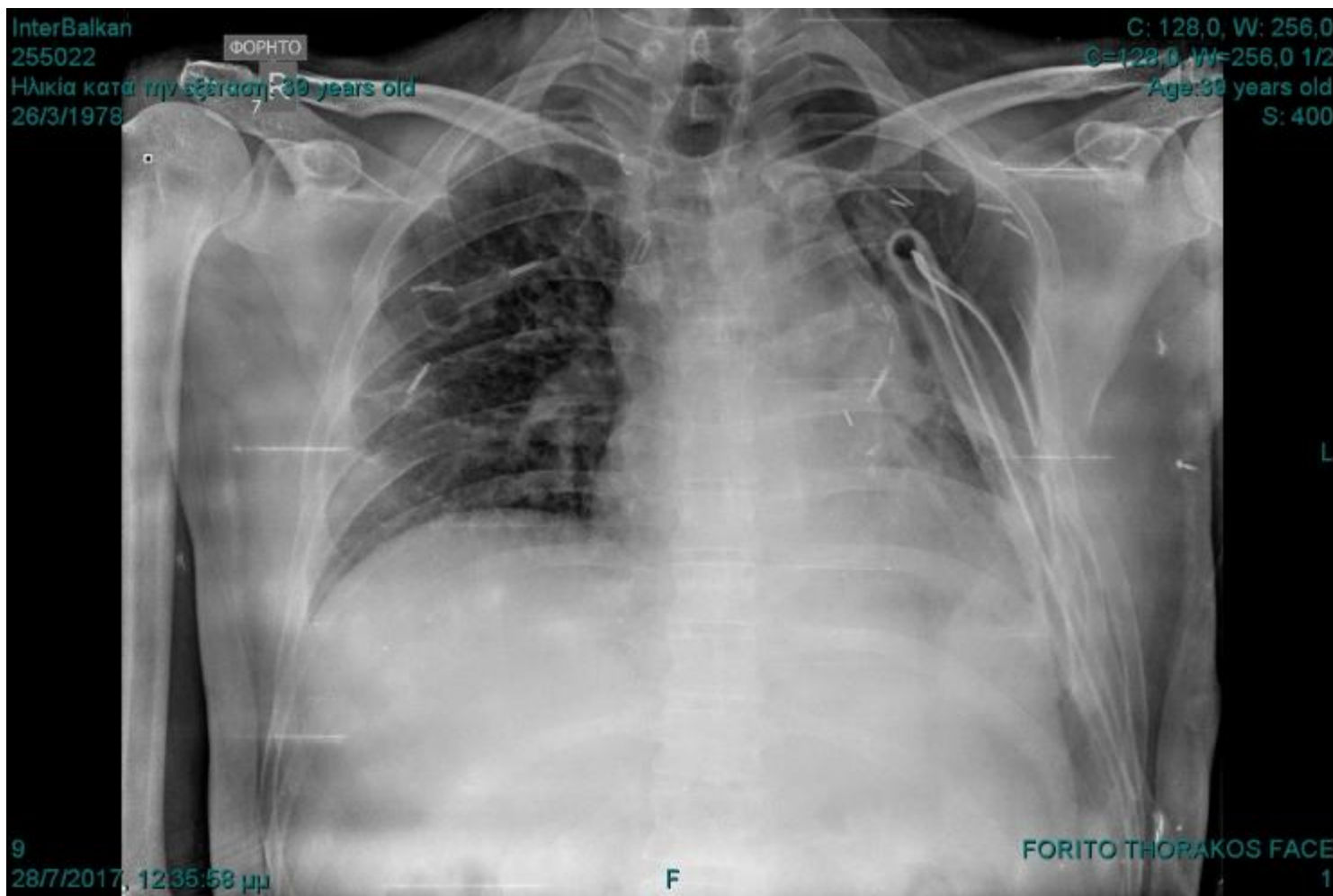
Case 1

Air space (pocket)

1. Reoperation
2. **Chest tube insertion**
3. VATS exploration
4. Watch & see

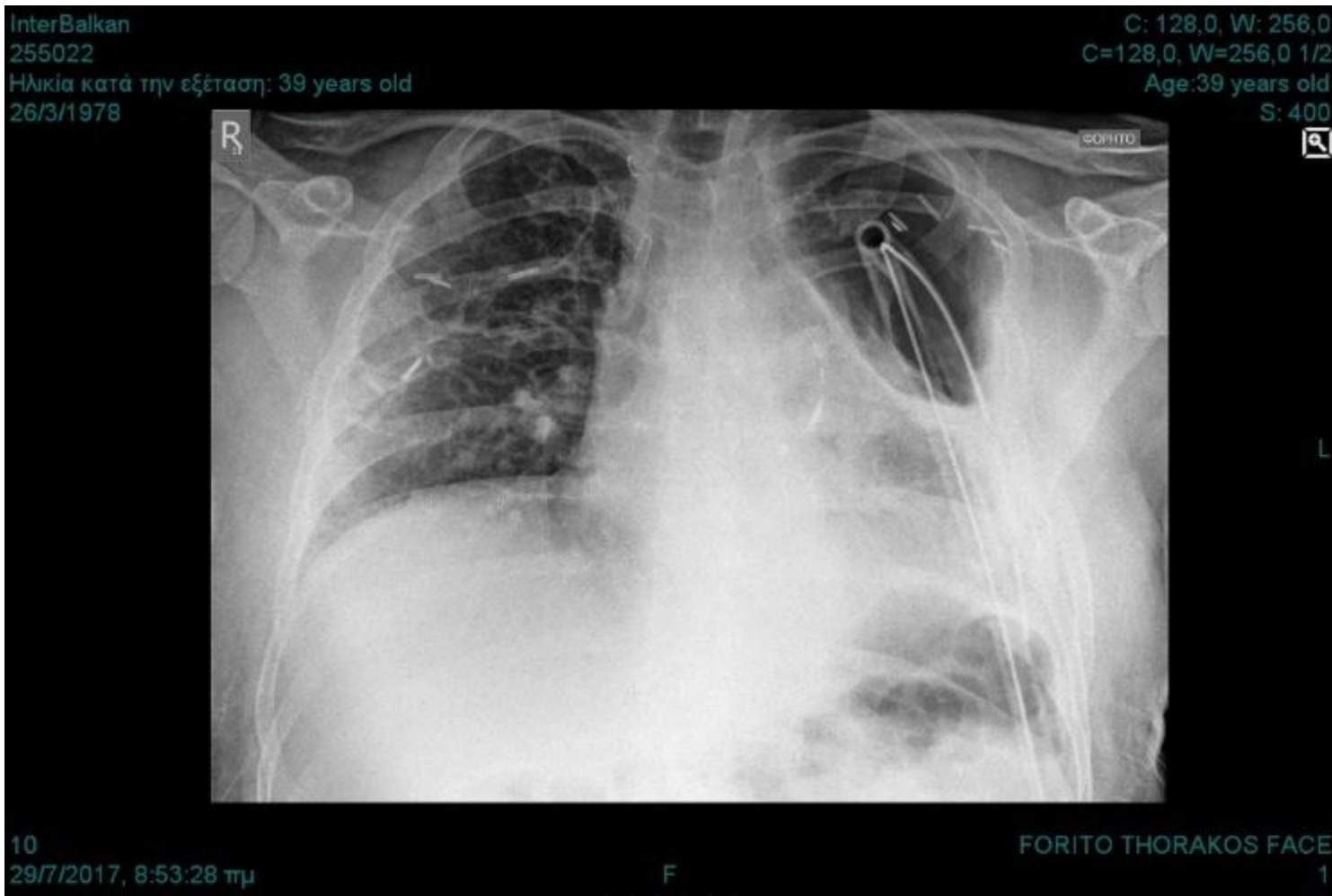


Case 1



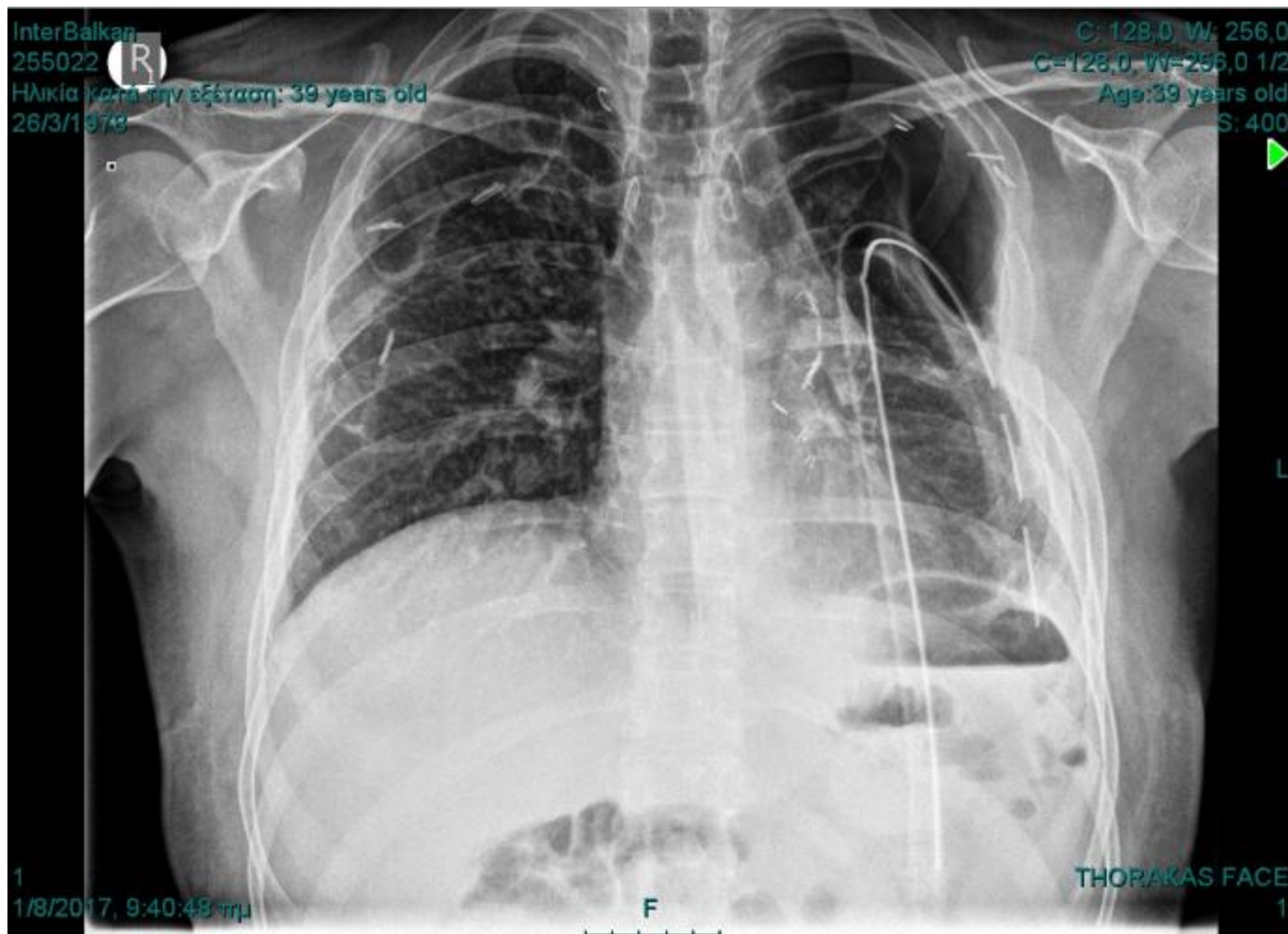
(56th postOp) Chest X-ray (F)

Case 1



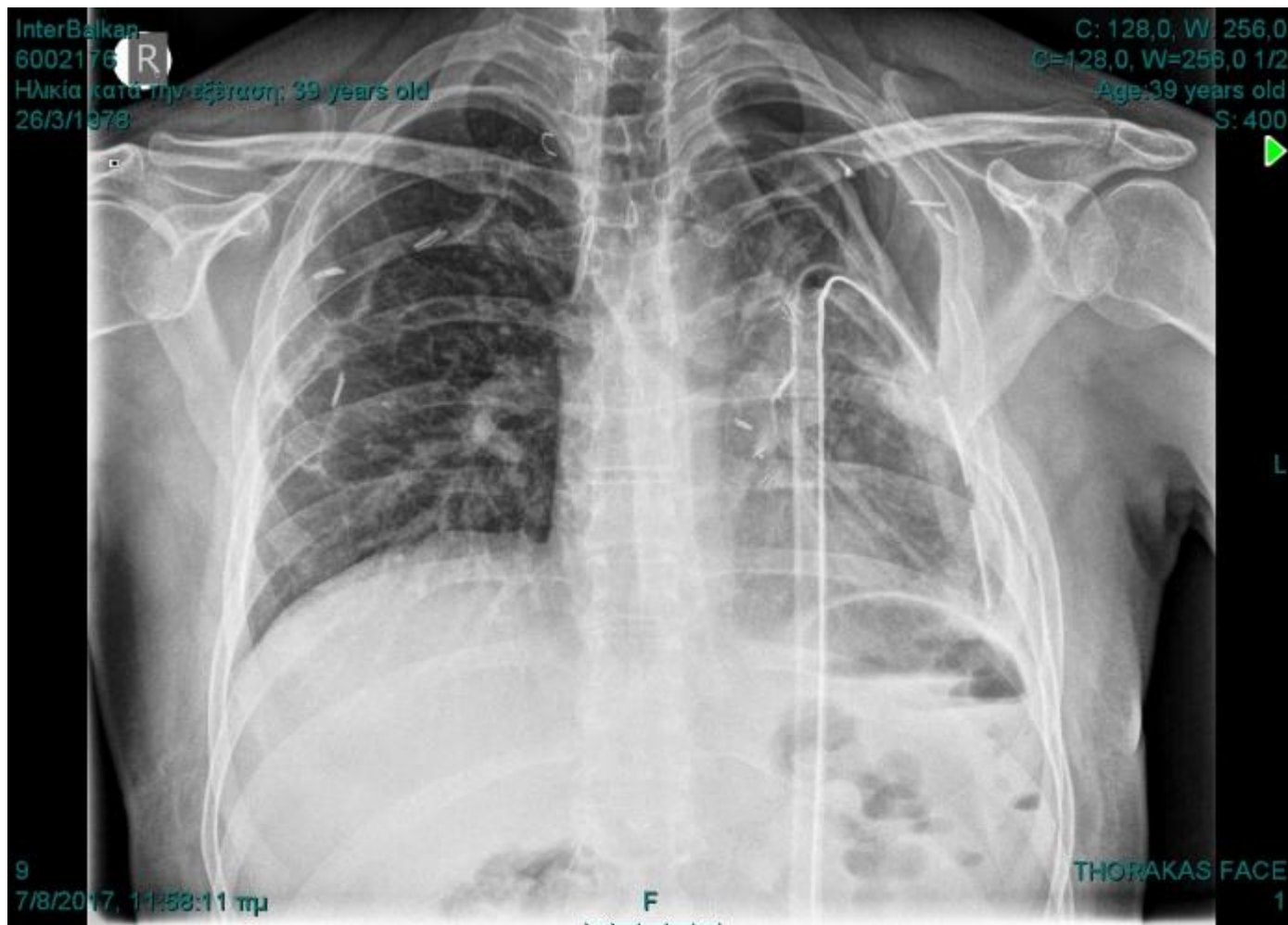(57th postOp) Chest X-ray (F)

Case 1



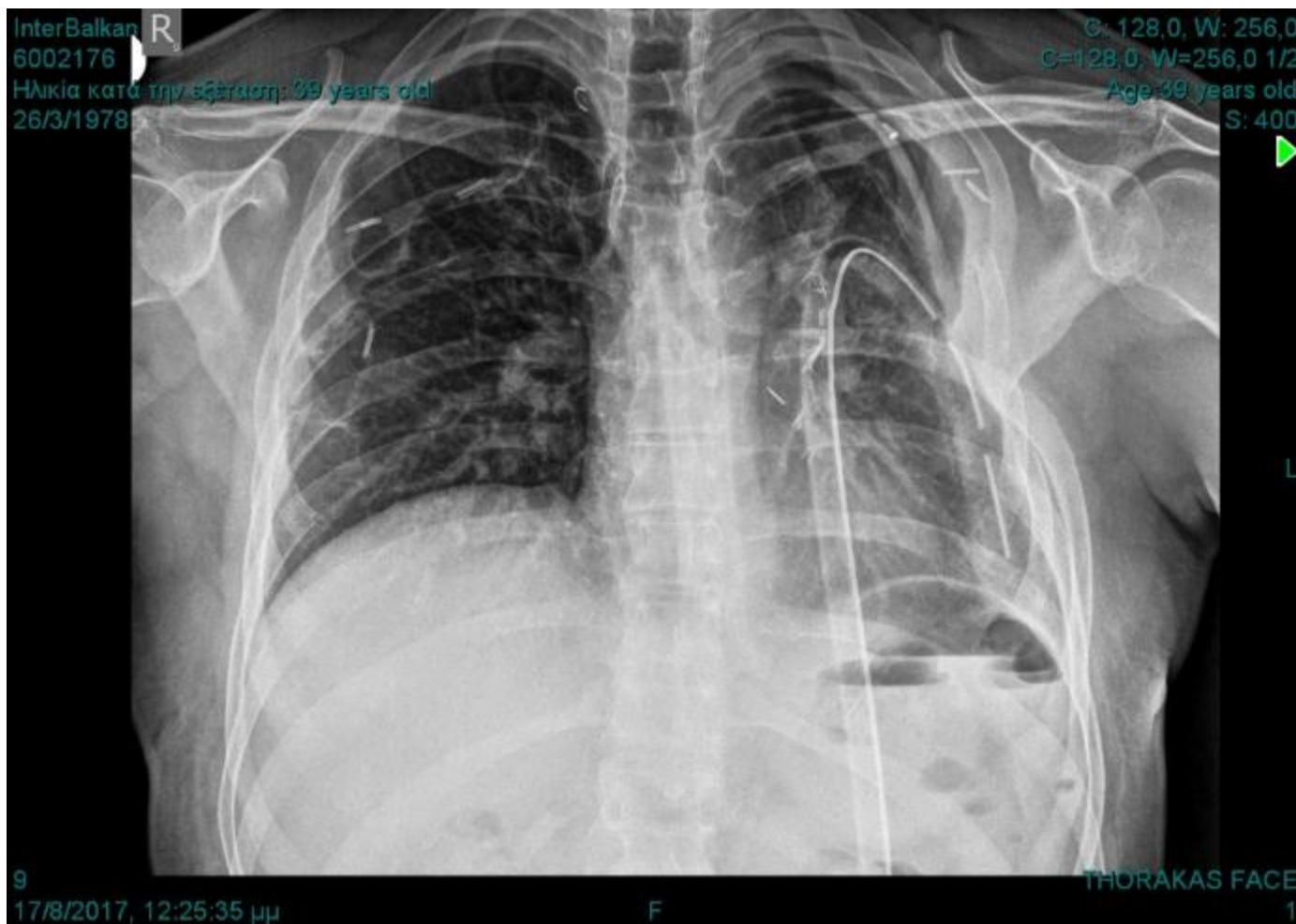
(60th postOp) Chest X-ray (F)

Case 1



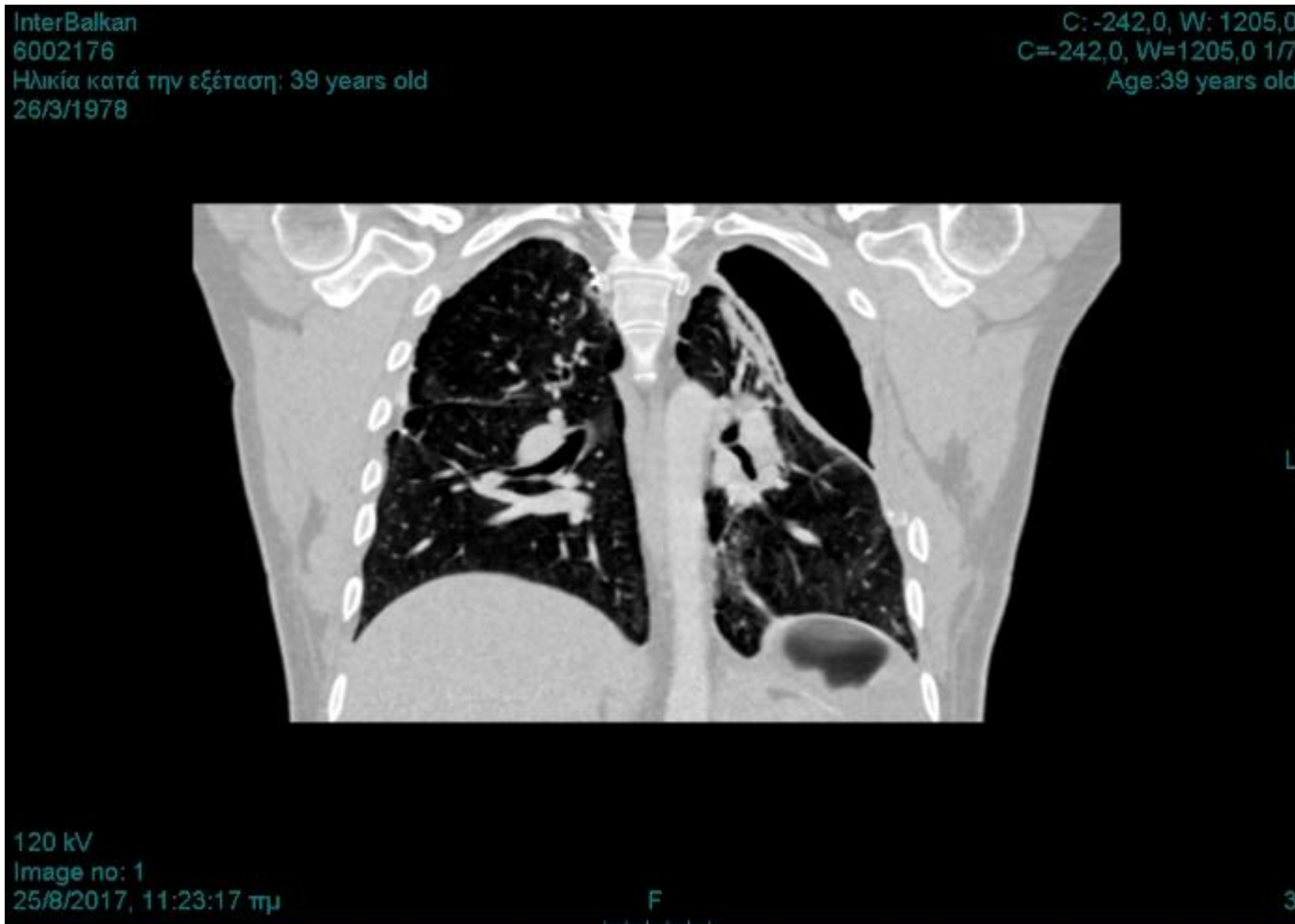
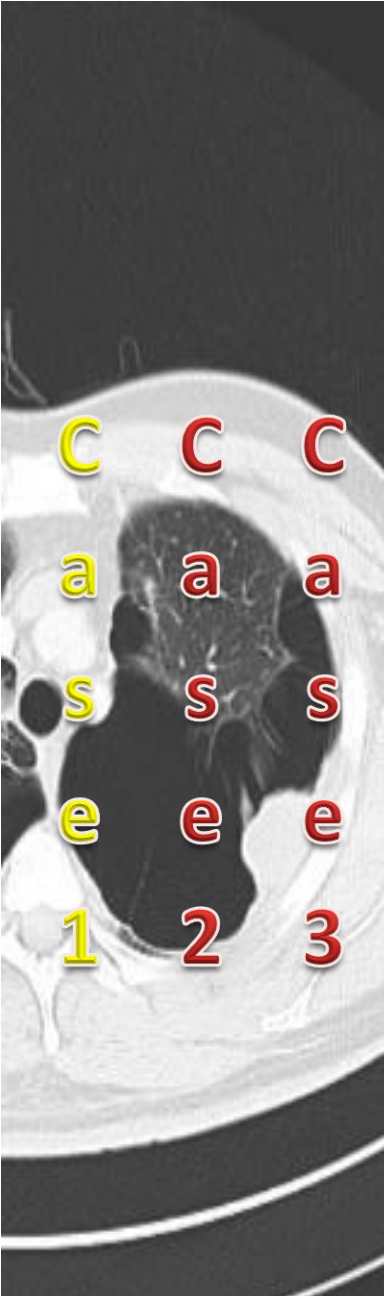
(66th postOp) Chest X-ray (F)

Case 1



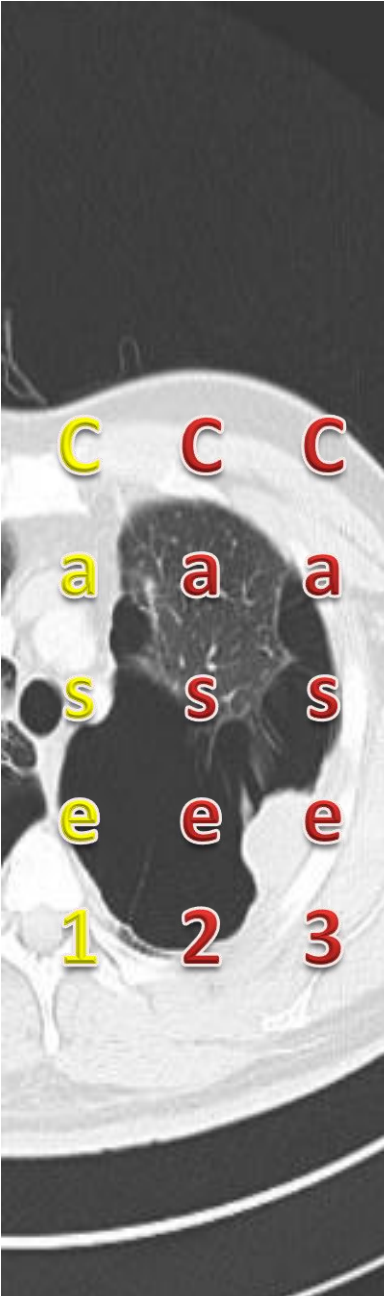
(76th postOp) Chest X-ray (F)

Case 1



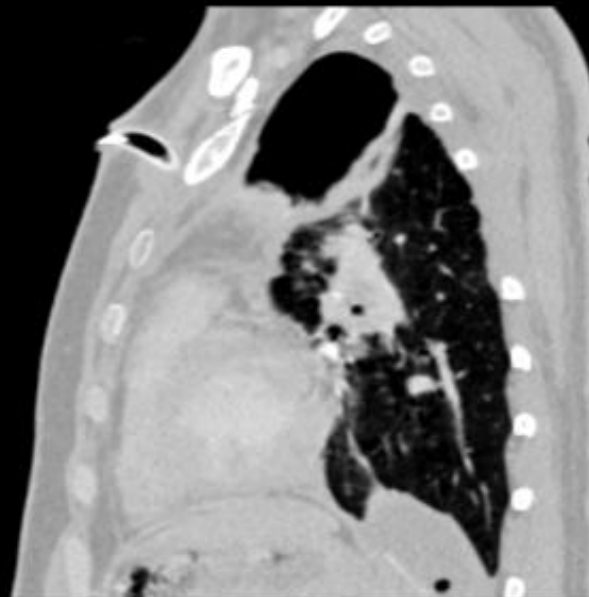
(84th postOp) Chest CT Scan

Case 1



InterBalkan
6002176
Ηλικία κατά την εξέταση: 39 years old
26/3/1978

C: -242,0, W: 1205,0
C=-242,0, W=1205,0 1/7
Age:39 years old



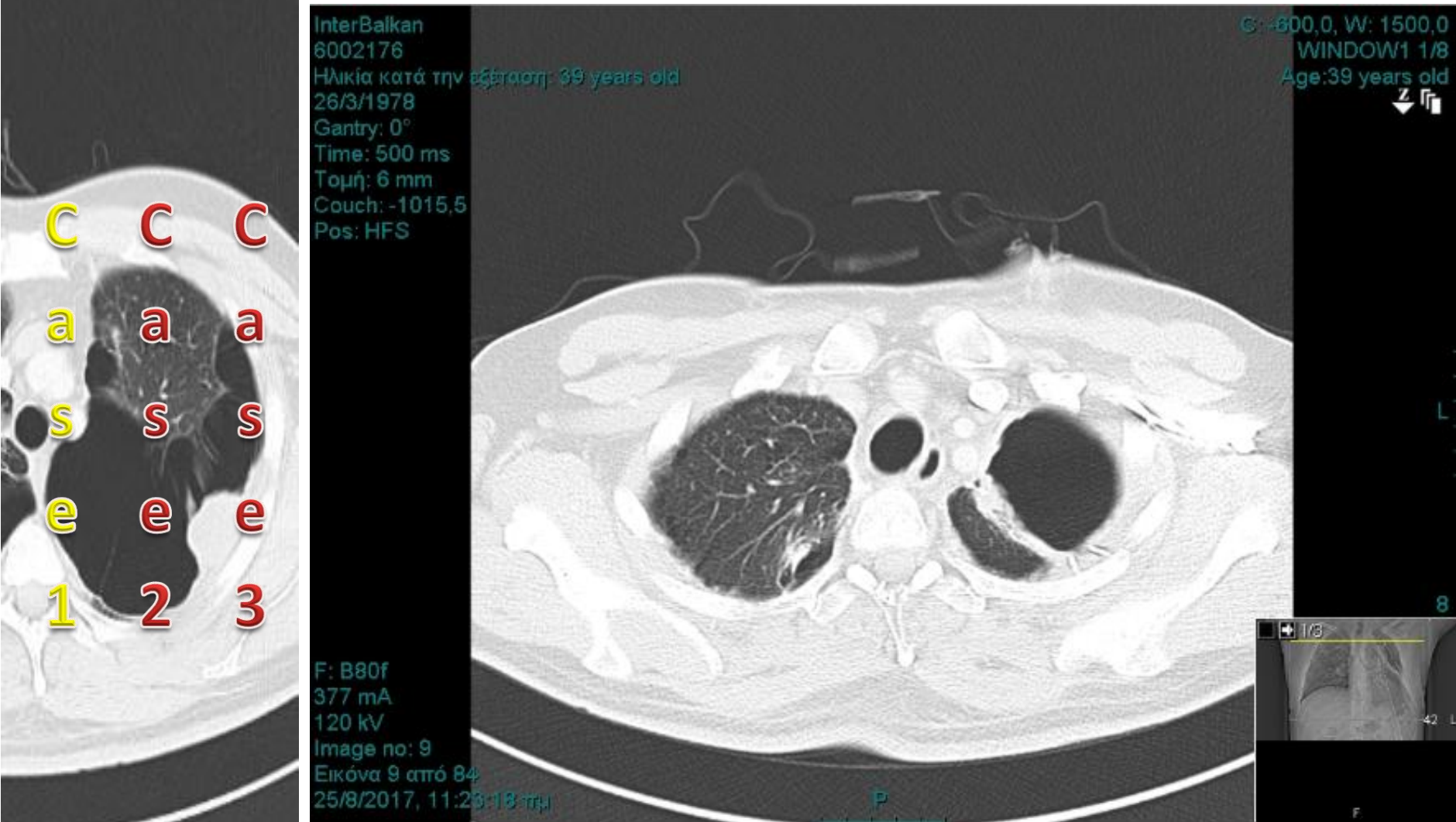120 kV
Image no: 1
25/8/2017, 11:23:17 πμ

F

4

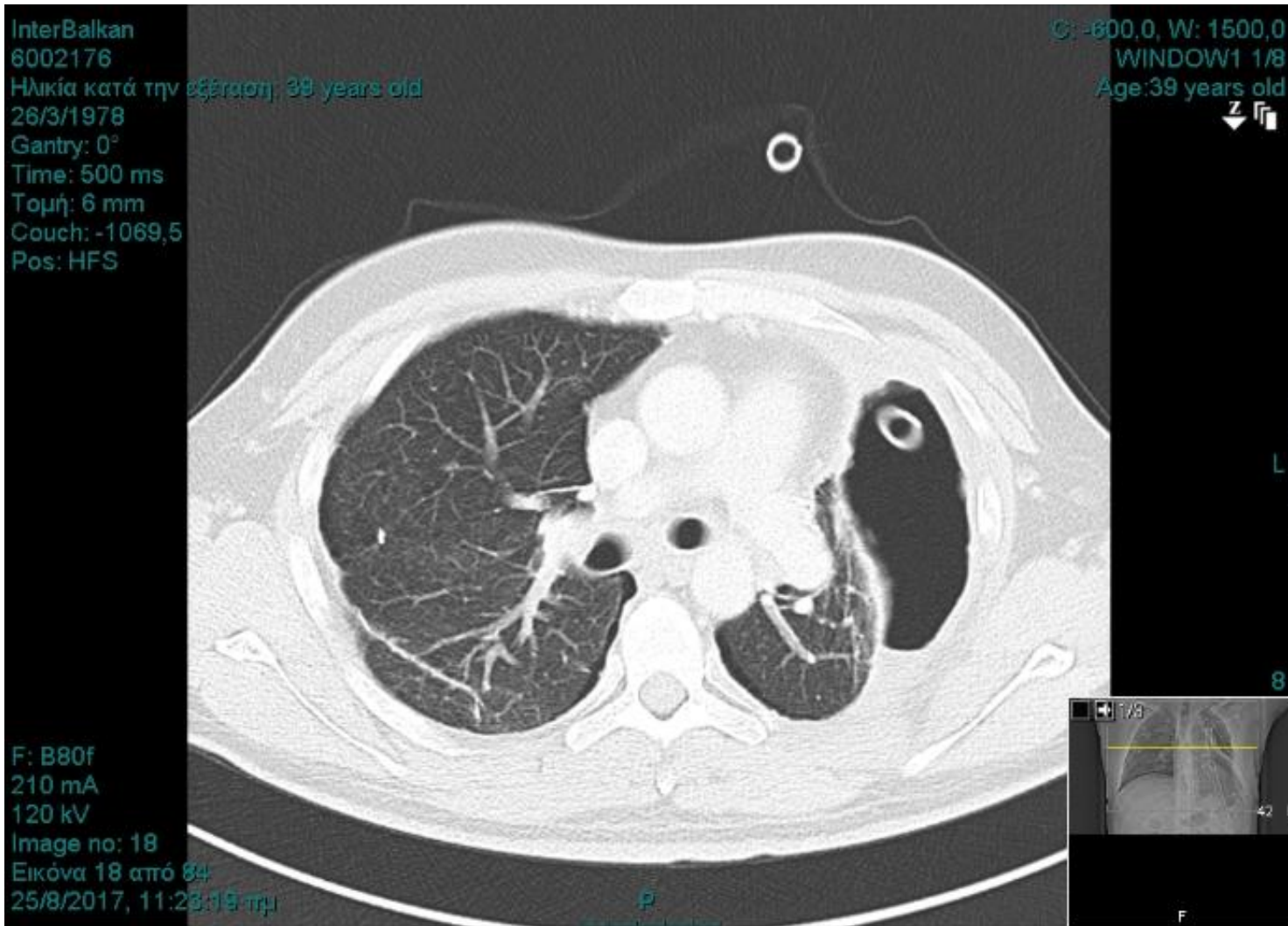
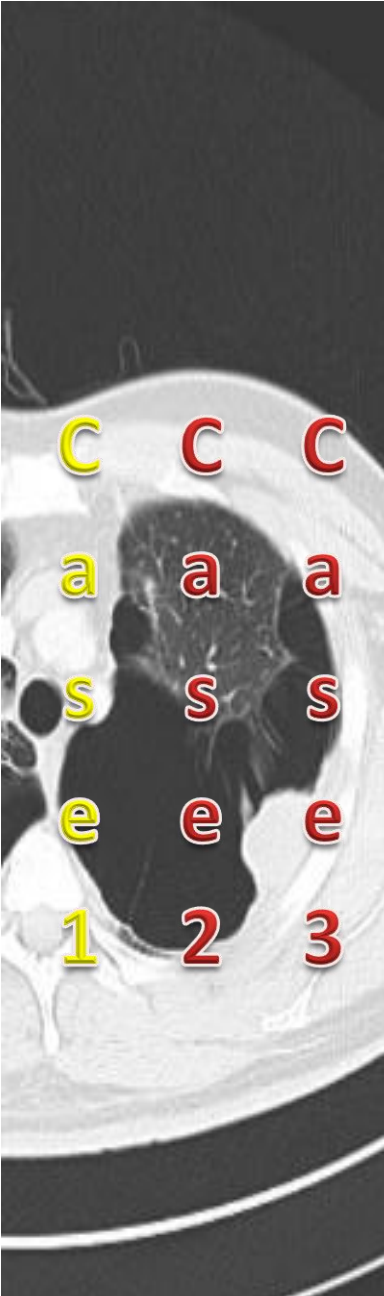
(84th postOp) Chest CT Scan

Case 1



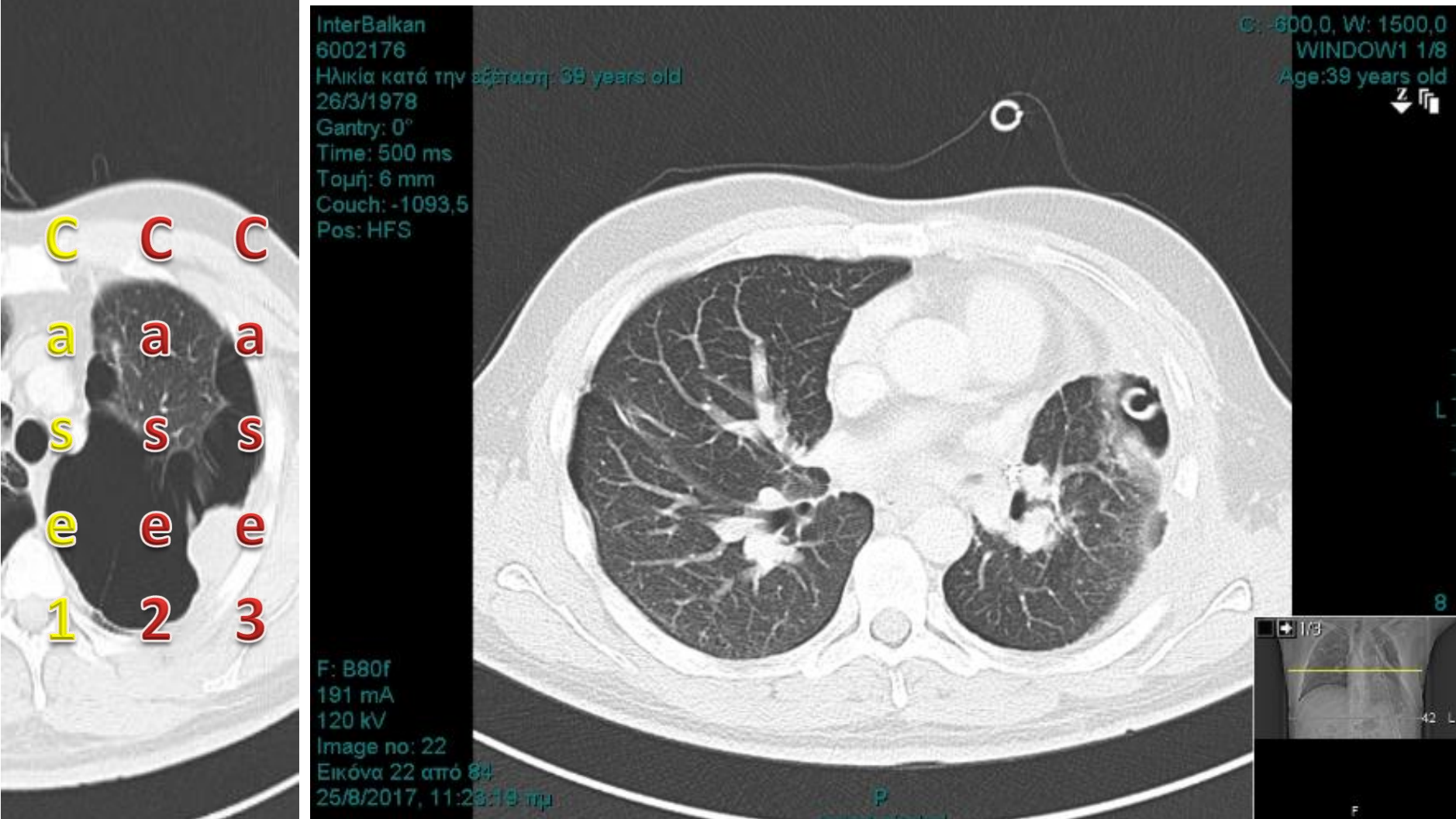
(84th postOp) Chest CT Scan

Case 1



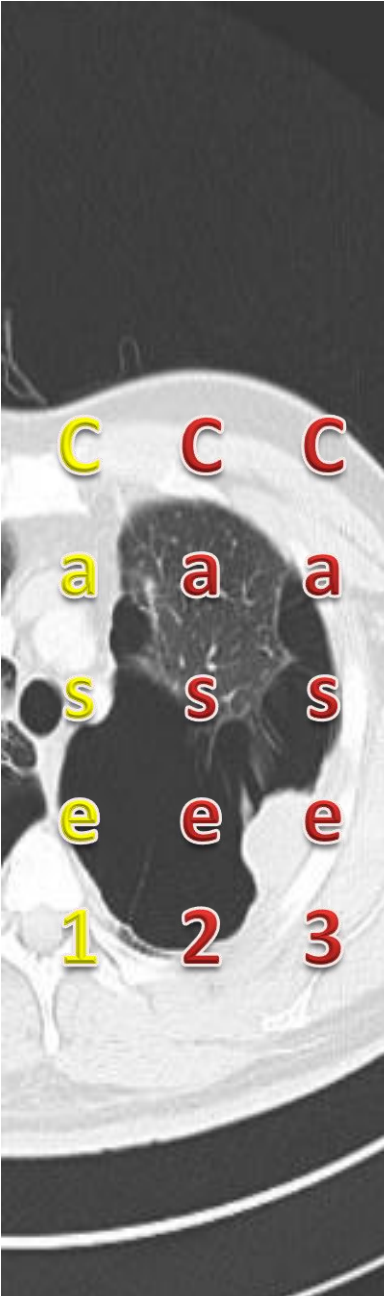
(84th postOp) Chest CT Scan

Case 1



(84th postOp) Chest CT Scan

Case 1



Chest drain removal

(85^h postOp)

Case 1

Fever - Air space infection

1. Reoperation
2. Chest tube insertion
3. VATS exploration
4. Antibiotics



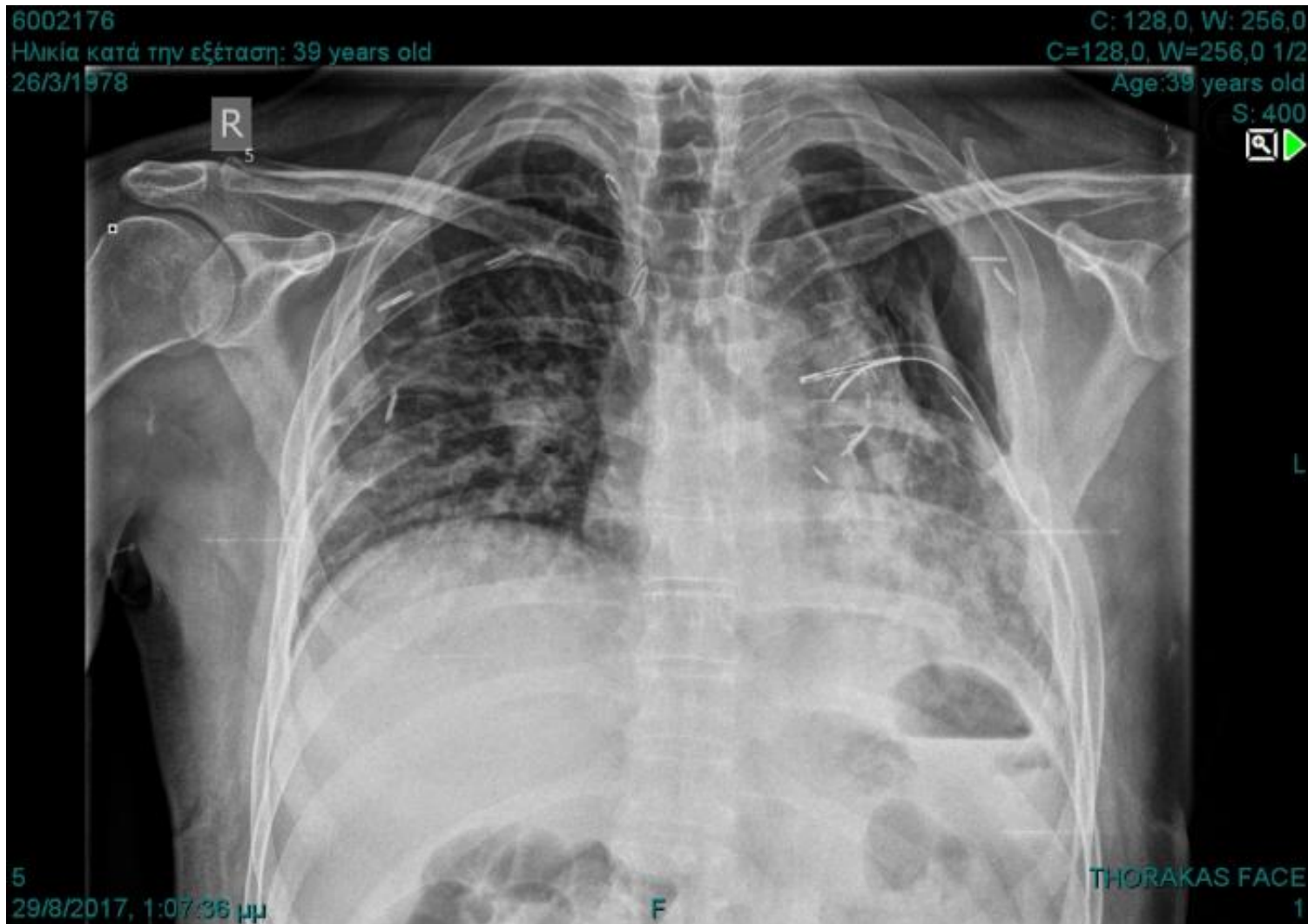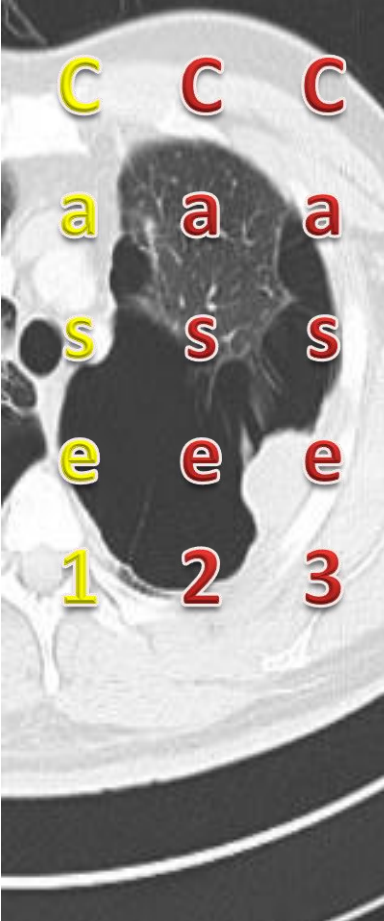Case 1

Fever - Air space infection

1. Reoperation
2. **Chest tube insertion**
3. VATS exploration
4. **Antibiotics**

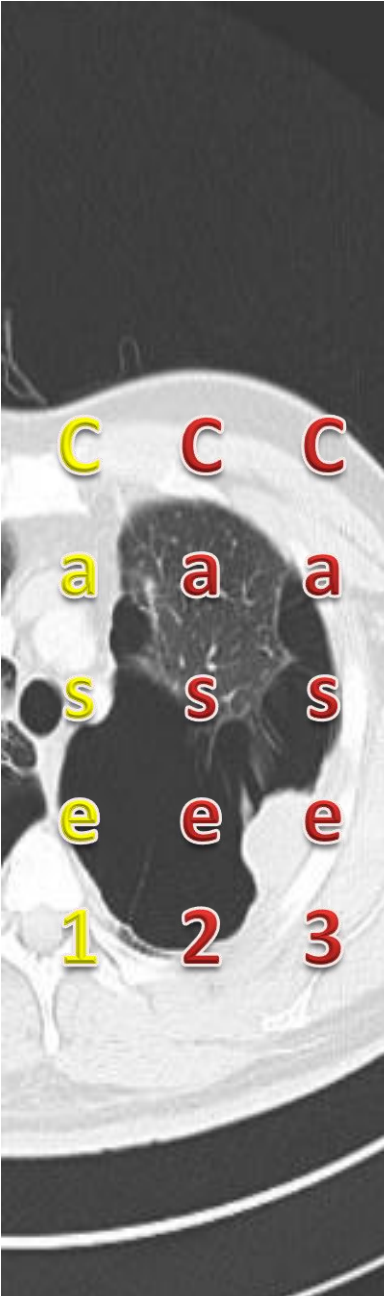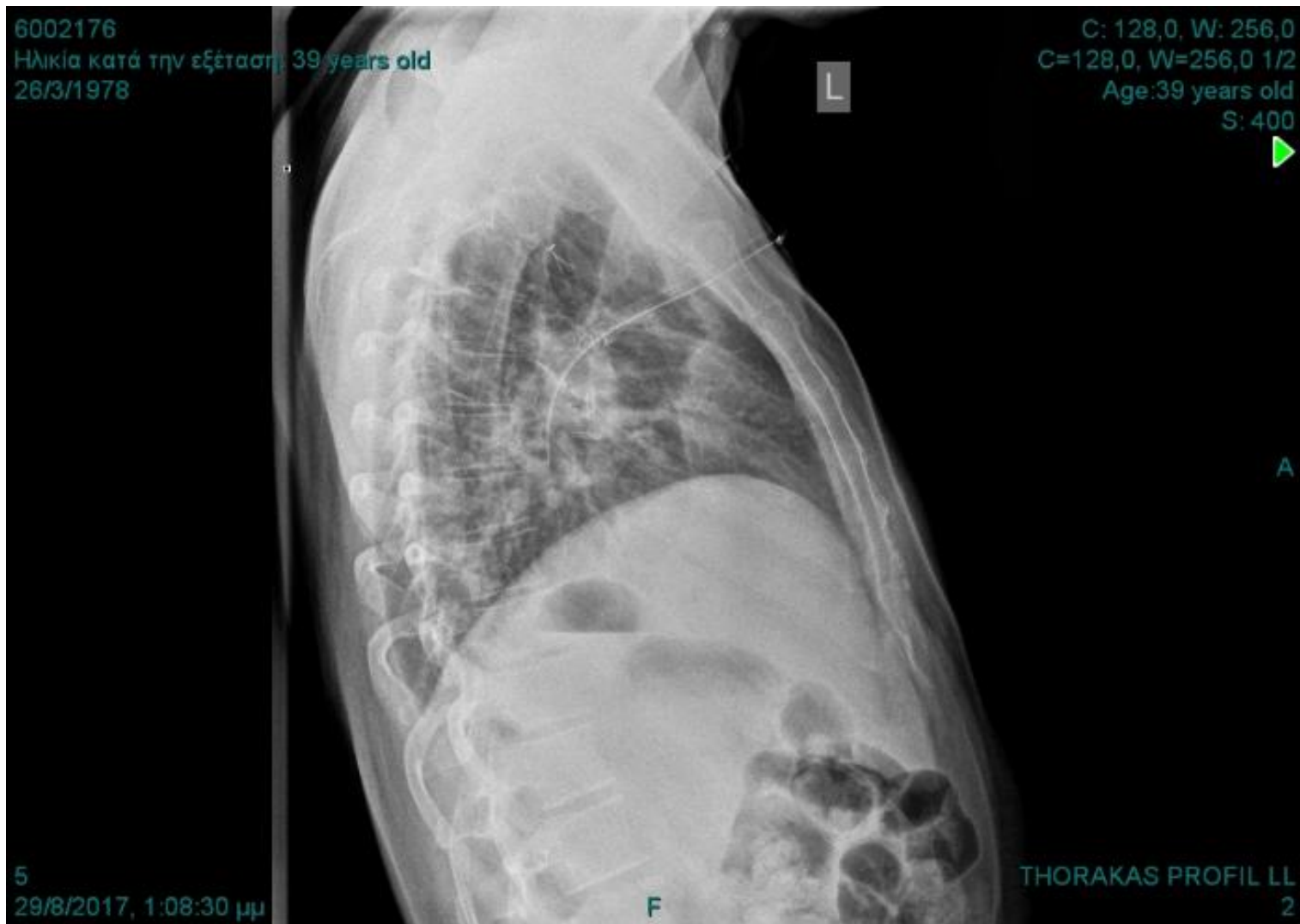


Case 1



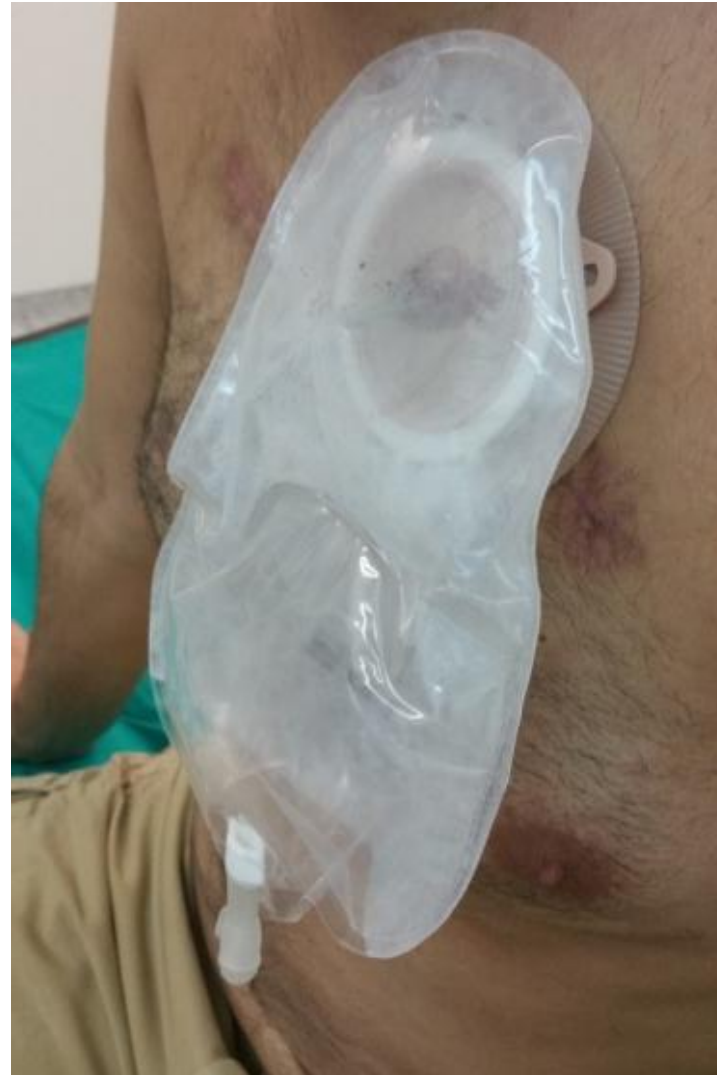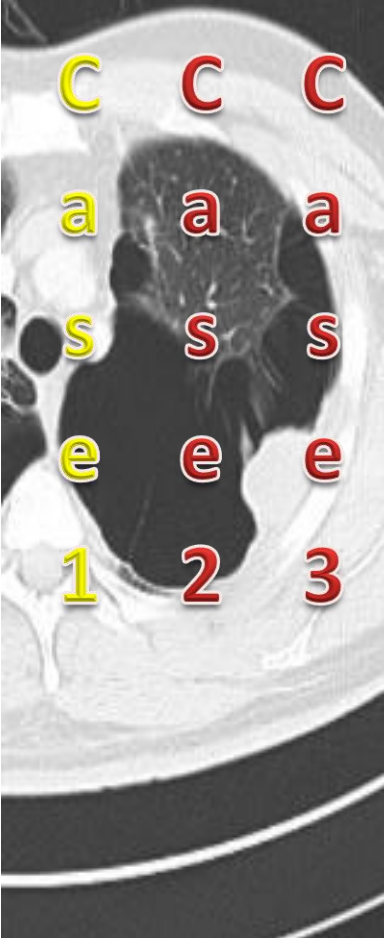(88th postOp) Chest CT Scan

Case 1



(88th postOp) Chest CT Scan

Case 1



(88th postOp)

Case 1

Fever - pus - Aspergillus

1. Reoperation
2. Chest tube insertion
3. VATS exploration
4. Antibiotics
5. Voriconazole
6. Thoracoplasty
7. Thoracostomy



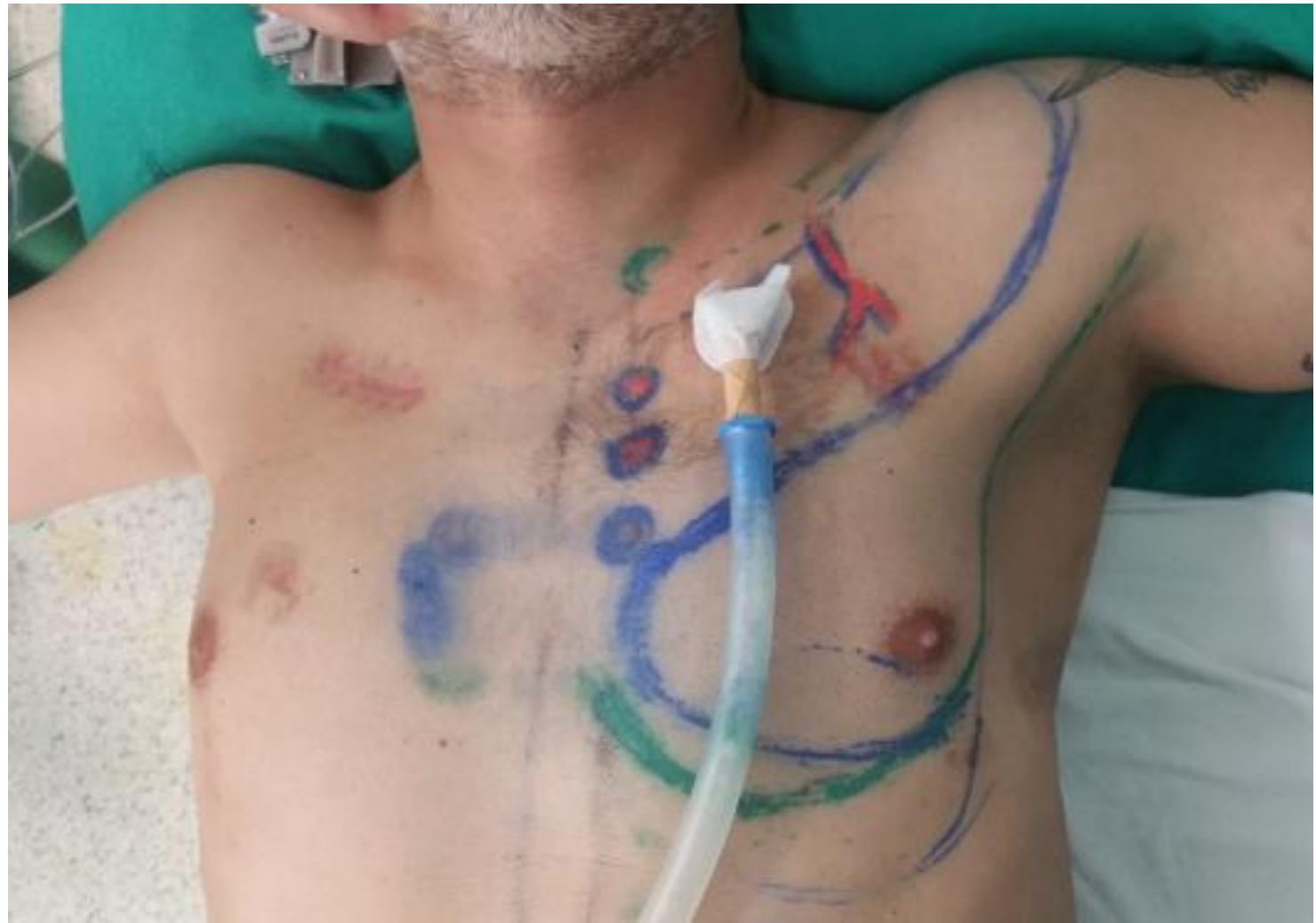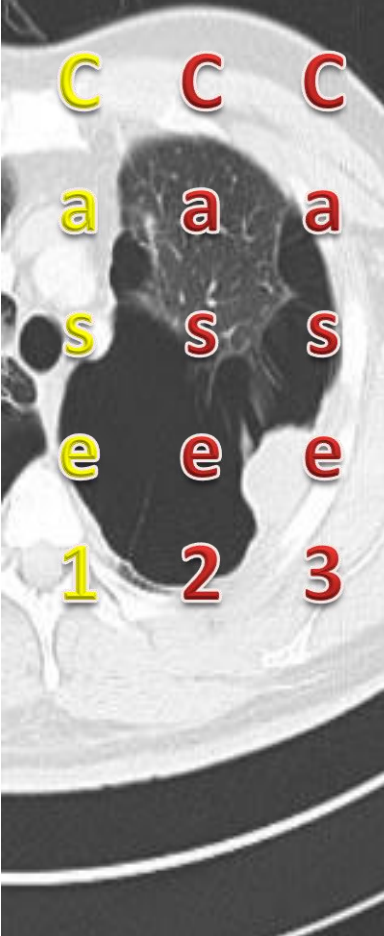Case 1

Fever - pus - Aspergillus

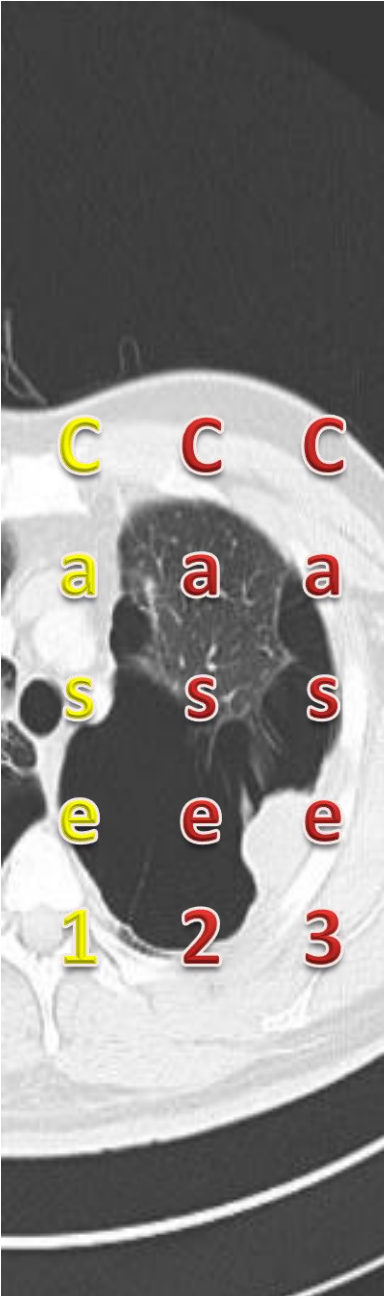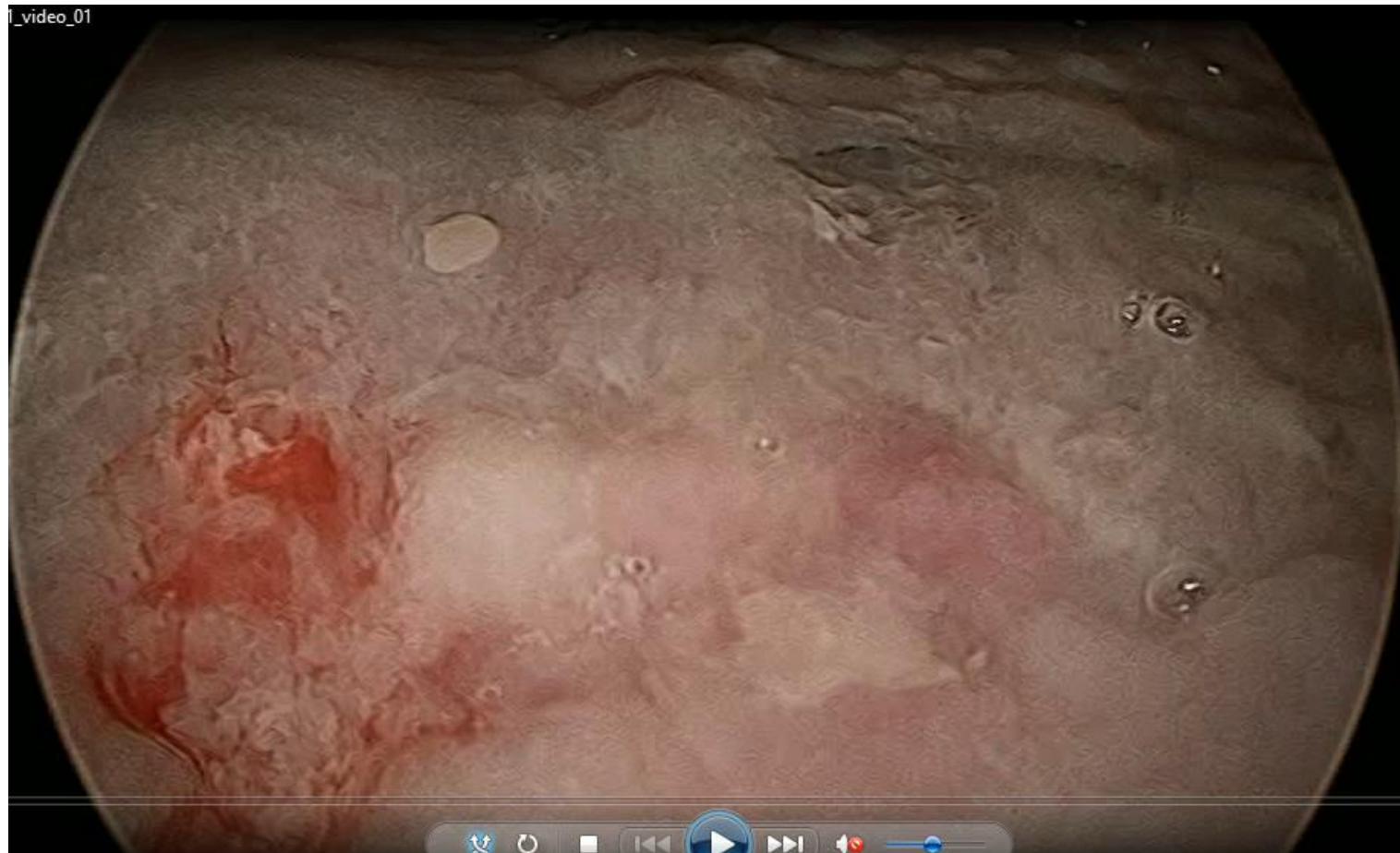
1. Reoperation
2. Chest tube insertion
3. **VATS exploration**
4. **Antibiotics**
5. **Voriconazole**
6. **Thoracoplasty**
7. Thoracostomy



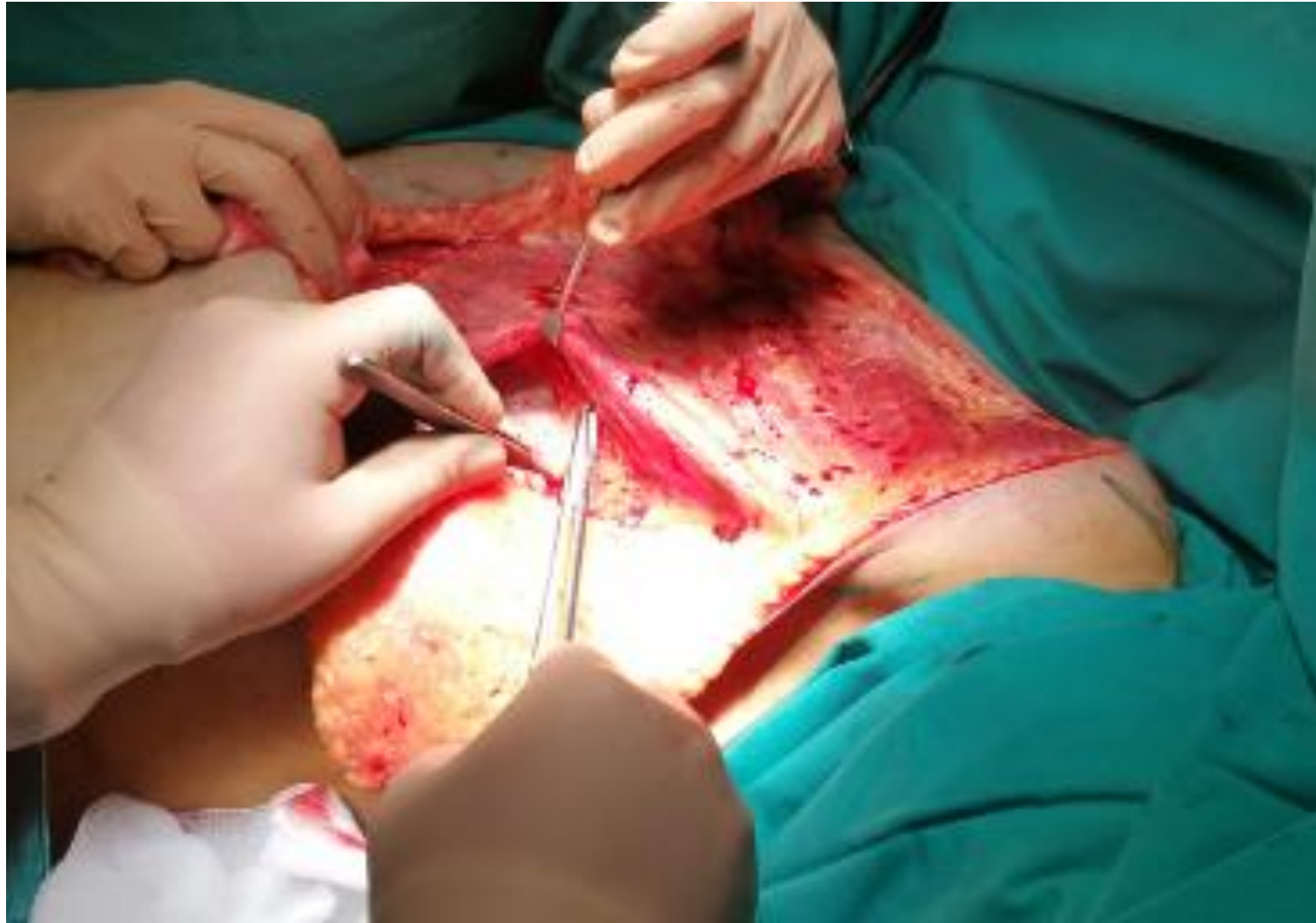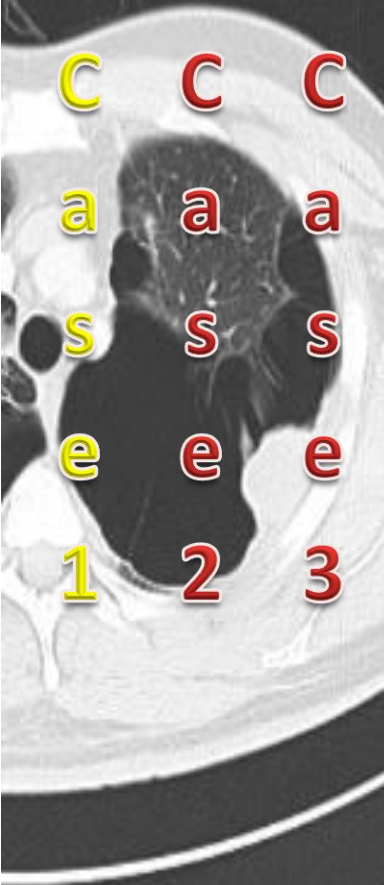Case 1



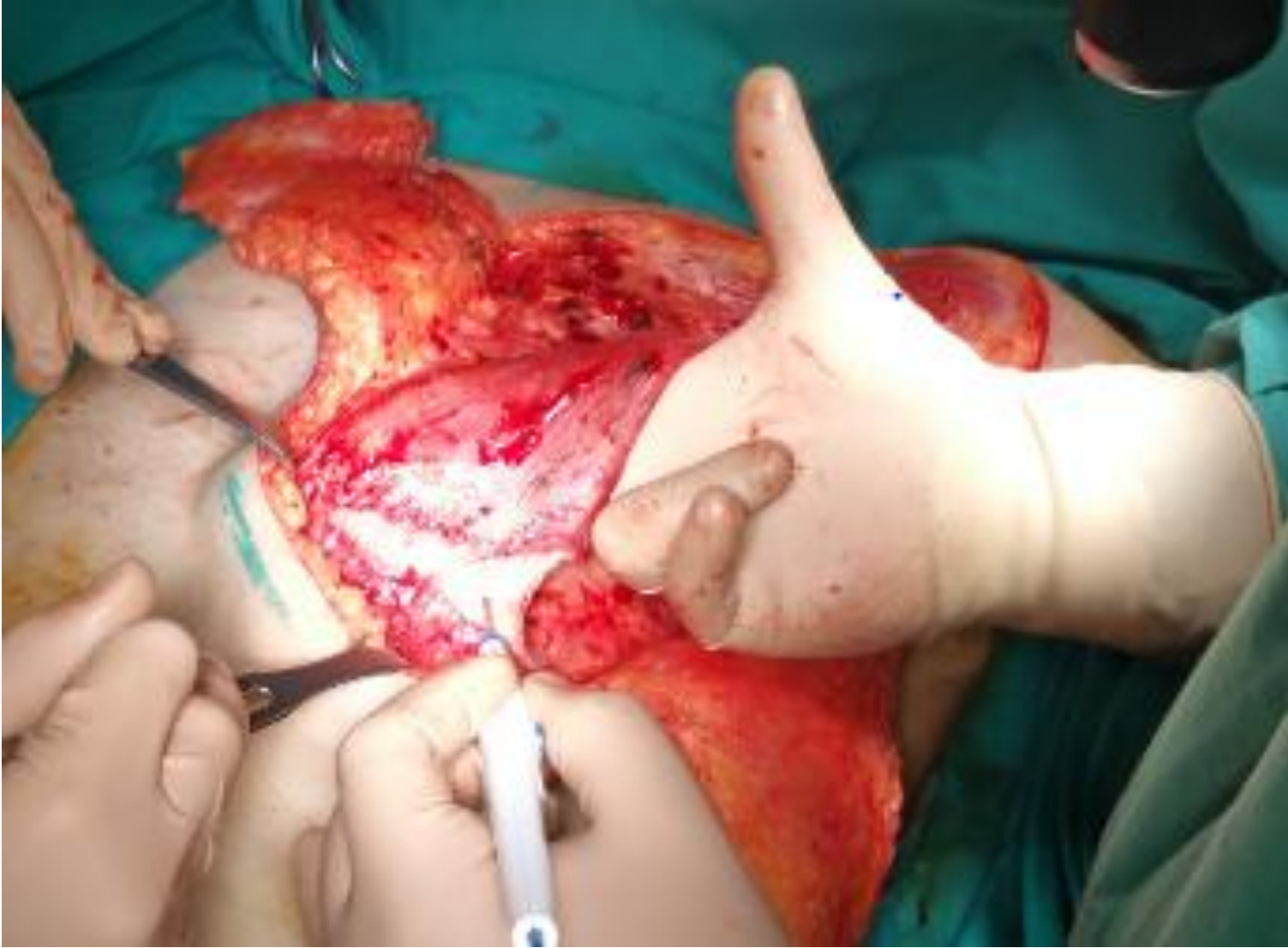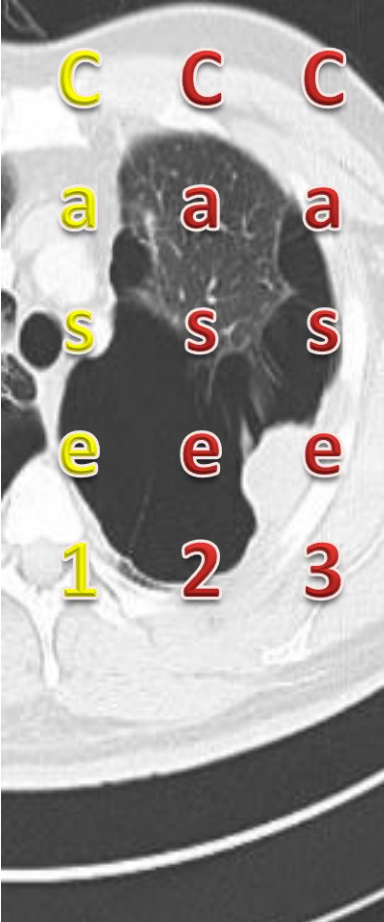Case 1



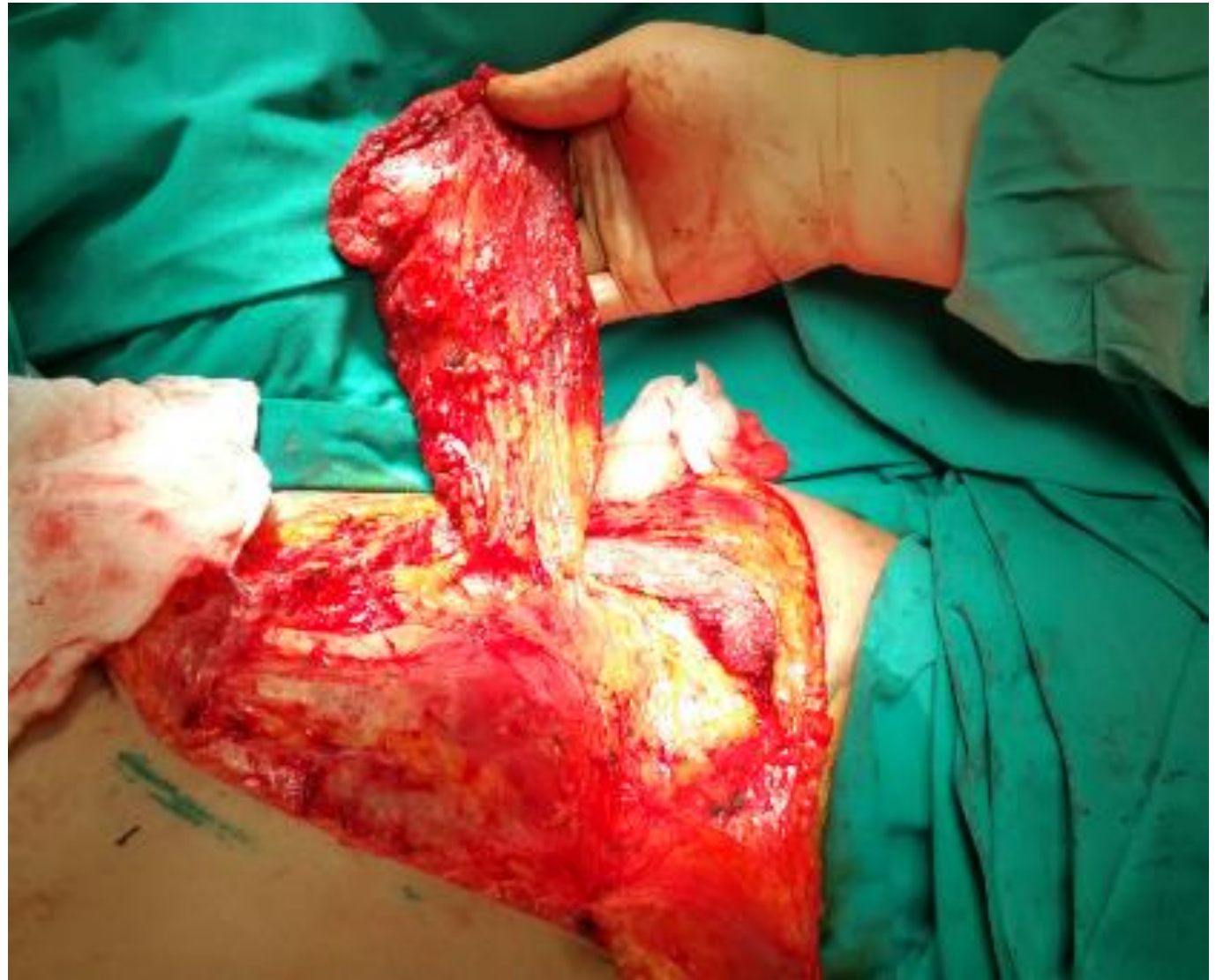Case 1



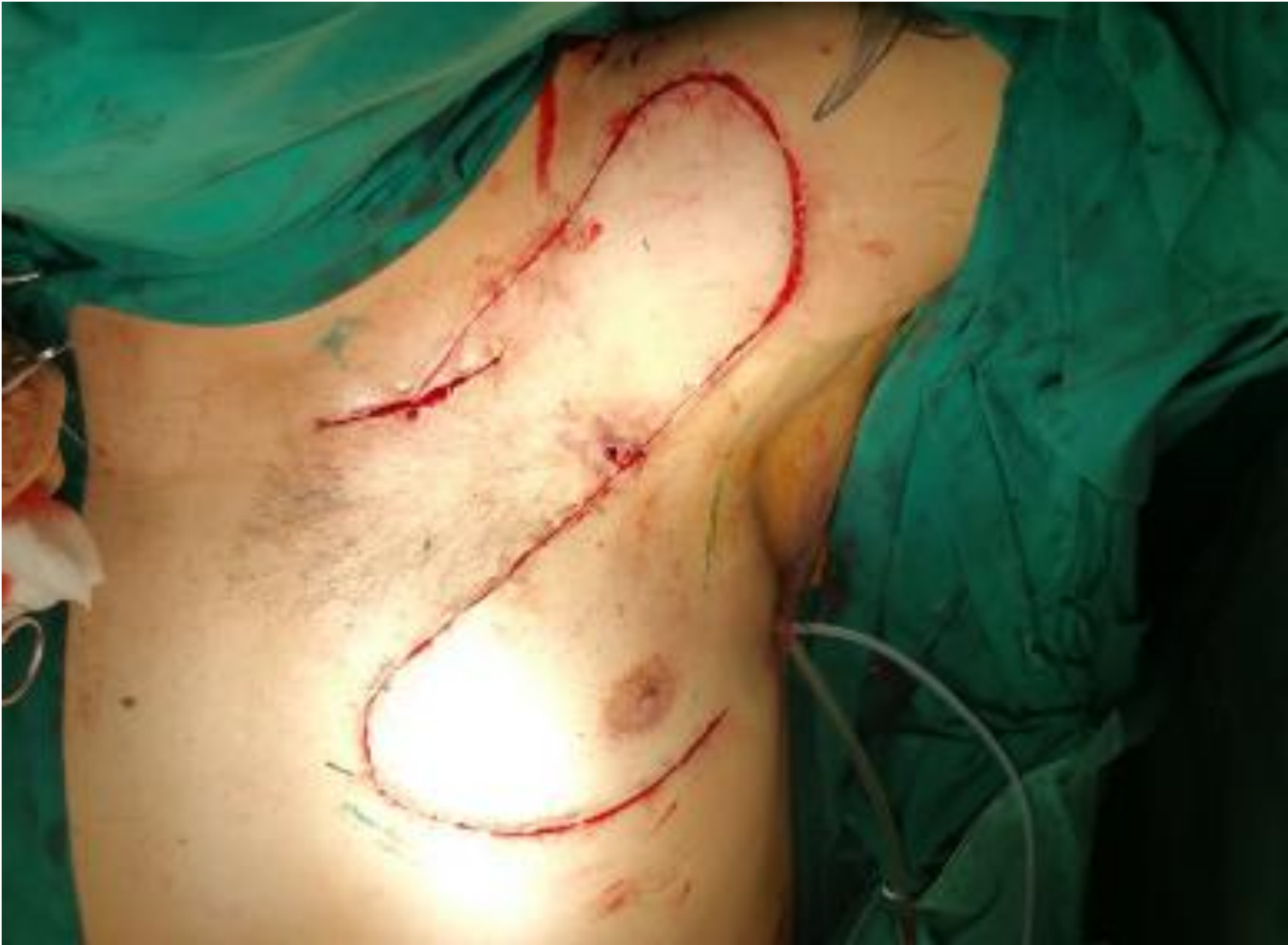Case 1



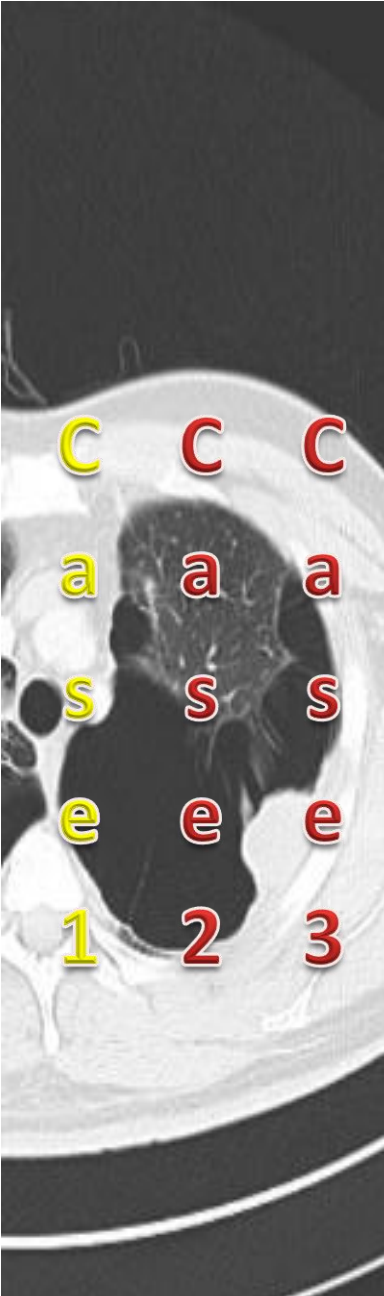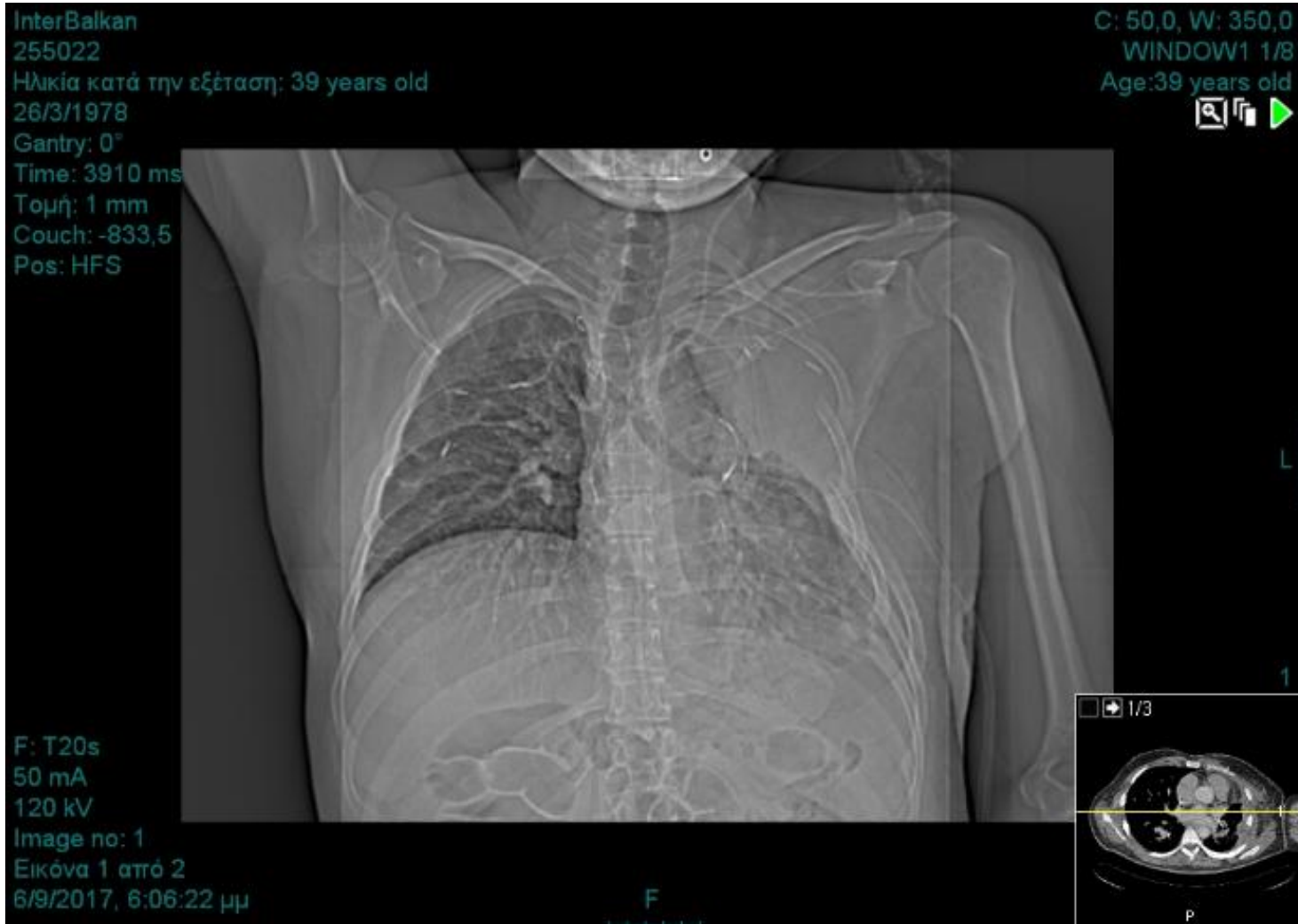
Case 1



Case 1

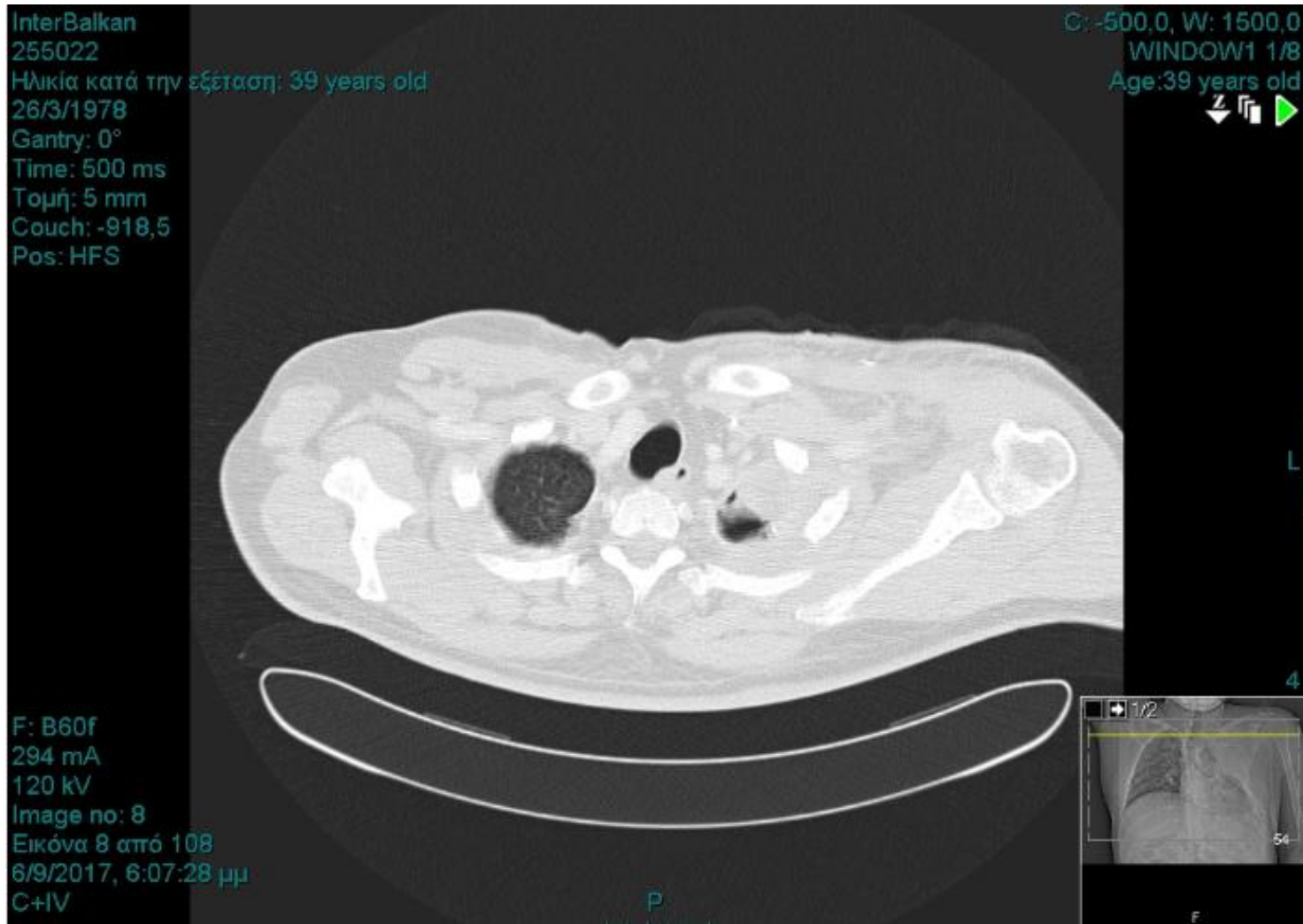
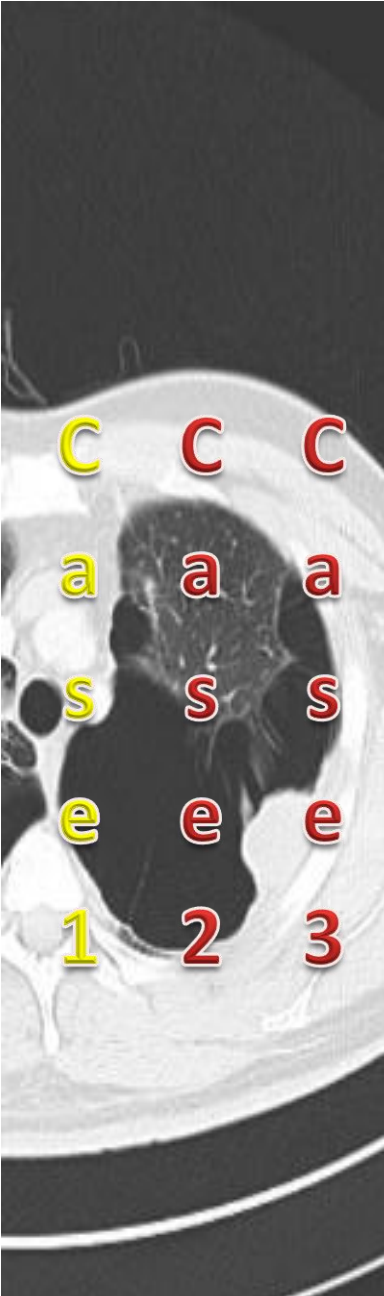


Case 1



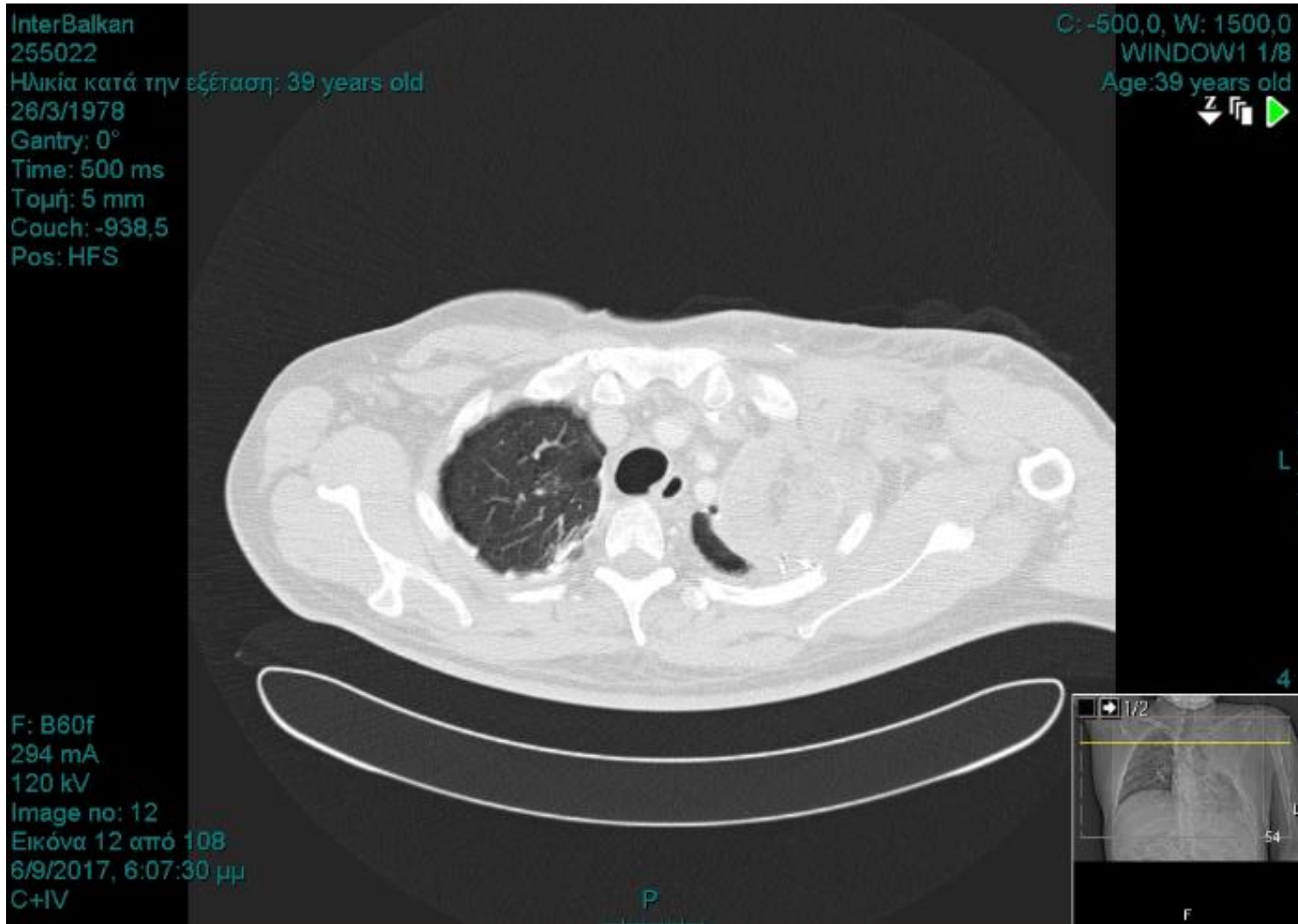
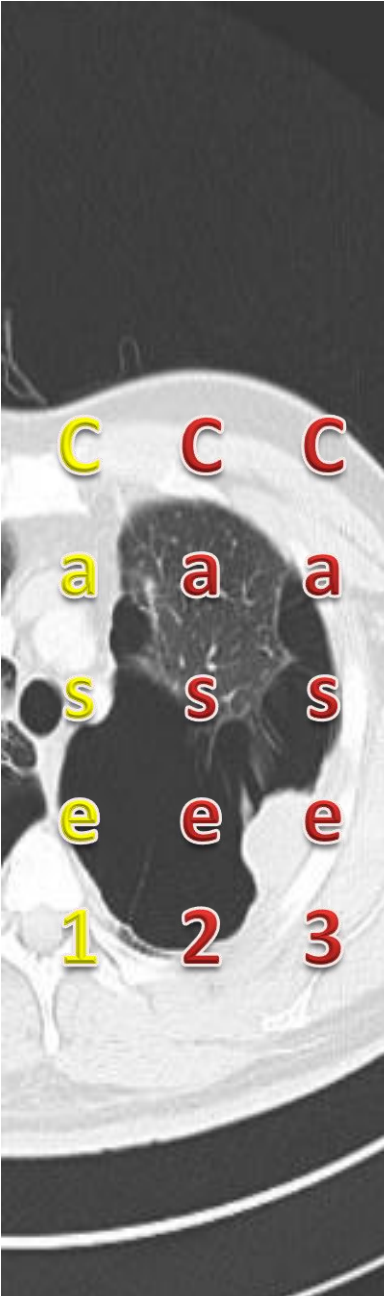
(96th postOp) Chest CT Scan

Case 1



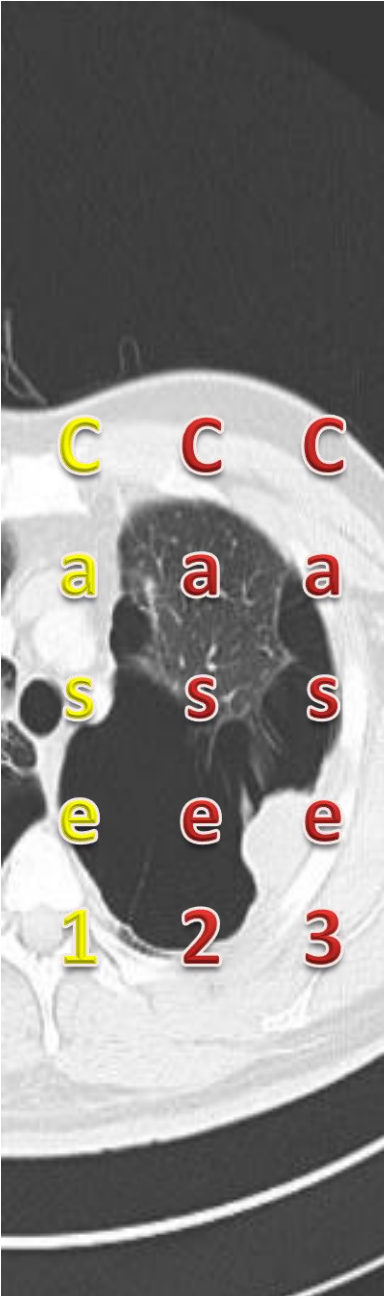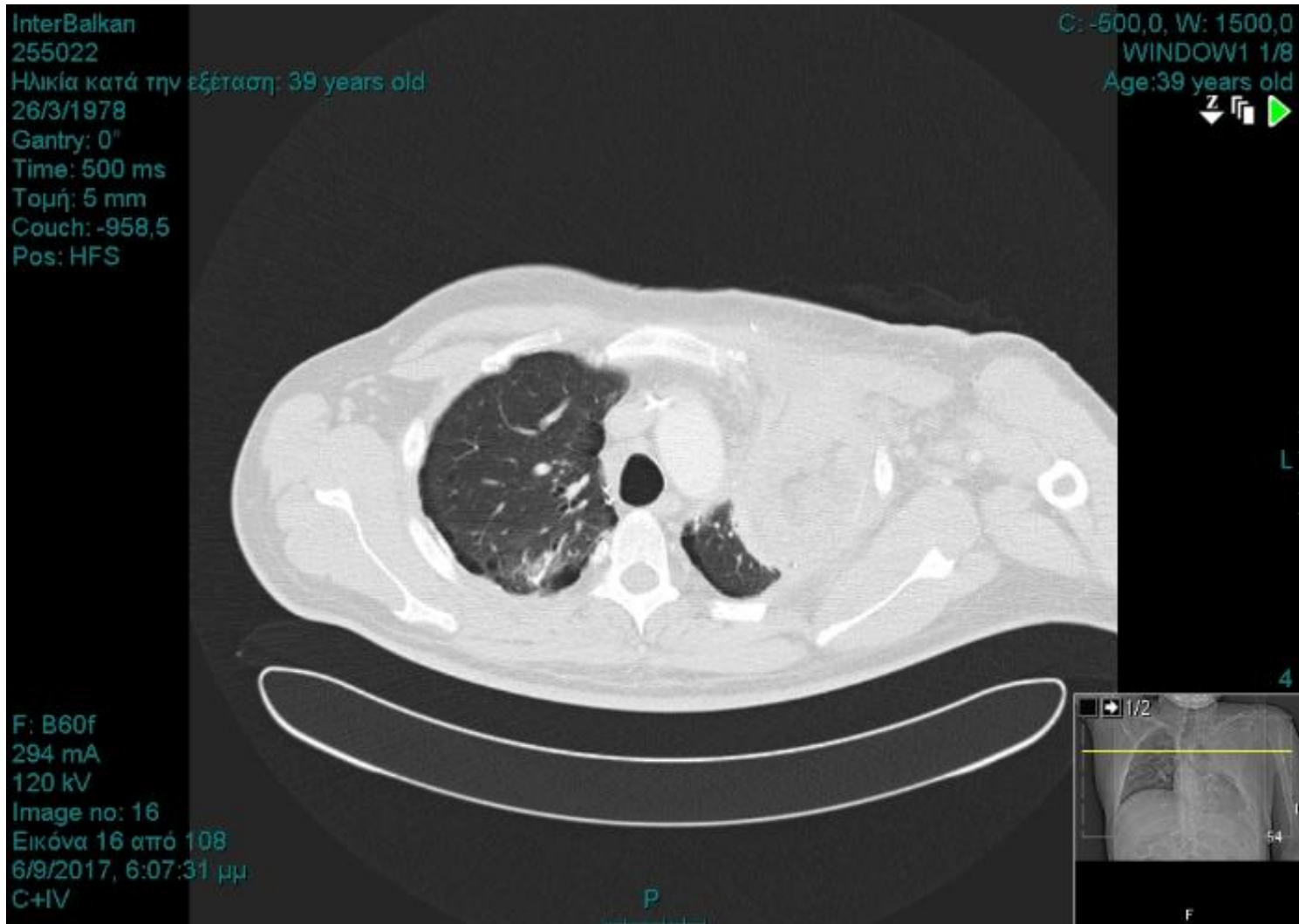
(96th postOp) Chest CT Scan

Case 1



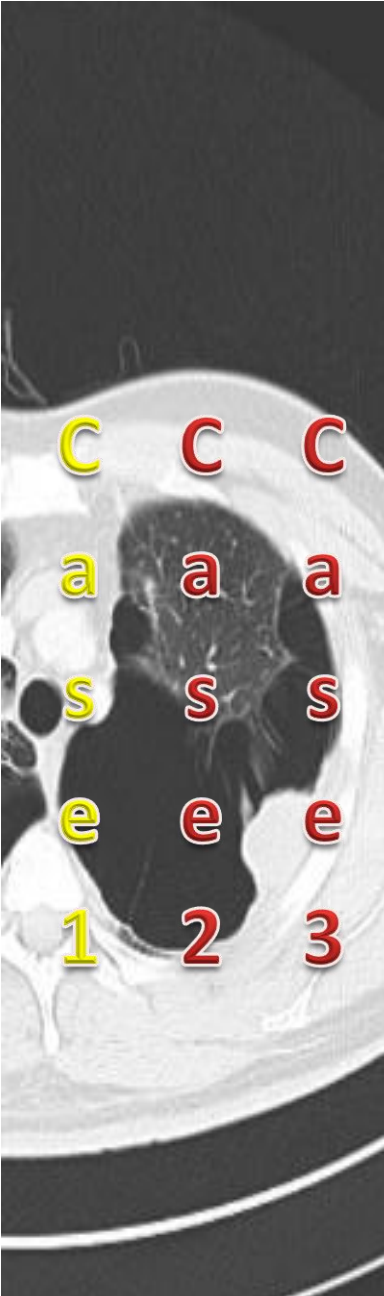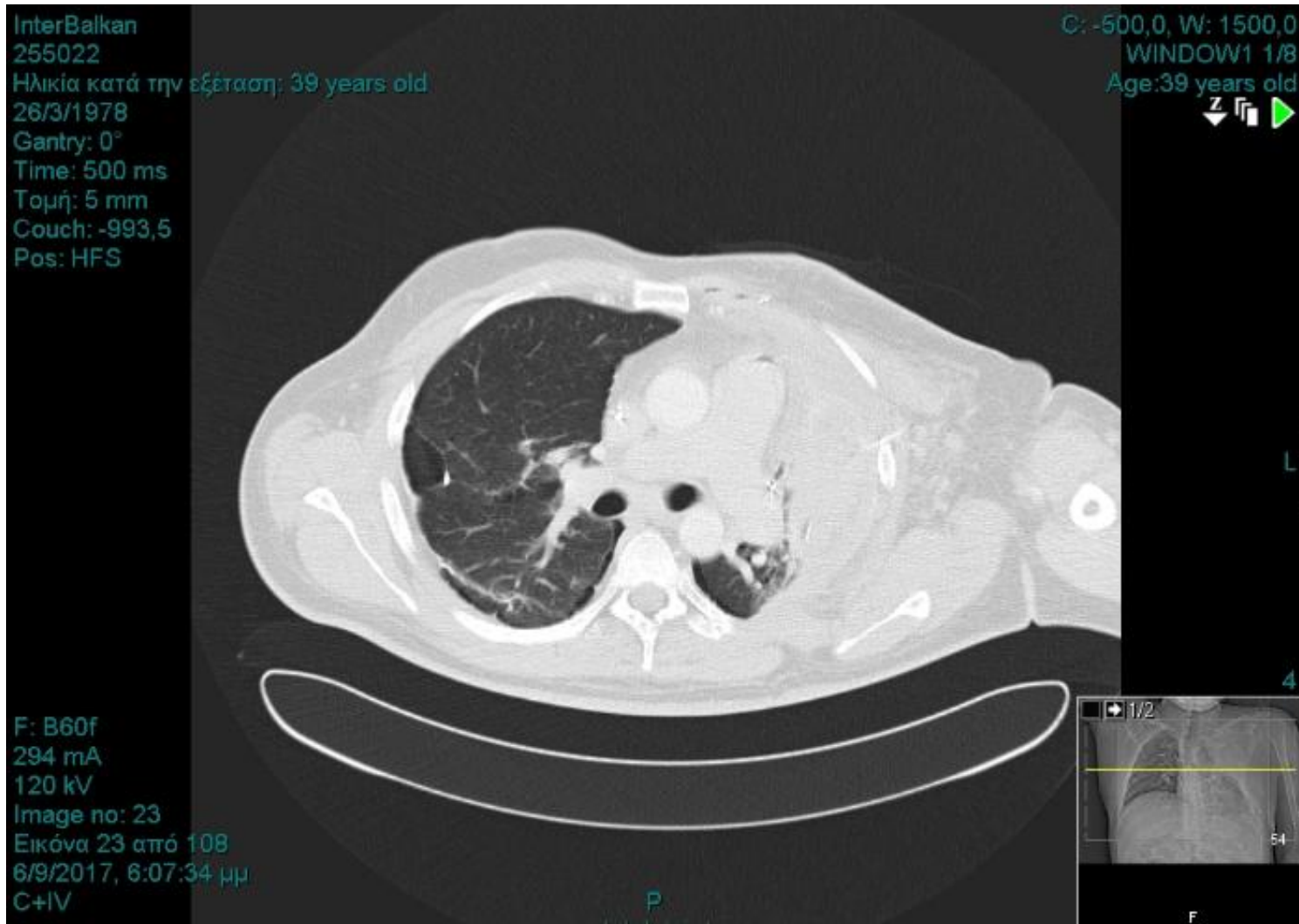
(96th postOp) Chest CT Scan

Case 1



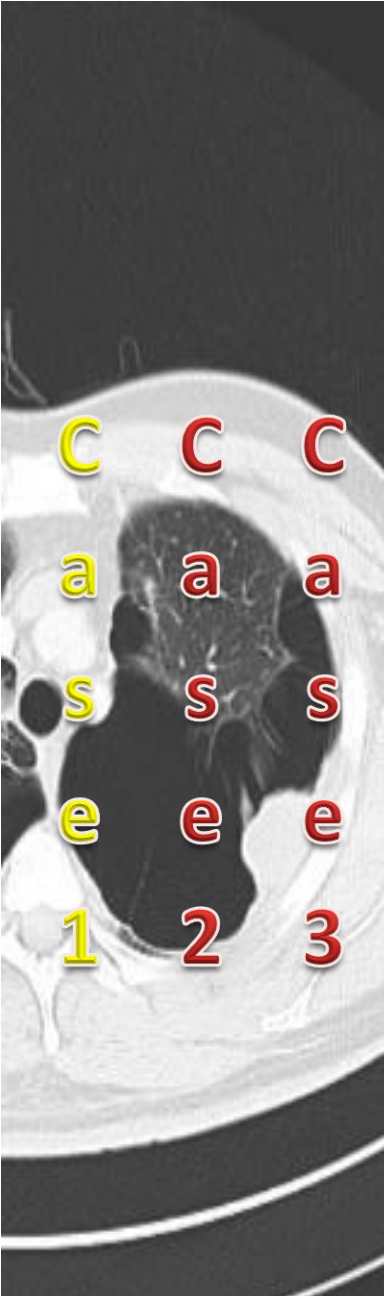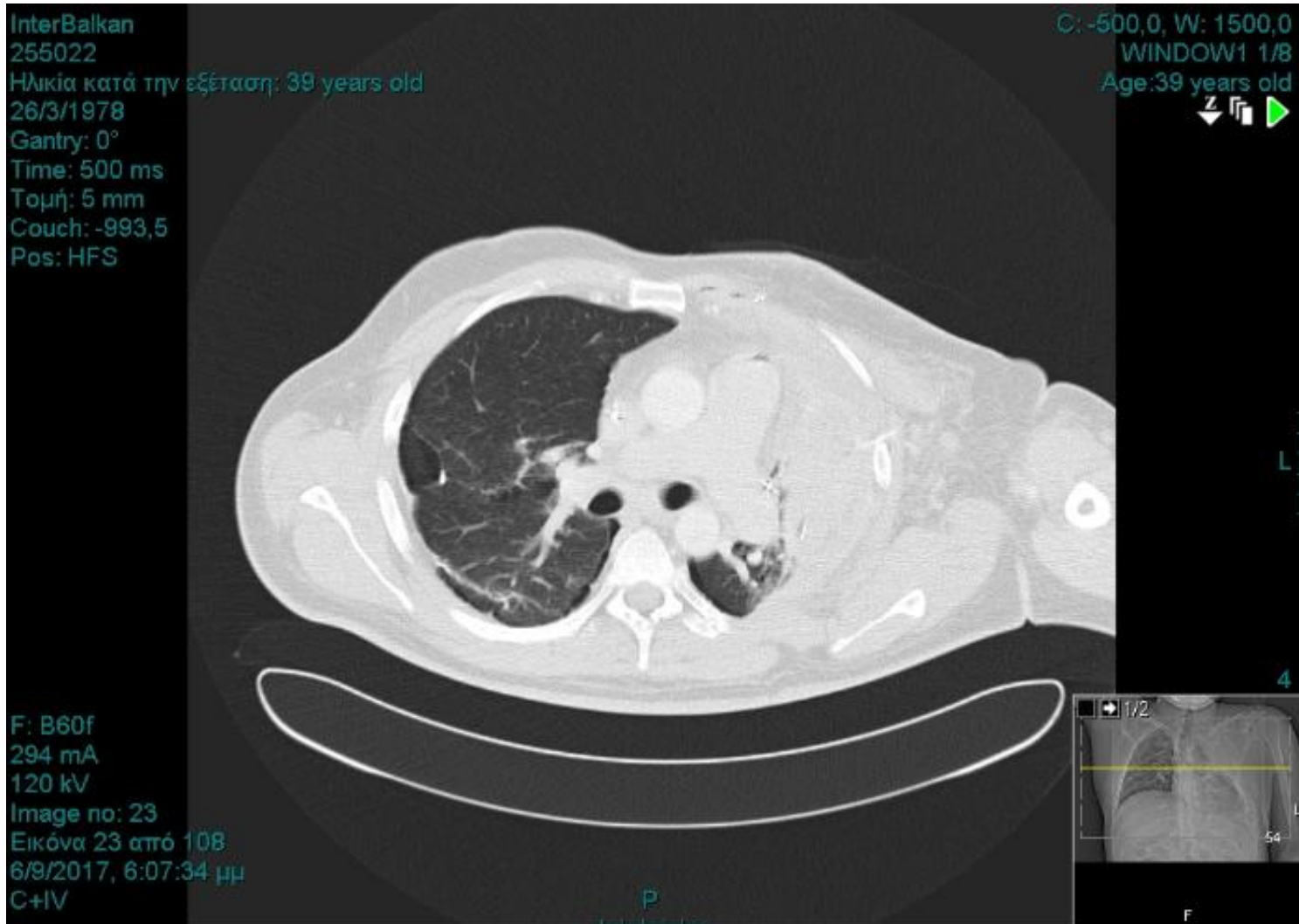
(96th postOp) Chest CT Scan

Case 1



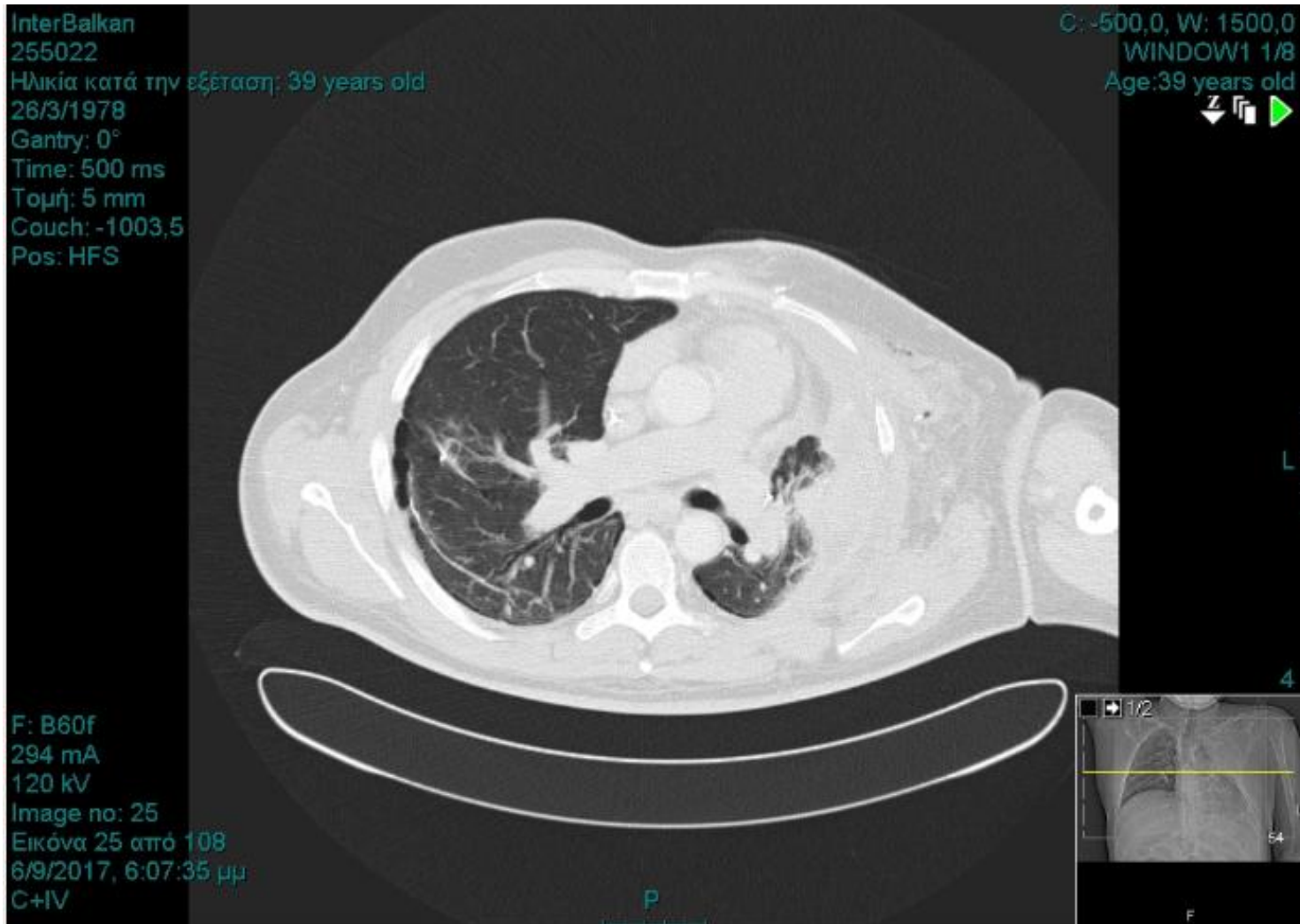
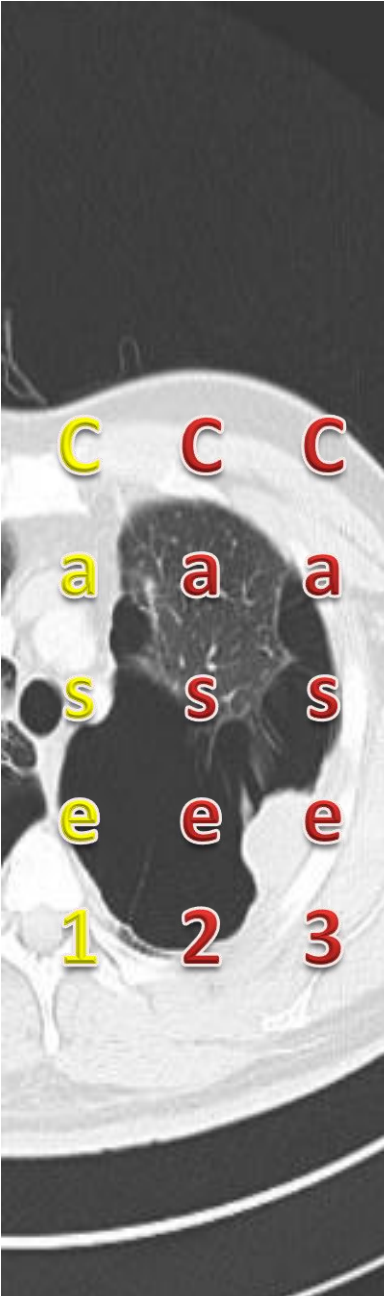
(96th postOp) Chest CT Scan

Case 1



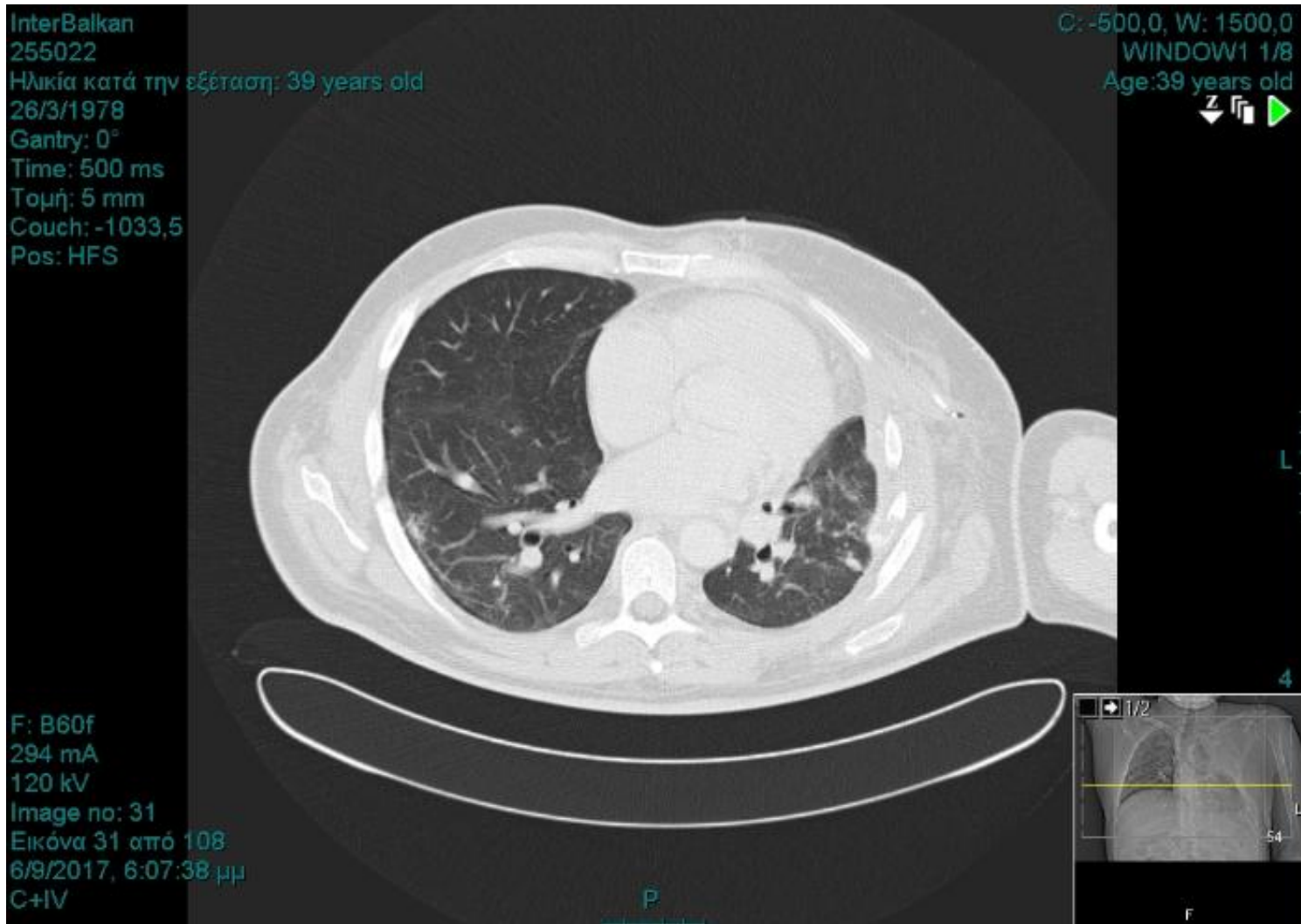
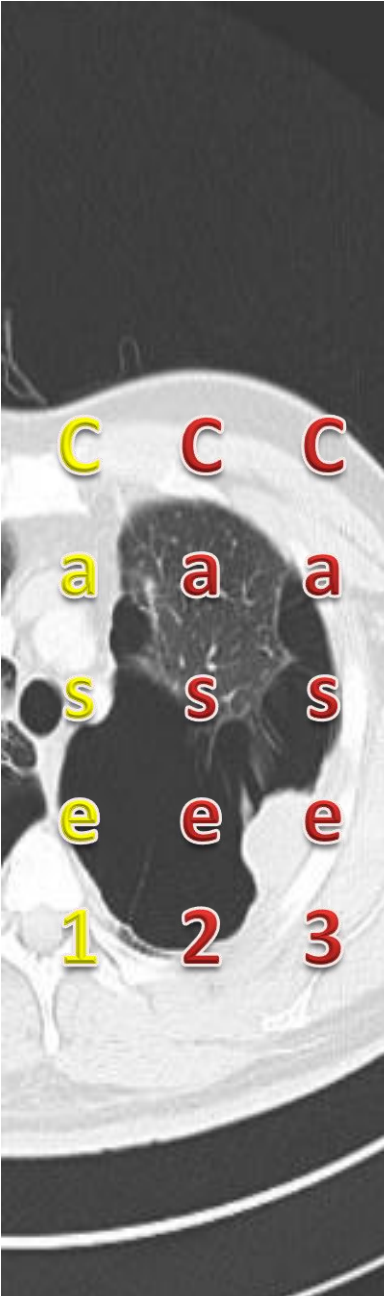
(96th postOp) Chest CT Scan

Case 1



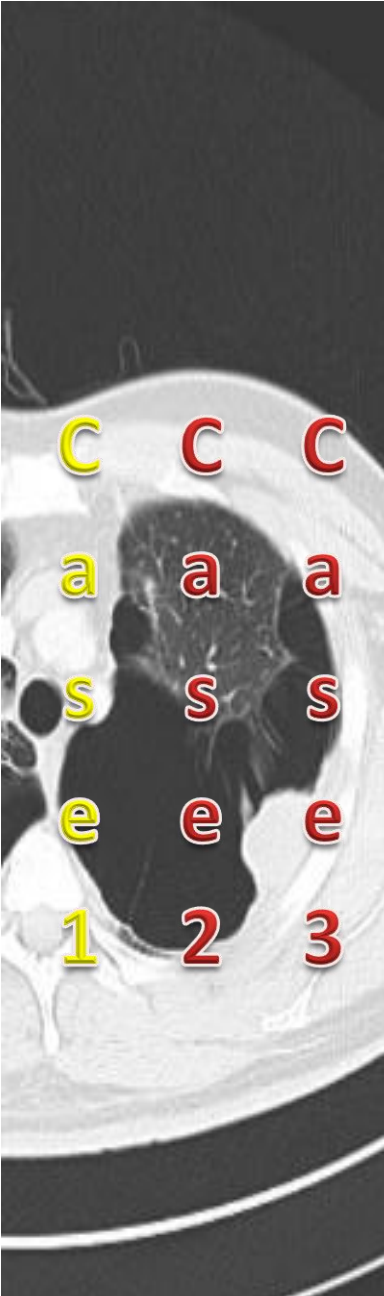
(96th postOp) Chest CT Scan

Case 1



(96th postOp) Chest CT Scan

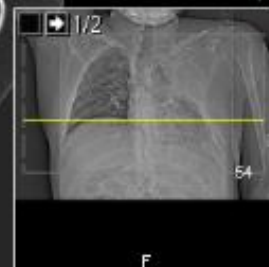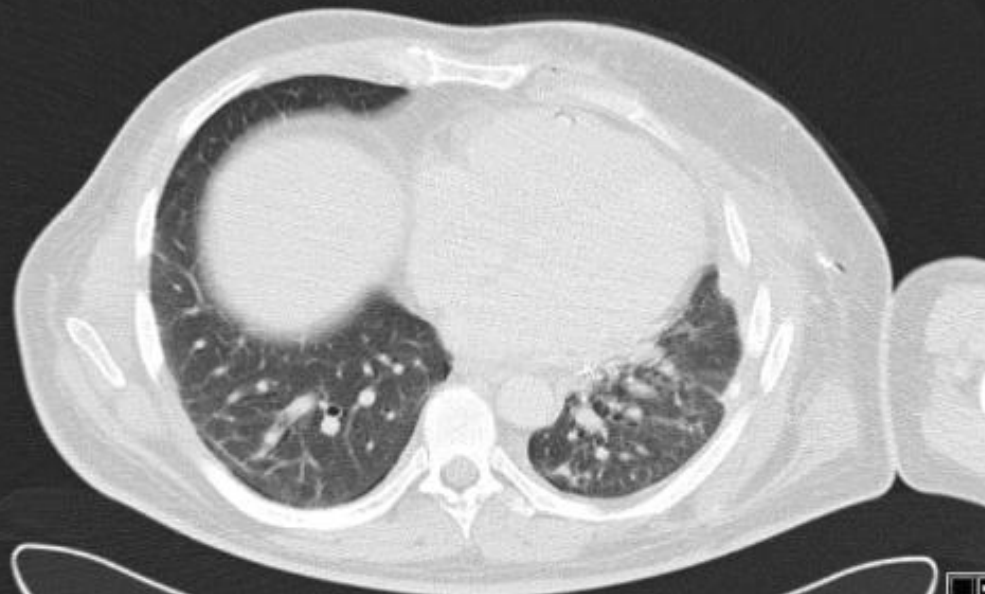Case 1



InterBalkan
255022
Ηλικία κατά την εξέταση: 39 years old
26/3/1978
Gantry: 0°
Time: 500 ms
Τομή: 5 mm
Couch: -1048,5
Pos: HFS

C: -500,0, W: 1500,0
WINDOW1 1/8
Age: 39 years old

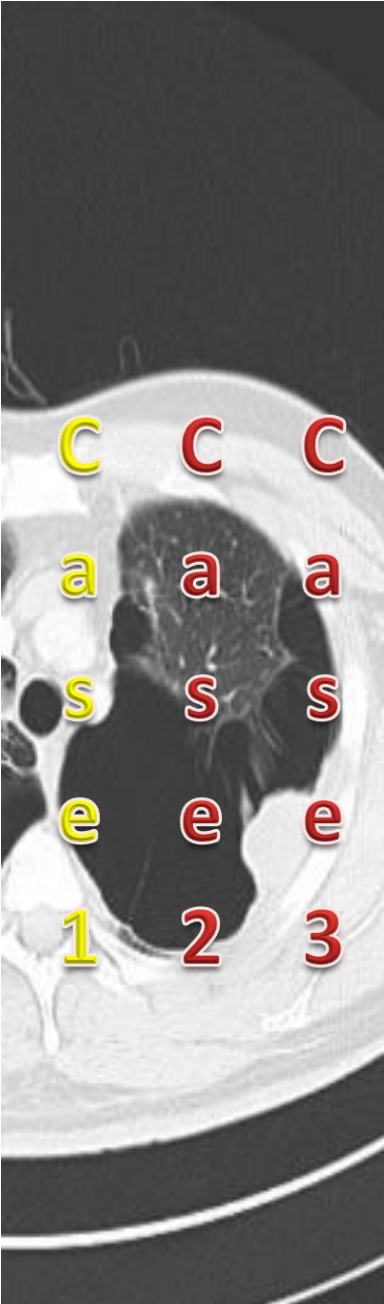
F: B60f
294 mA
120 kV
Image no: 34
Εικόνα 34 από 108
6/9/2017, 6:07:39 μμ
C+IV



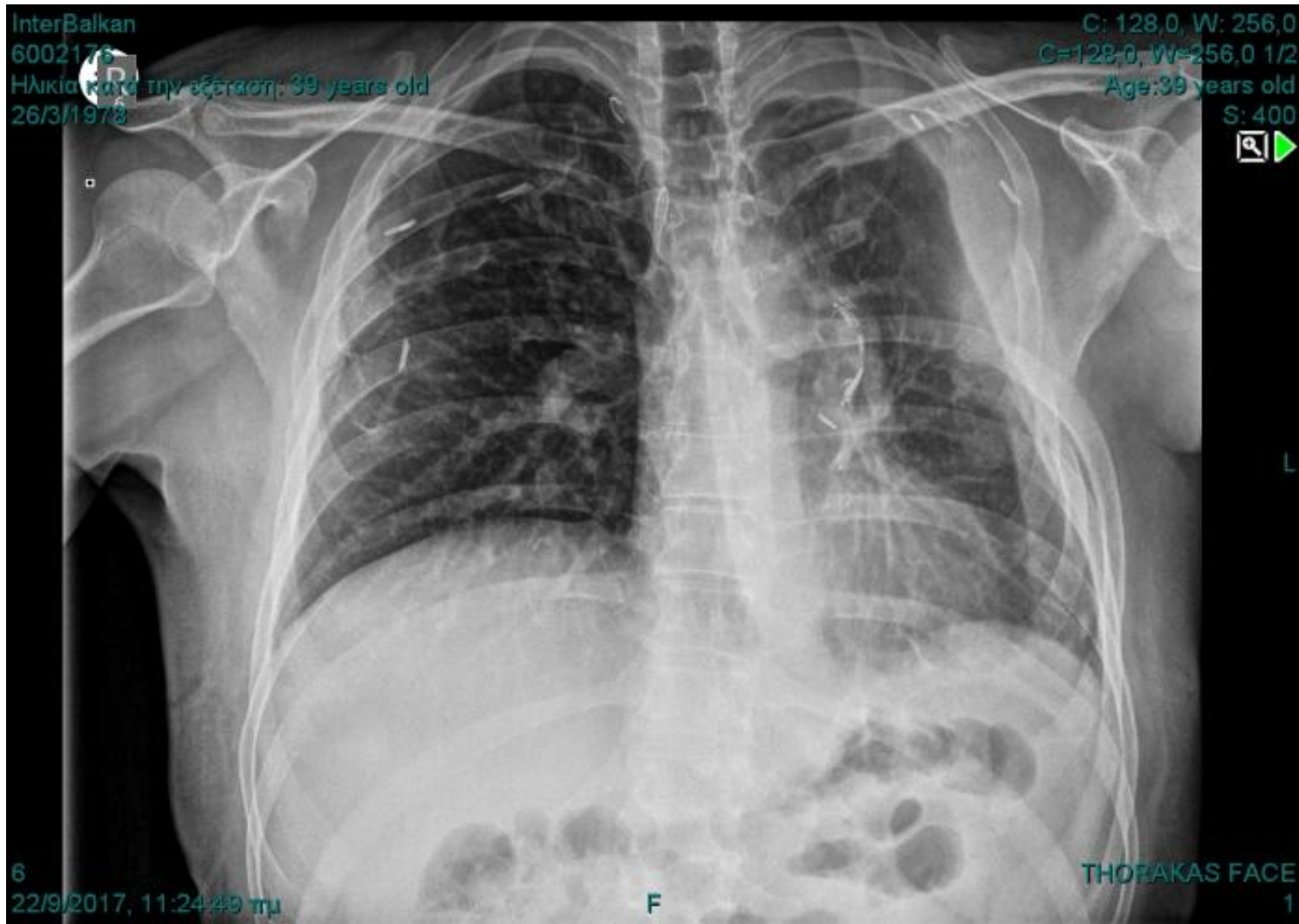
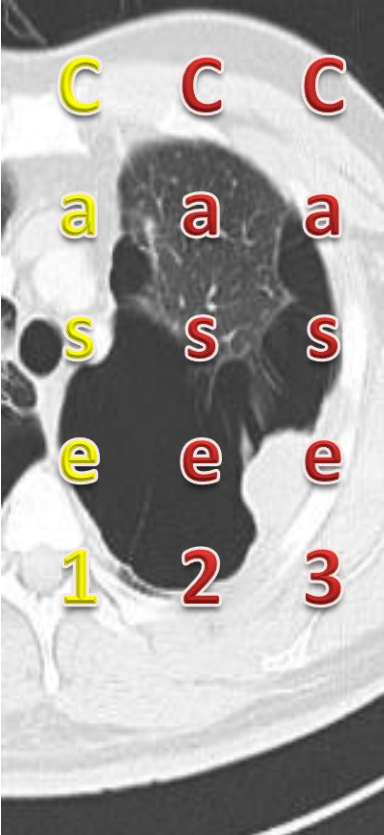(96th postOp) Chest CT Scan

Case 1

**Discharge
(101st postOp)**

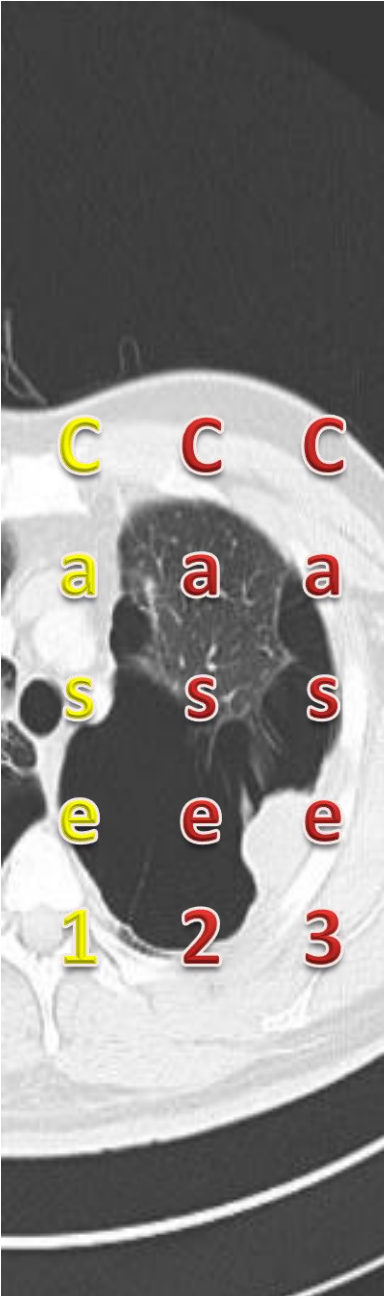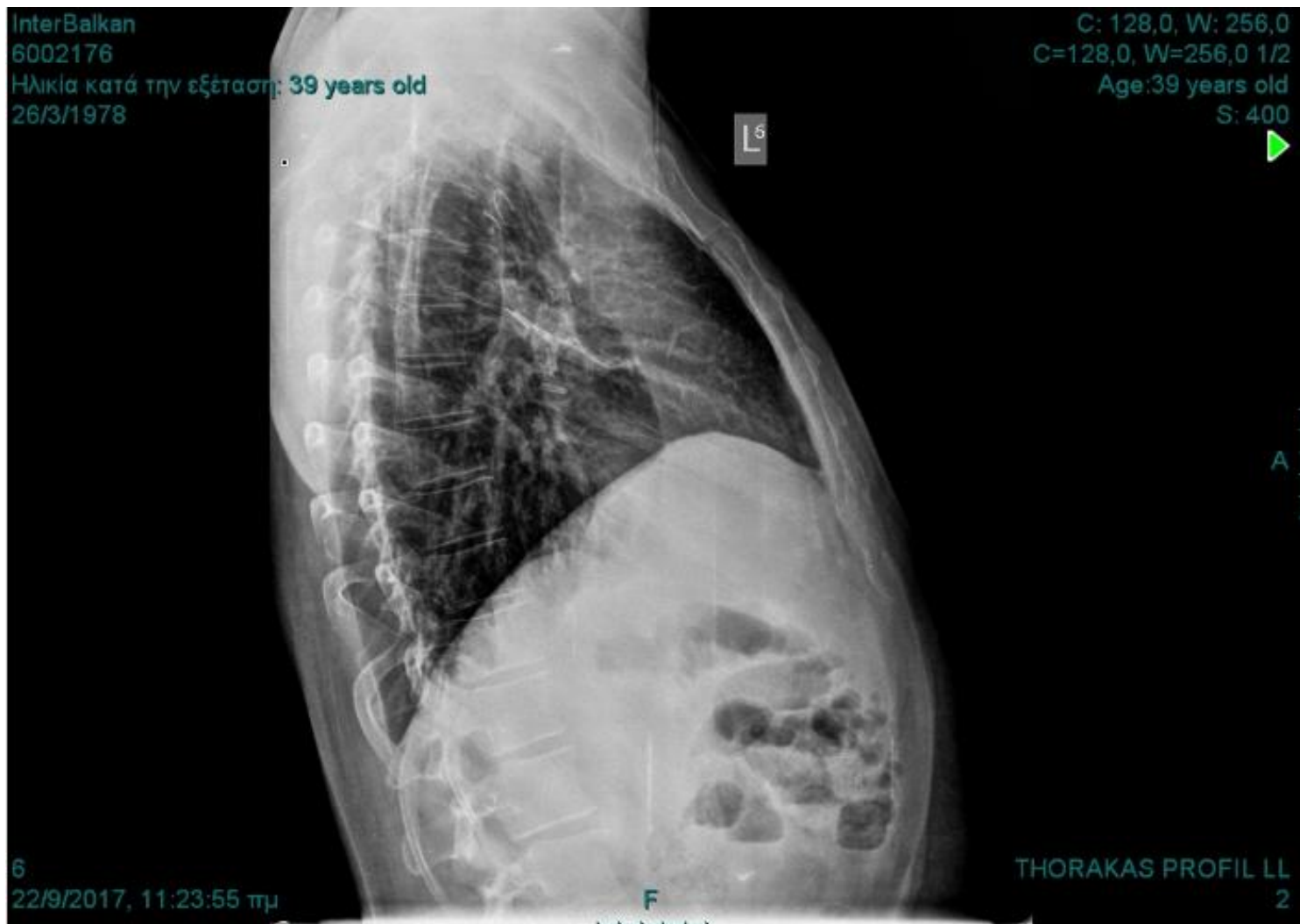


Case 1



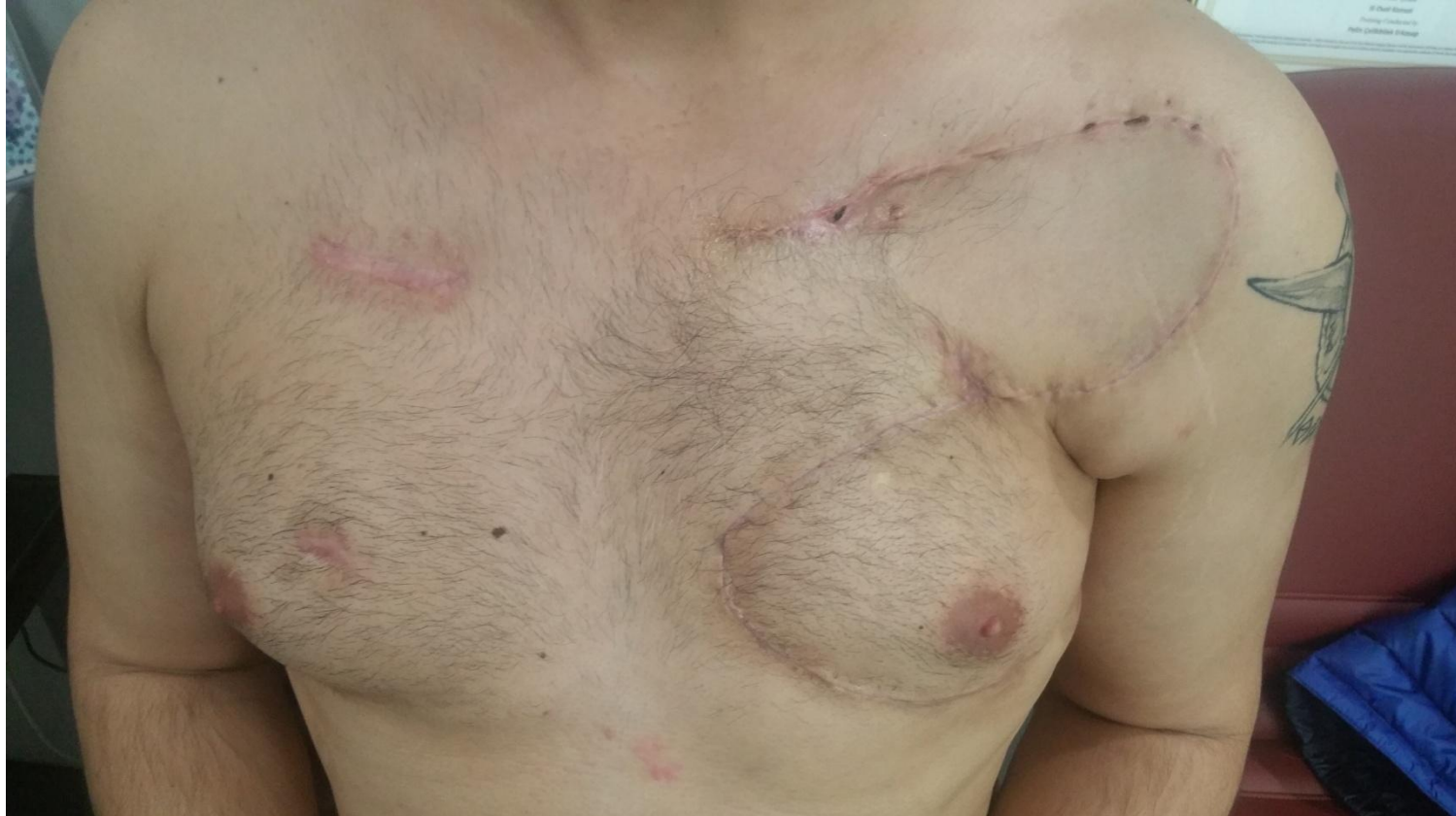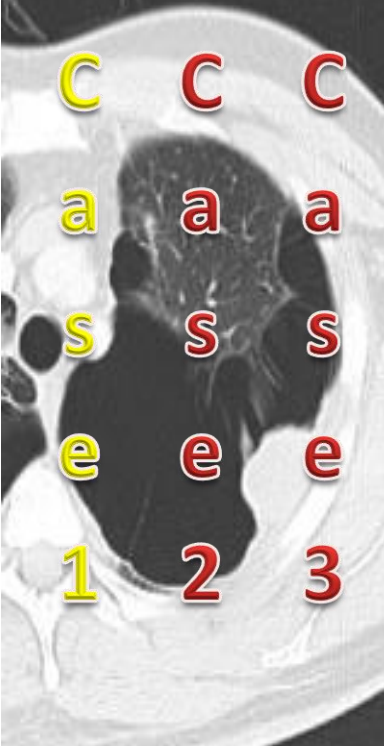(112th postOp) Chest x-ray

Case 1



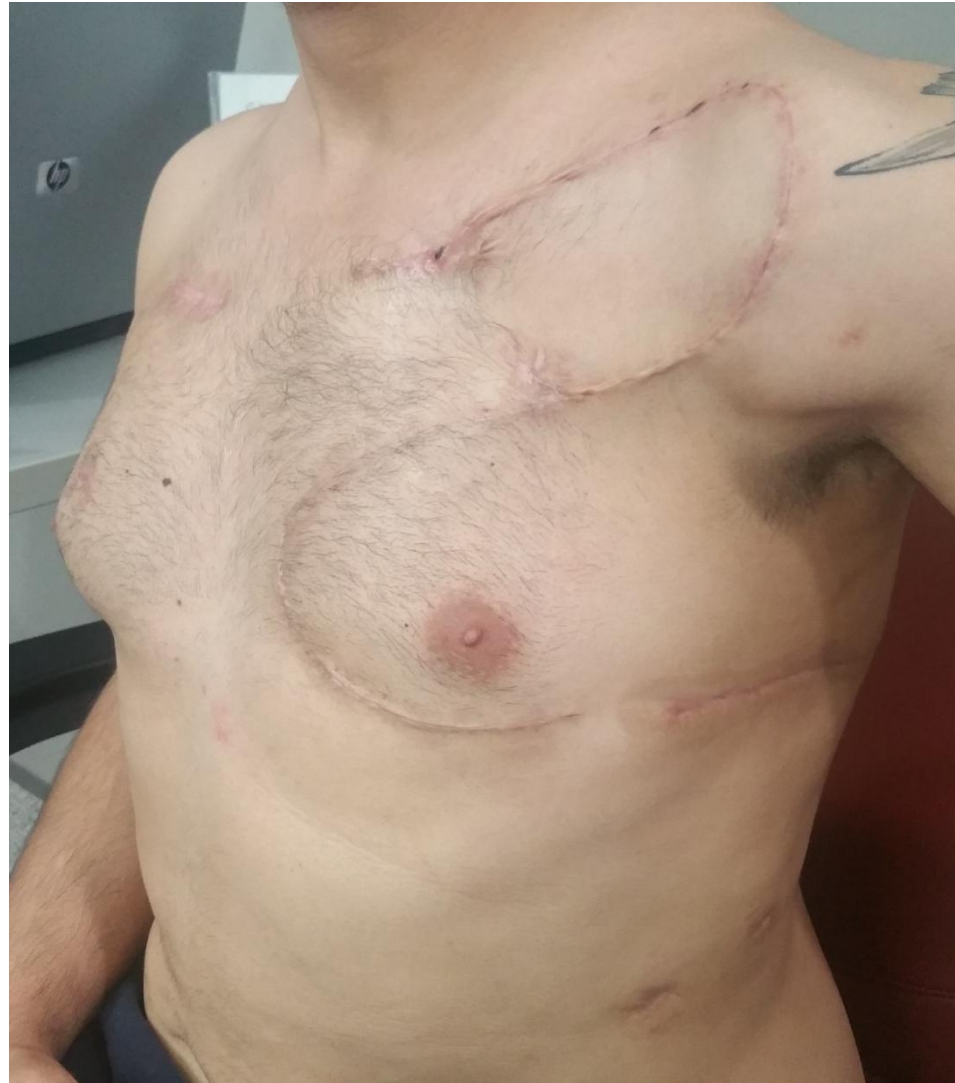(112th postOp) Chest x-ray

Case 1



(112th postOp)

Case 1



(112th postOp)

Case 1

PDL 1: 95%
What next?

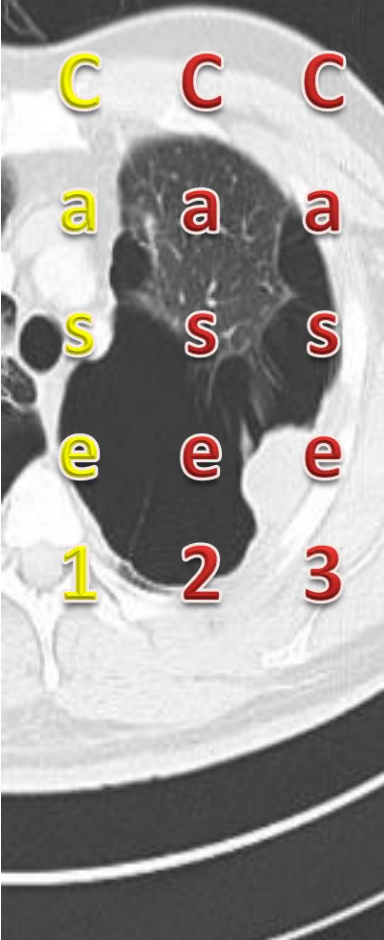- 1. Chemotherapy**
- 2. Radiotherapy**
- 3. Immunotherapy**
- 4. Watch & See**



Case 1

Multidisciplinary Team

Thoracic Surgeon
Oncologist
Plastic Surgeon
Anesthesiologist
Internist
Pulmonologist
Pathologist



Thank U for your attention!



Case 2

Male 72 y

Chief Complain:

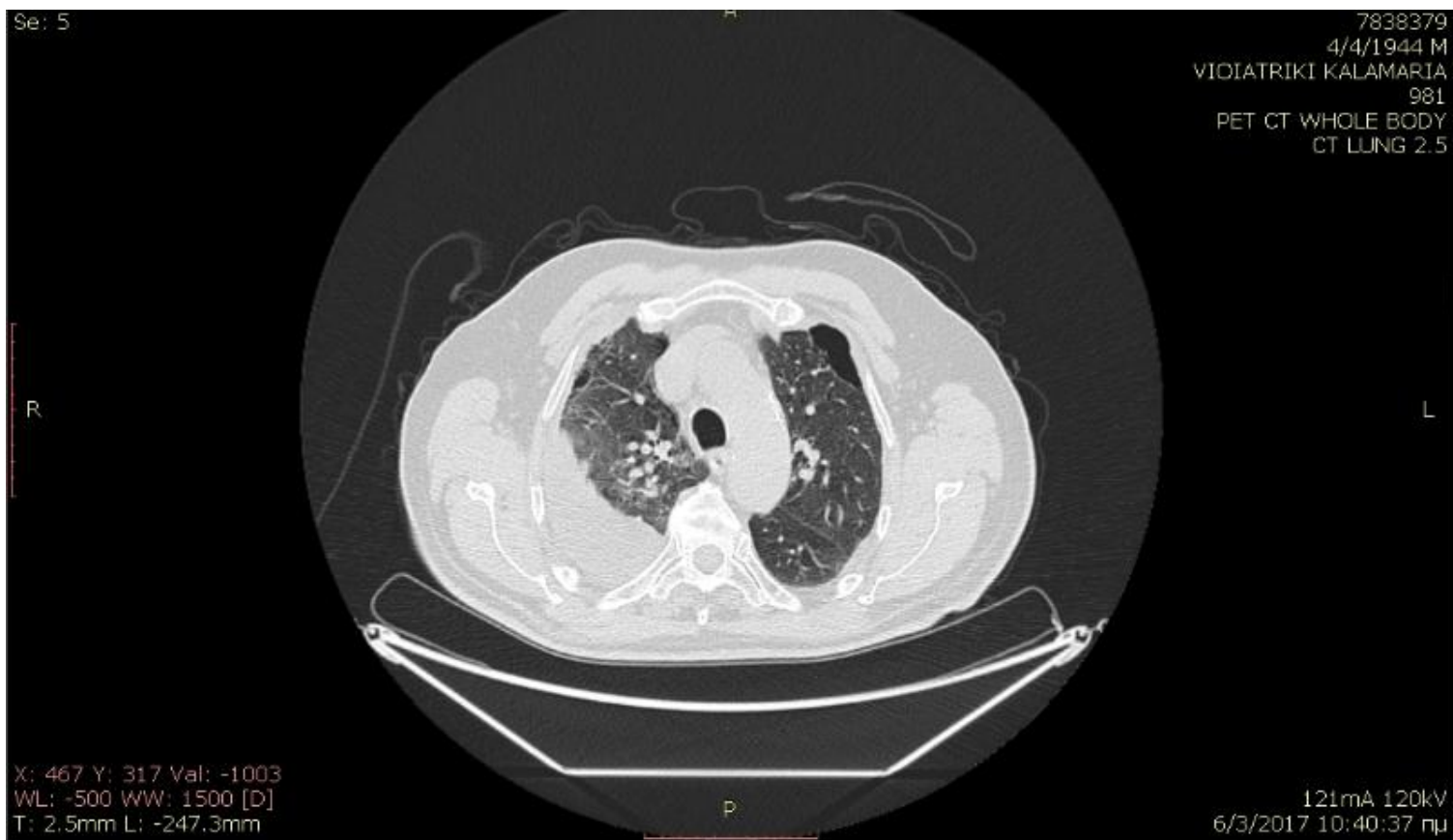
- Dyspnea
- Unspecified pain at right hemithorax
- Tumor at RLL
- Pleuritis (R)

Personal Medical History:

- PCI X 2 (2011)
- Nephrolithiasis
- Saphenectomy (R)

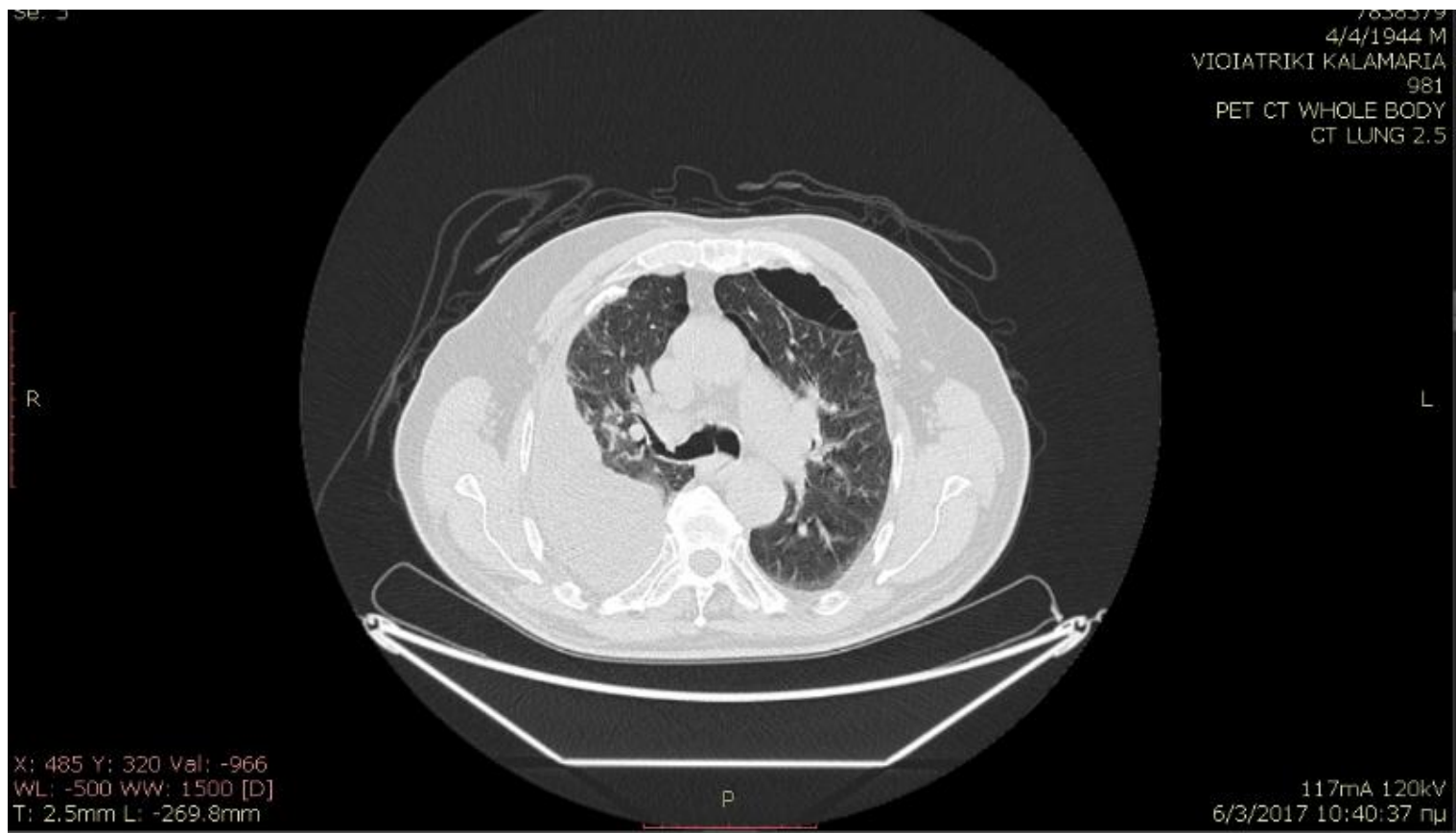
C C C
a a a
s s s
e e e
1 2 3

Case 2



PreOp Chest CT Scan

Case 2

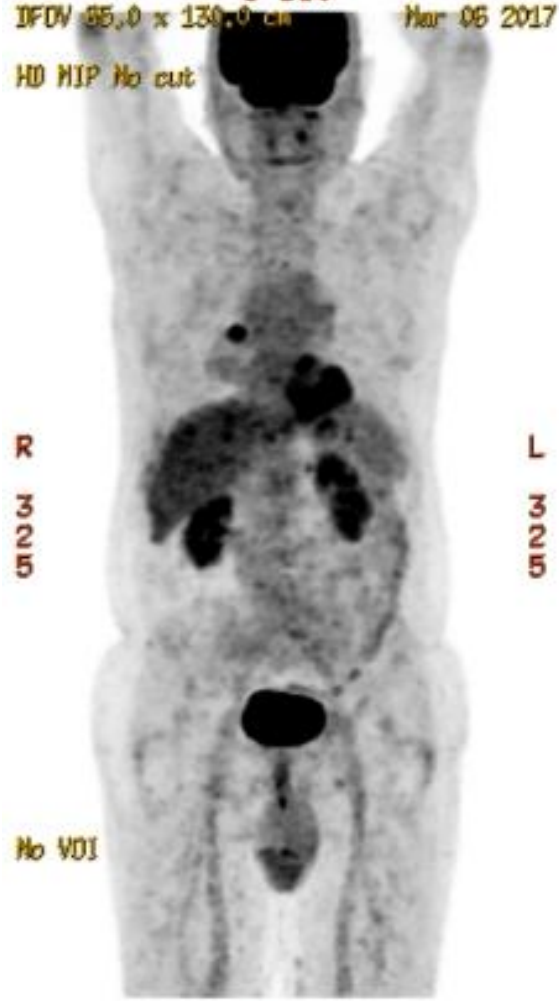


PreOp Chest CT Scan

Case 2

S 160
IFDV 05.0 x 130.0 cm Mar 06 2017


HD MIP No cut



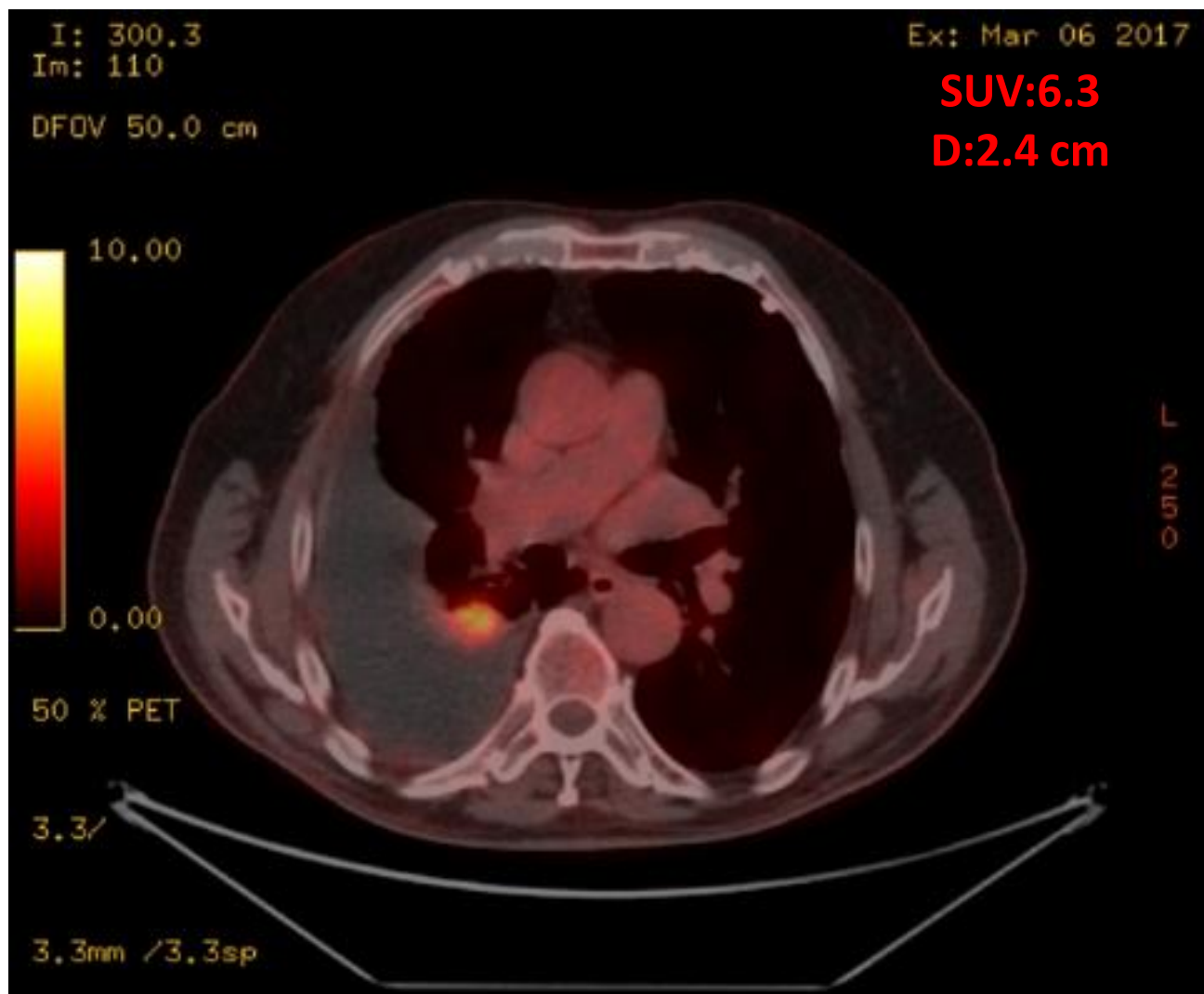
No VOI

$\mu=0.00$ $\sigma=3.70$ $g/41$ 1140 -999999.000000


PreOp PET-CT Scan



Case 2



PreOp PET-CT Scan



Case 2

ΥΛΙΚΟ : Υγρό υπεζωκοτικής κοιλότητας

ΚΛΙΝΙΚΕΣ ΠΛΗΡΟΦΟΡΙΕΣ : Δεξιά ετερόπλευρη υπεζωκοτική συλλογή (εξίδρωμα), χωρίς υποκείμενη υπεζωκοτική βλάβη. Αξονική κοιλίας και εγκεφάλου χωρίς ευρήματα.

ΚΥΤΤΑΡΟΛΟΓΙΚΑ ΕΥΡΗΜΑΤΑ

Η κυτταρολογική κατά Παπανικολάου εξέταση του υλικού που παραλάβαμε κατόπιν επεξεργασίας με την τεχνική Thin Prep, έδειξε λίγα μεσοθηλιακής προέλευσης κύτταρα με ήπιου βαθμού αντιδραστικού και εκφυλιστικού τύπου αλλοιώσεις. Μεταξύ αυτών ωστόσο παρατηρούνται και λίγες ομάδες επιθηλιακών κυττάρων, μέσου - μικρού μεγέθους που προσλαμβάνουν ύποπτους για κακοήθεια νεοπλασματικούς χαρακτήρες (πυρηνική υπερχρωμασία, διαταραχή πυρηνοπλασματικής αναλογίας). Στο υπόστρωμα αναγνωρίζονται αρκετά φλεγμονώδη κυτταρικά στοιχεία, κυρίως λεμφοκύτταρα.

ΑΝΟΣΟΚΥΤΤΑΡΟΧΗΜΕΙΑ : Κατά την ανοσοκυτταροχημική διερεύνηση του υλικού τα ως άνω κύτταρα εμφανίζουν θετικότητα στον δείκτη Ber-EP4 και στον παράγοντα TTF-1 και απουσία έκφρασης στην Calretinin και CK5/6.

ΣΥΜΠΕΡΑΣΜΑ : Κυτταρομορφολογικά και κυρίως ανοσοκυτταροχημικά ευρήματα περισσότερο συμβατά με την παρουσία αδενοκαρκινώματος με πρωτοπαθή εστία τον πνεύμονα.

C C C
a a a
s s s
e e e
1 2 3

Thoracentesis

Case 2

Treatment management

1. VATS pleural fluid drainage and pleura and lung biopsy
2. Medical thoracoscopy fluid drainage and pleura biopsy
3. Pleural fluid drainage and CT-guided biopsy
4. Pleurodesis
5. Chemotherapy

C C C
a a a
s s s
e e e
1 2 3

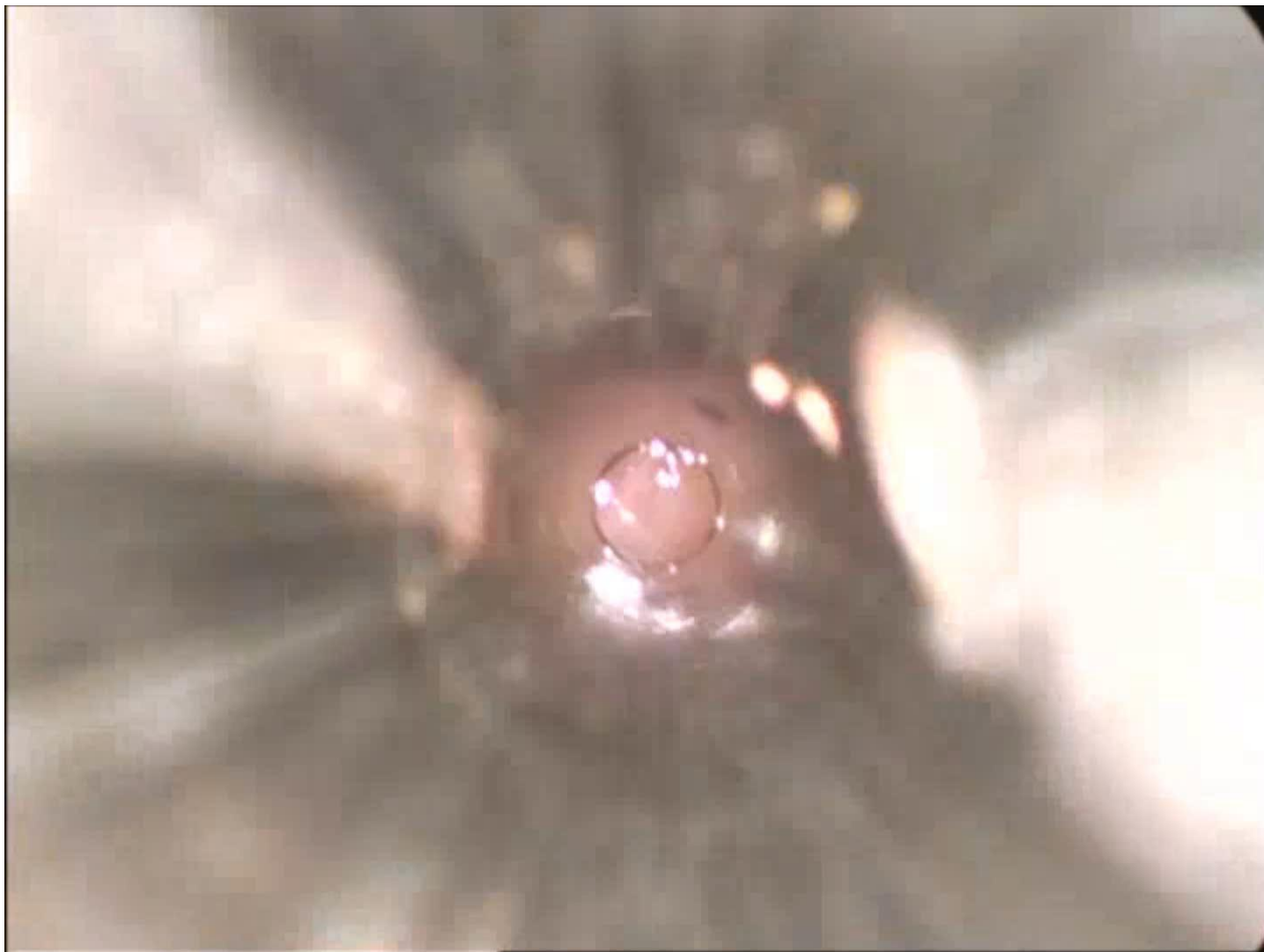Case 2

Treatment management

1. VATS pleural fluid drainage and pleura and lung biopsy
2. **Medical thoracoscopy fluid drainage and pleura biopsy**
3. Pleural fluid drainage and CT-guided biopsy
4. **Pleurodesis**
5. Chemotherapy

C C C
a a a
s s s
e e e
1 2 3

Case 2



Surgical field

C C C
a a a
s s s
e e e
1 2 3

Case 2

Treatment management

1. Chemotherapy
2. RLL Lobectomy
3. RLL Segmentectomy
4. Hyperthermic Intrathoracic Chemo Perfusion (HITHOC)

C C C
a a a
s s s
e e e
1 2 3

Case 2

Treatment management

1. **Chemotherapy**
2. RLL Lobectomy
3. **RLL Segmentectomy**
4. **Hyperthermic Intrathoracic Chemo Perfusion (HITHOC)**

C C C
a a a
s s s
e e e
1 2 3

Case 2

RLL (apical segmentectomy)

+

HITHOC

500mg Carboplatin

42°C

1h

C C C
a a a
s s s
e e e
1 2 3

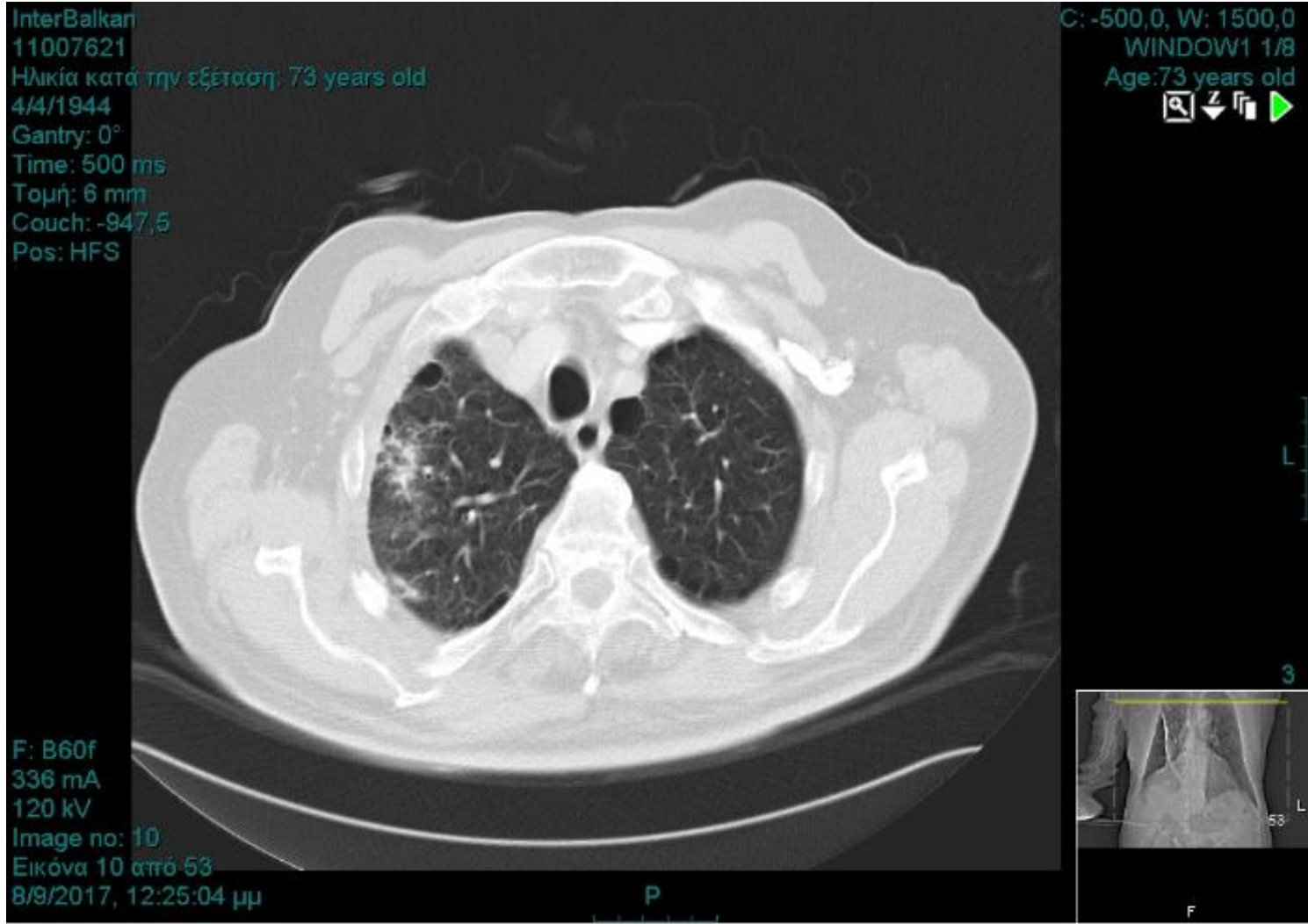
Case 2

C C C
a a a
s s s
e e e
1 2 3

Adjuvant Chemotherapy

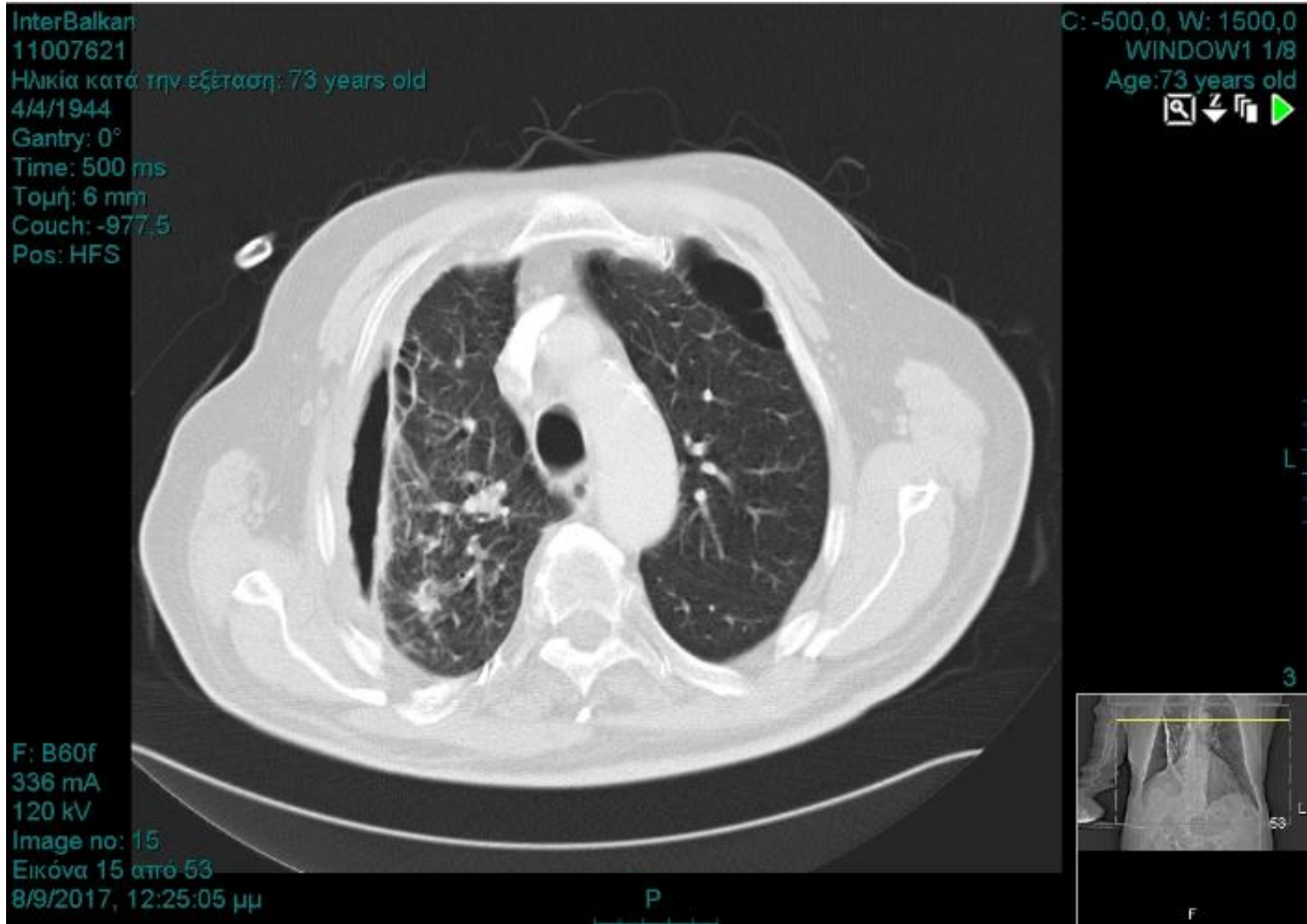
(5 cycles)
Carboplatin
Pemetrexed

Case 2




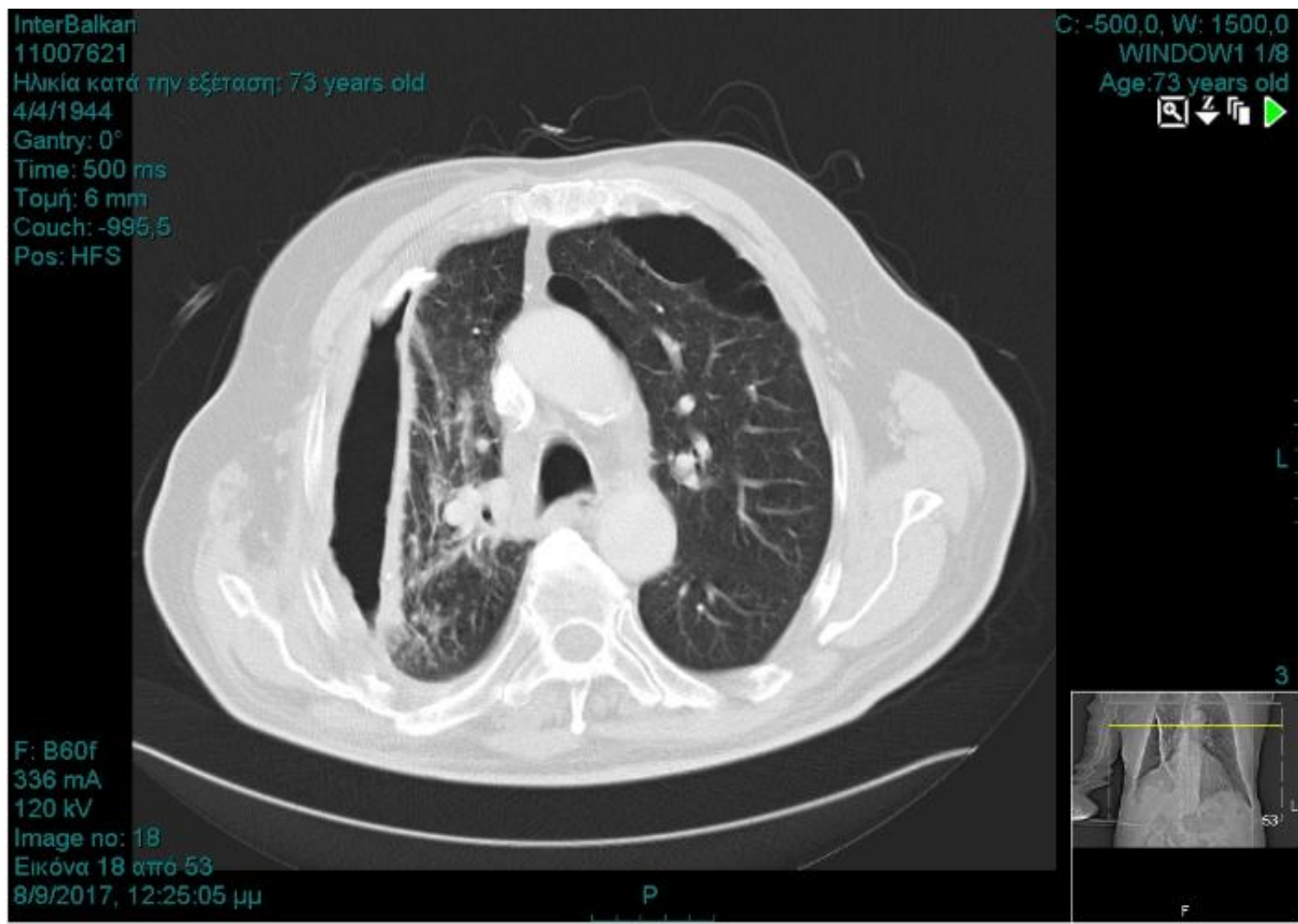
postOp (6 months) Chest CT Scan

Case 2



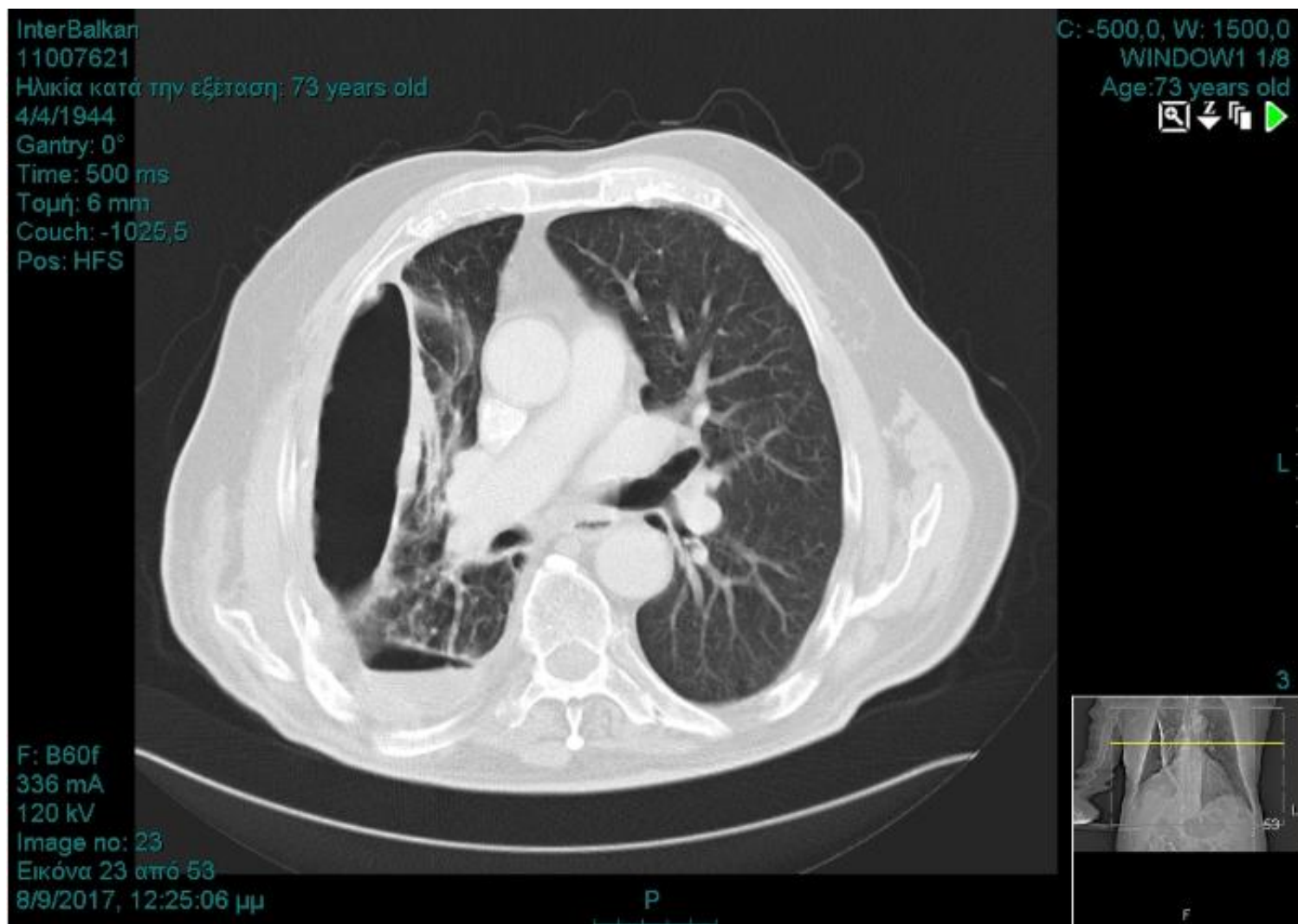
postOp (6 months) Chest CT Scan

Case 2



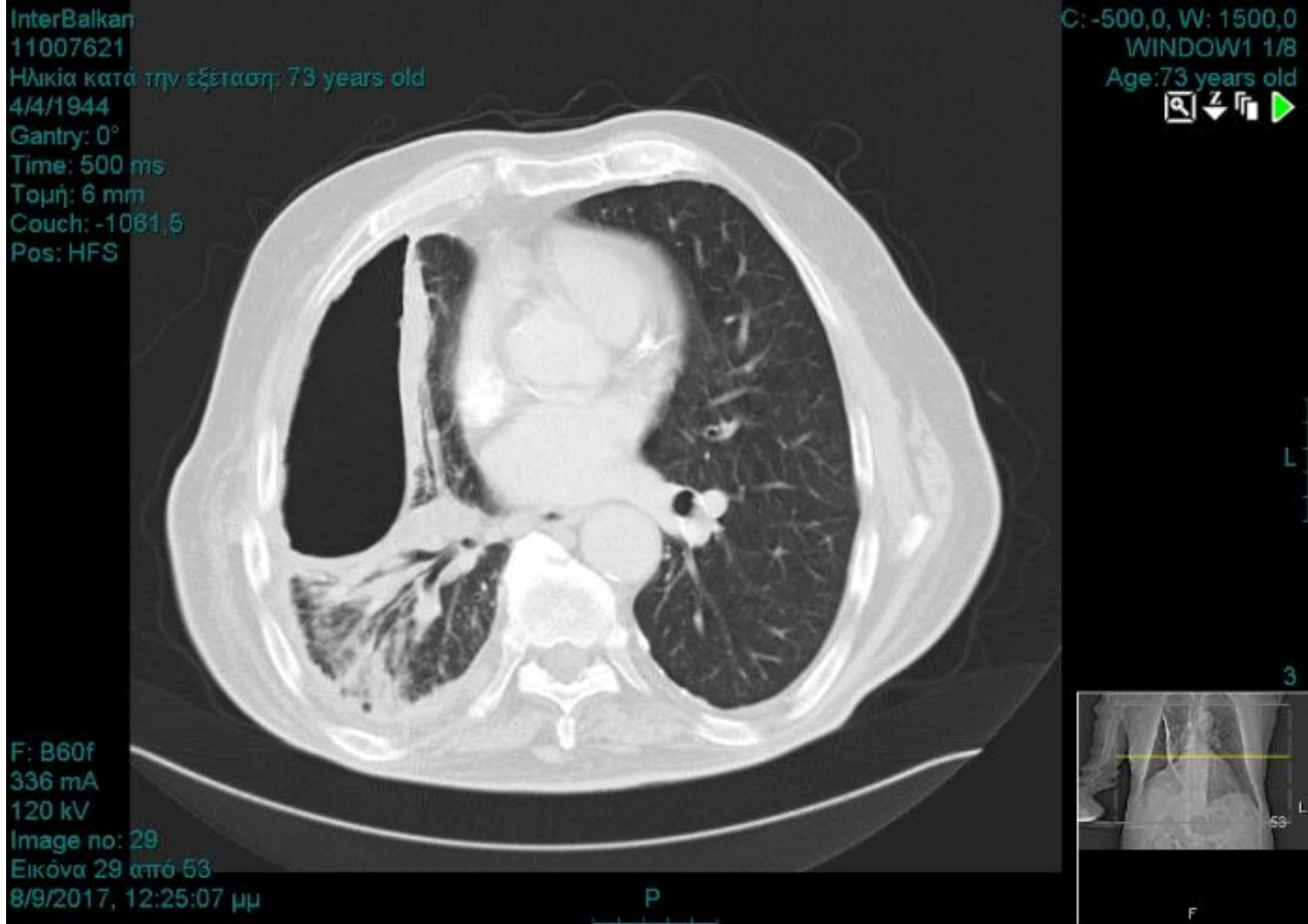postOp (6 months) Chest CT Scan

Case 2



postOp (6 months) Chest CT Scan

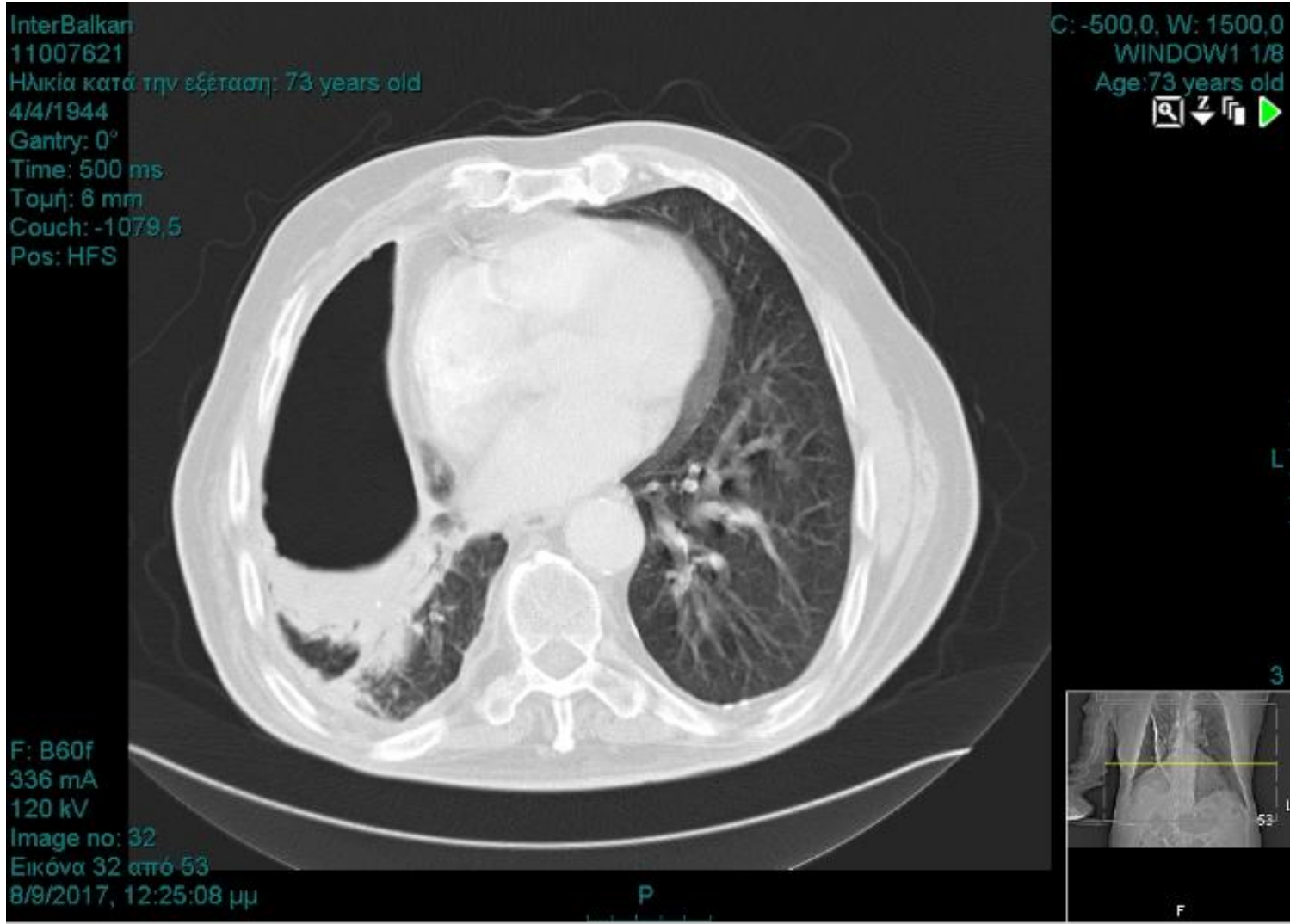
Case 2



C C C
a a a
s s s
e e e
1 2 3


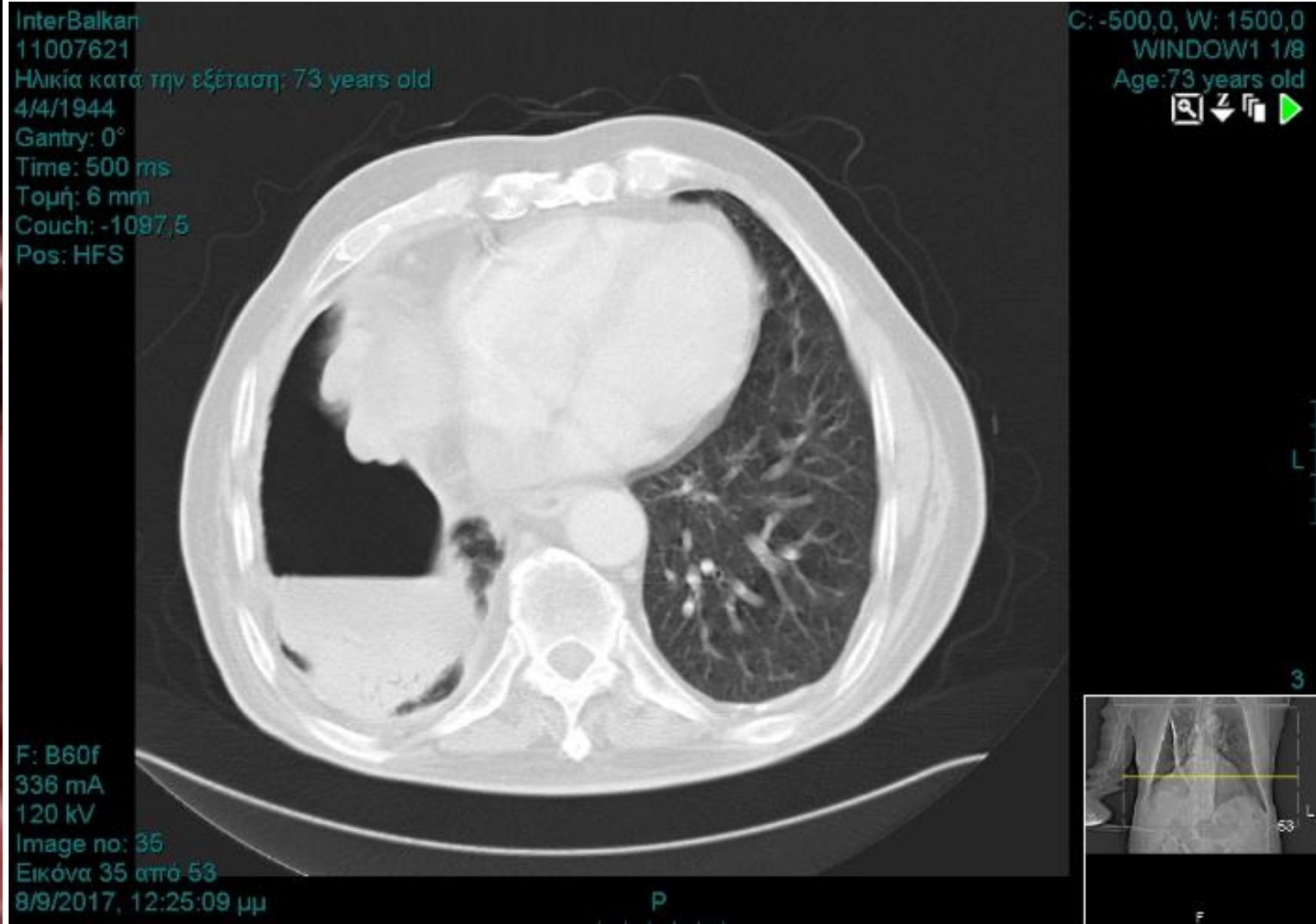
postOp (6 months) Chest CT Scan

Case 2




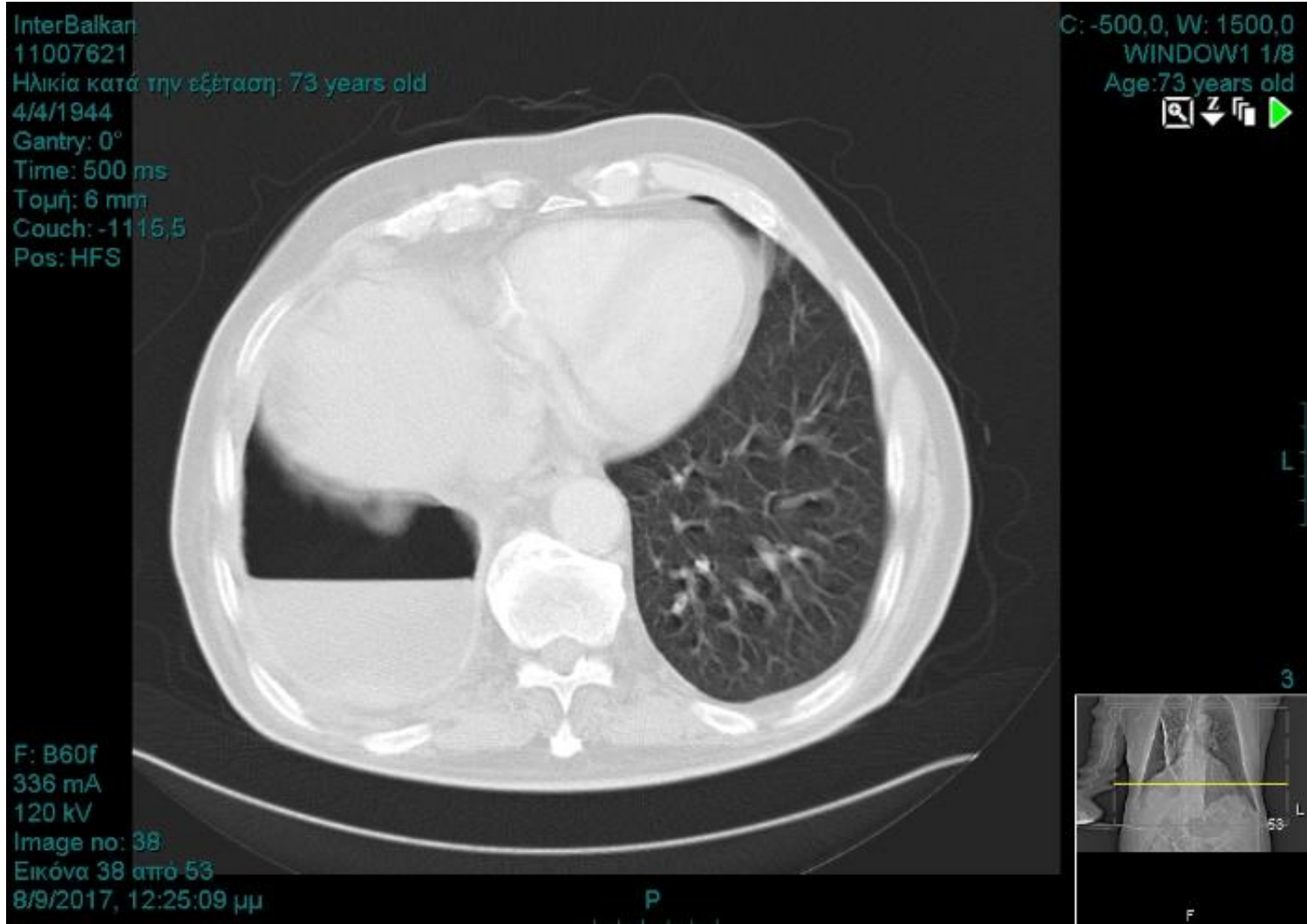
postOp (6 months) Chest CT Scan

Case 2



postOp (6 months) Chest CT Scan

Case 2



postOp (6 months) Chest CT Scan

Case 2

Air Space – Fever – Sputum - Aspergillus

1. Reoperation
2. Chest tube insertion
3. VATS exploration
4. Antibiotics
5. Voriconazole
6. Thoracoplasty
7. Thoracostomy

C C C
a a a
s s s
e e e
1 2 3

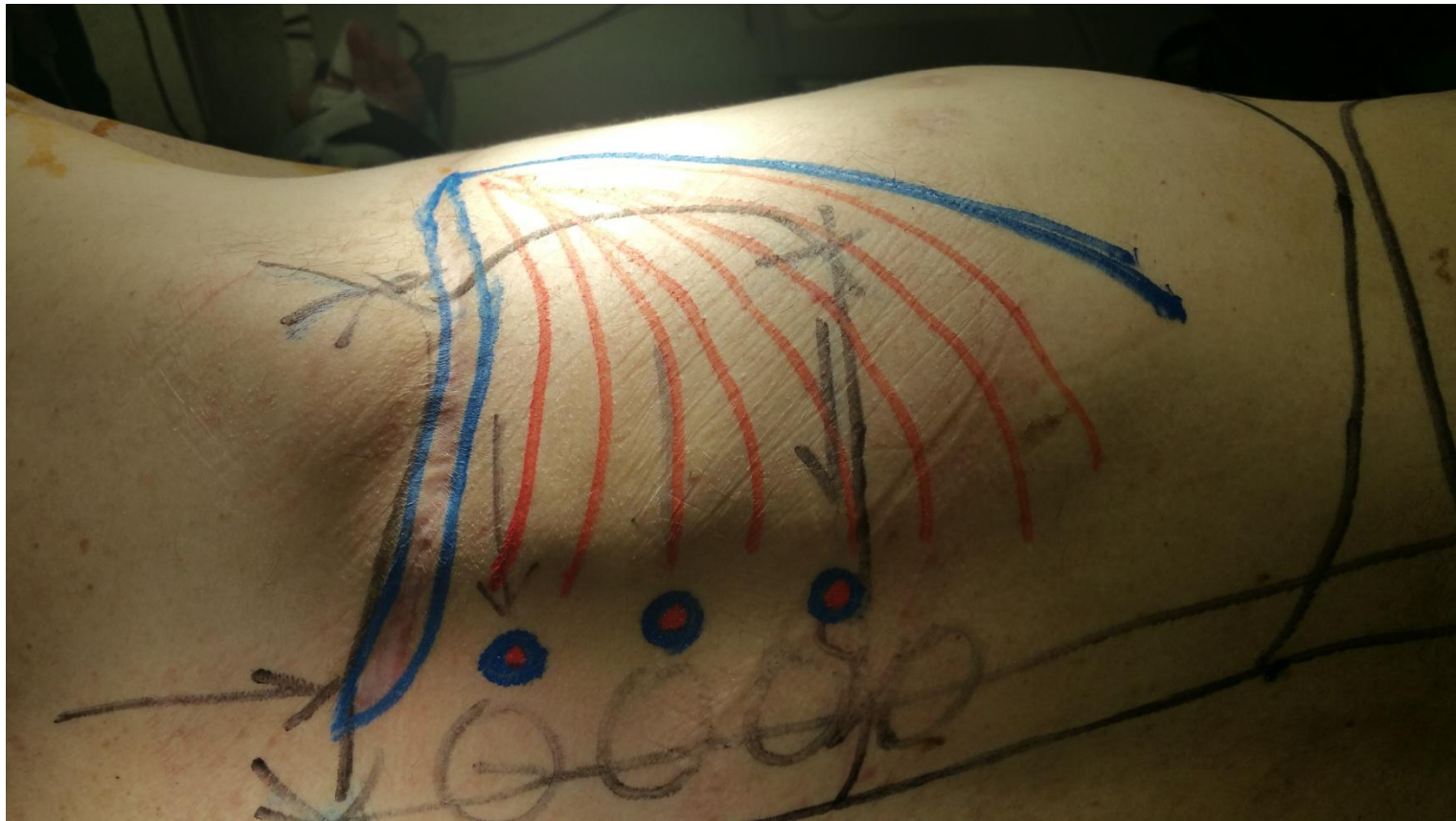
Case 2

Air Space – Fever – Sputum - Aspergillus

1. Reoperation
2. Chest tube insertion
3. **VATS exploration**
4. **Antibiotics**
5. **Voriconazole**
6. **Thoracoplasty**
7. Thoracostomy

C C C
a a a
s s s
e e e
1 2 3

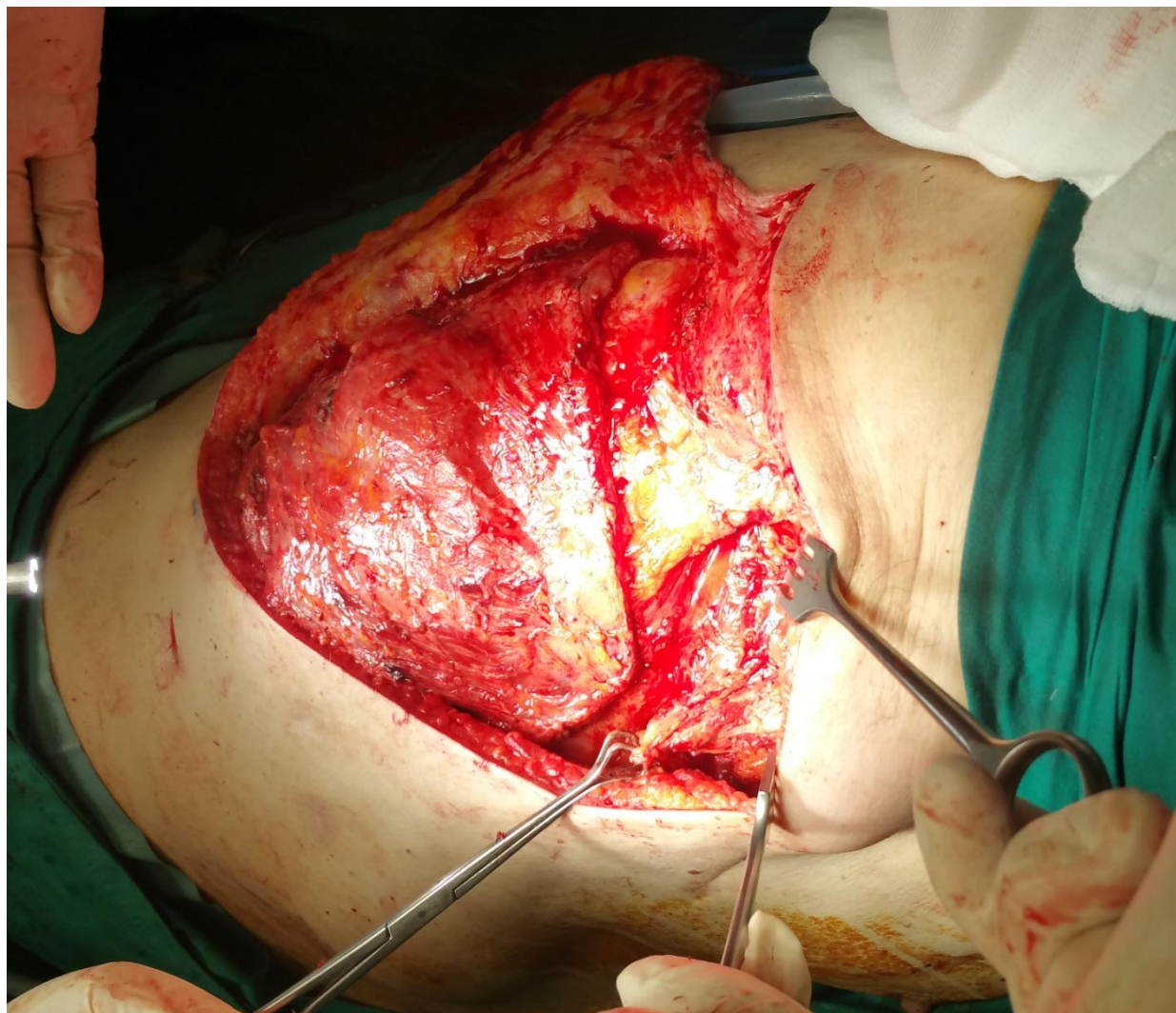Case 2



Surgical Field

C C C
a a a
s s s
e e e
1 2 3

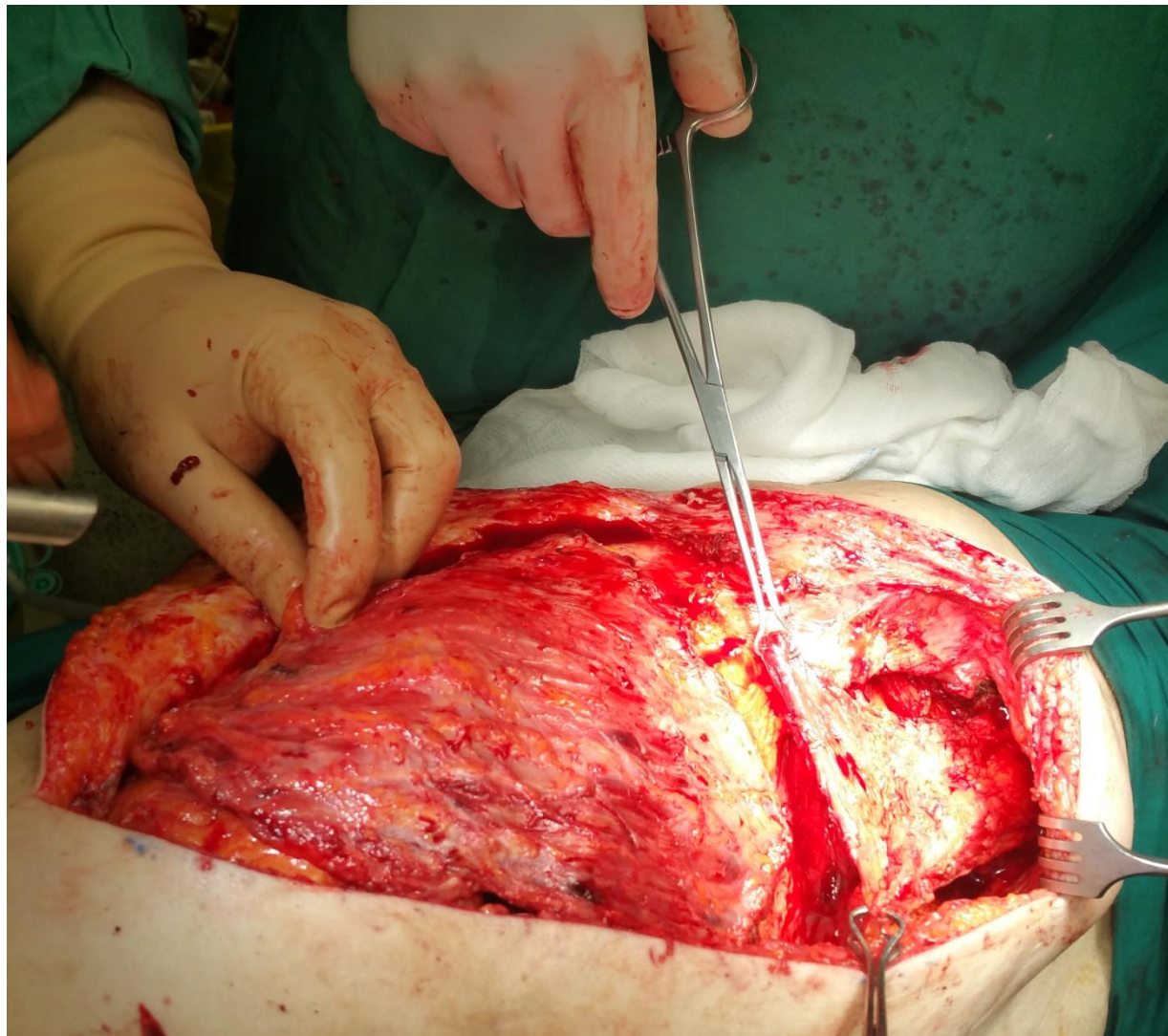
Case 2



Surgical Field

C C C
a a a
s s s
e e e
1 2 3

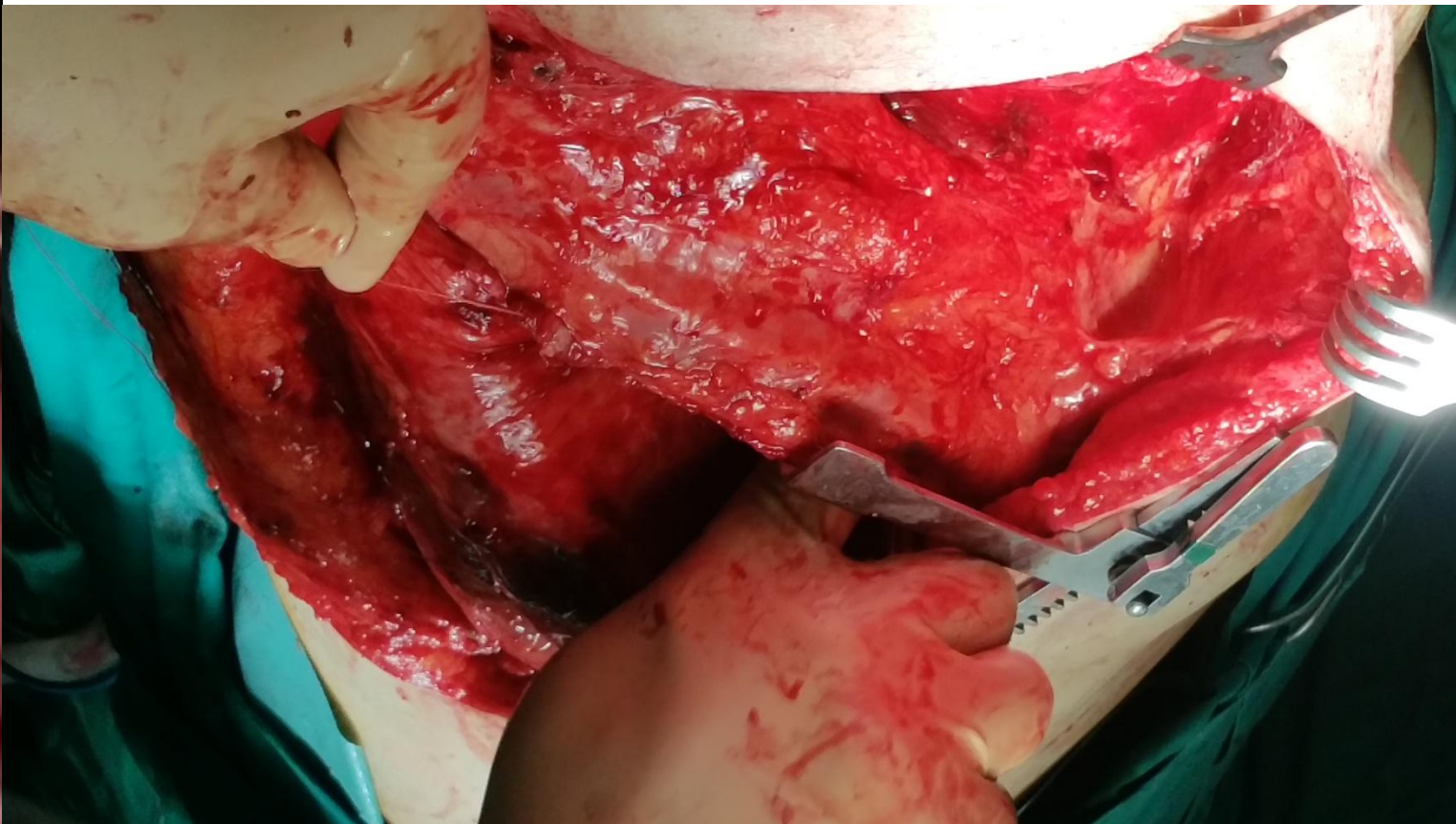
Case 2



Surgical Field

C C C
a a a
s s s
e e e
1 2 3

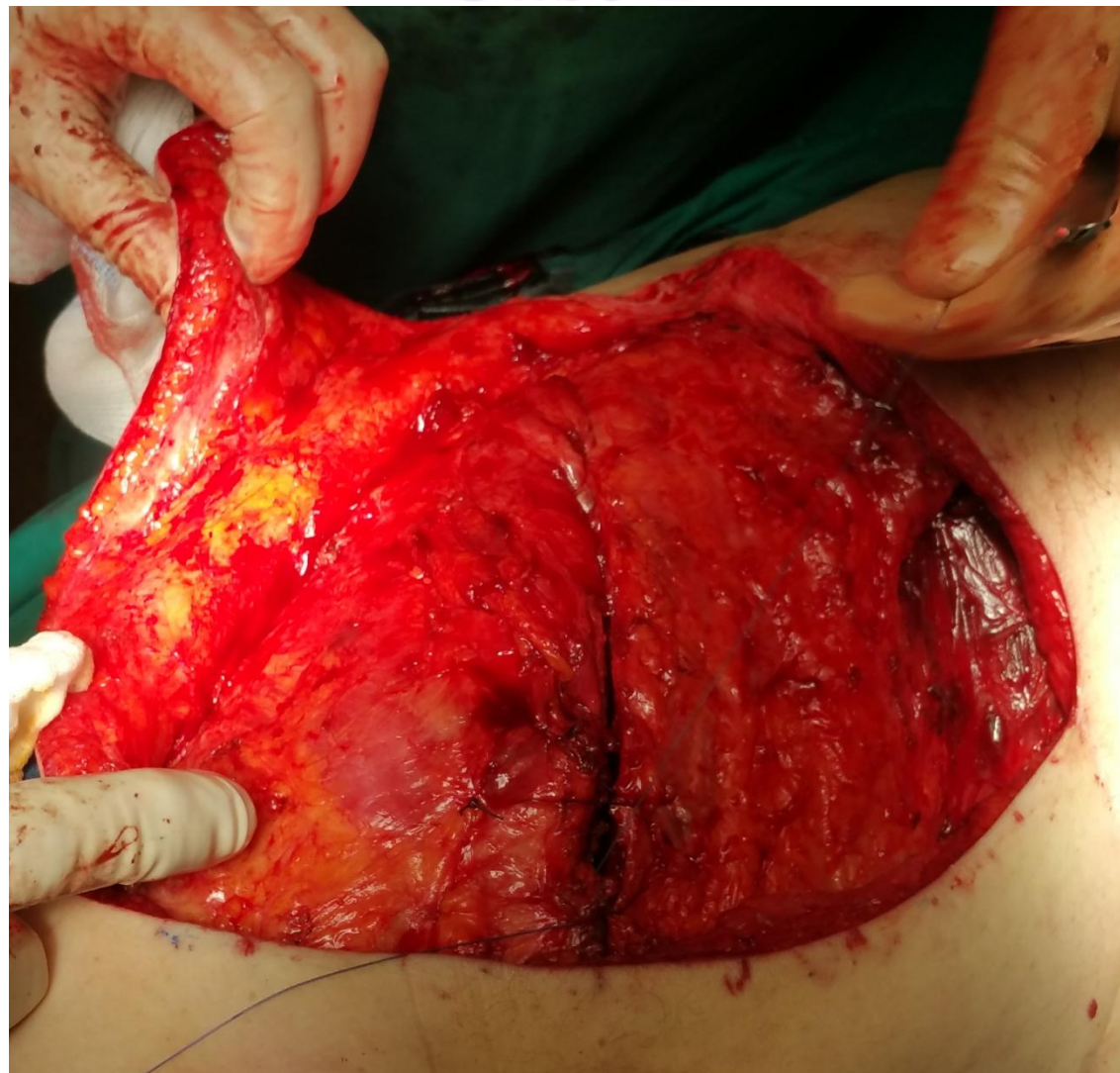
Case 2



C C C
a a a
s s s
e e e
1 2 3

Surgical Field

Case 2



Surgical Field

C C C
a a a
s s s
e e e
1 2 3

Case 2

InterBalkan
11007621

Ηλικία κατά την εξέταση: 73 years old

4/4/1944

Gantry: 0°

Time: 3622 ms

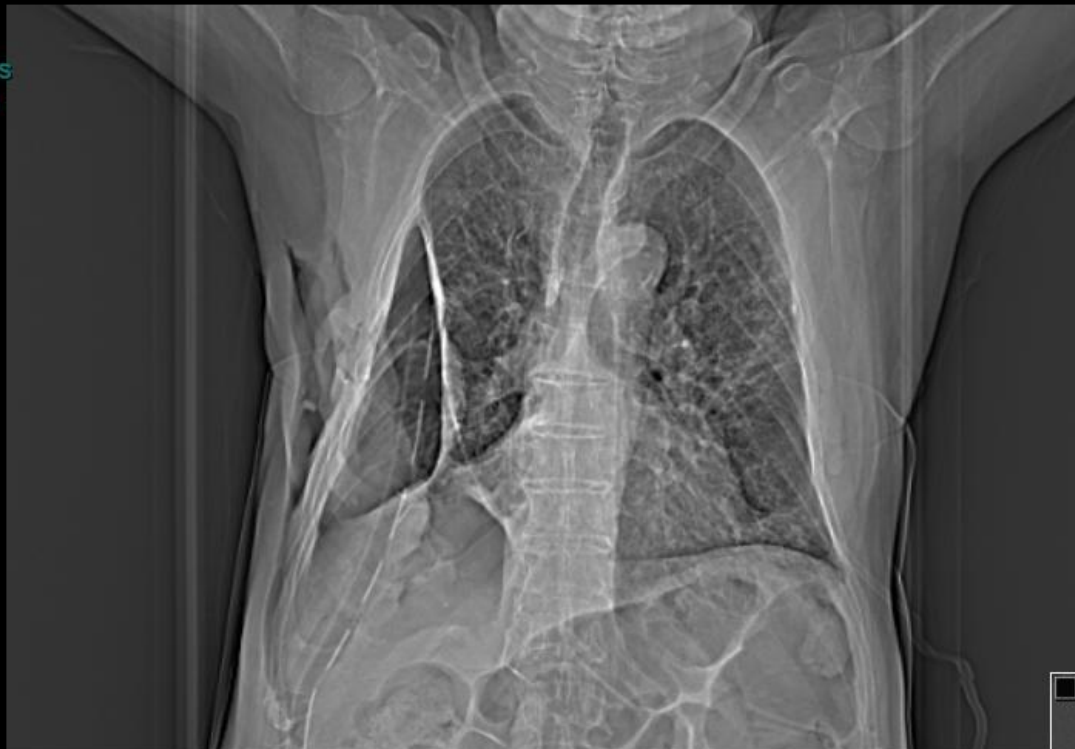Couch: -855,5

Pos: HFS

C: 50,0, W: 350,0

WINDOW1 1/8

Age: 73 years old



F: T20f

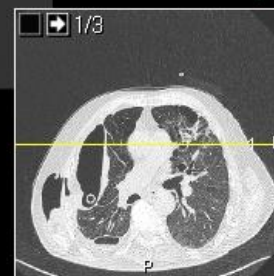
35 mA

120 kV

Image no: 1

Εικόνα 1 από 5

27/9/2017, 11:30:52 πμ



postOp (7 months) Chest CT Scan after thoracoplasty

C C C
a a a
s s s
e e e
1 2 3

Case 2

InterBalkan
11007621

Ηλικία κατά την εξέταση: 73 years old

4/4/1944

Gantry: 0°

Time: 500 ms

Τομή: 1 mm

Couch: -911,1

Pos: HFS

C: -600,0, W: 1500,0

WINDOW1 1/8

Age: 73 years old



F: B70f

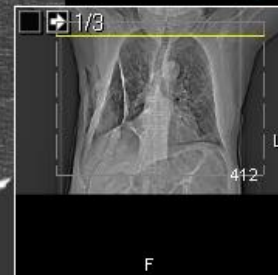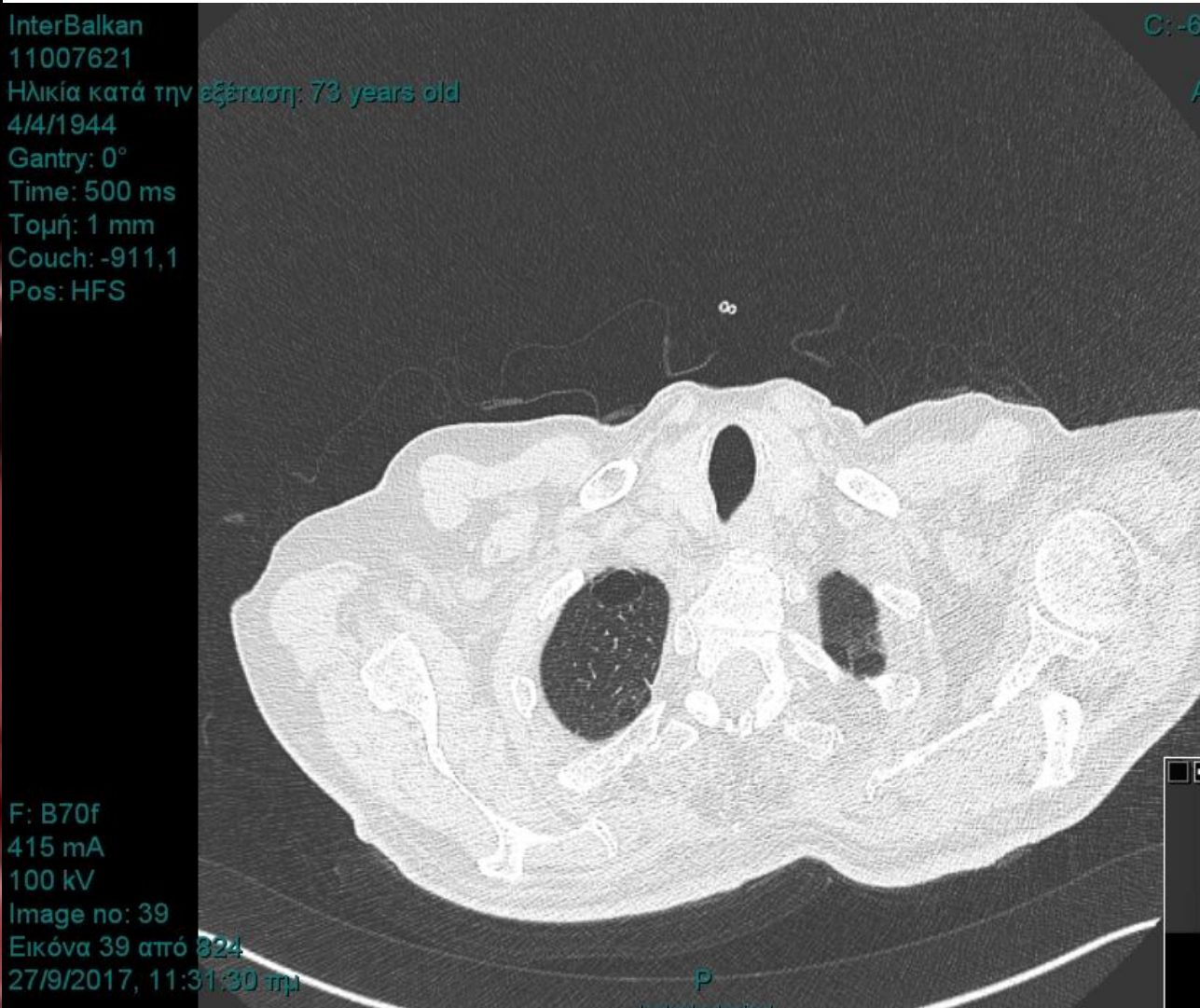415 mA

100 kV

Image no: 39

Εικόνα 39 από 324

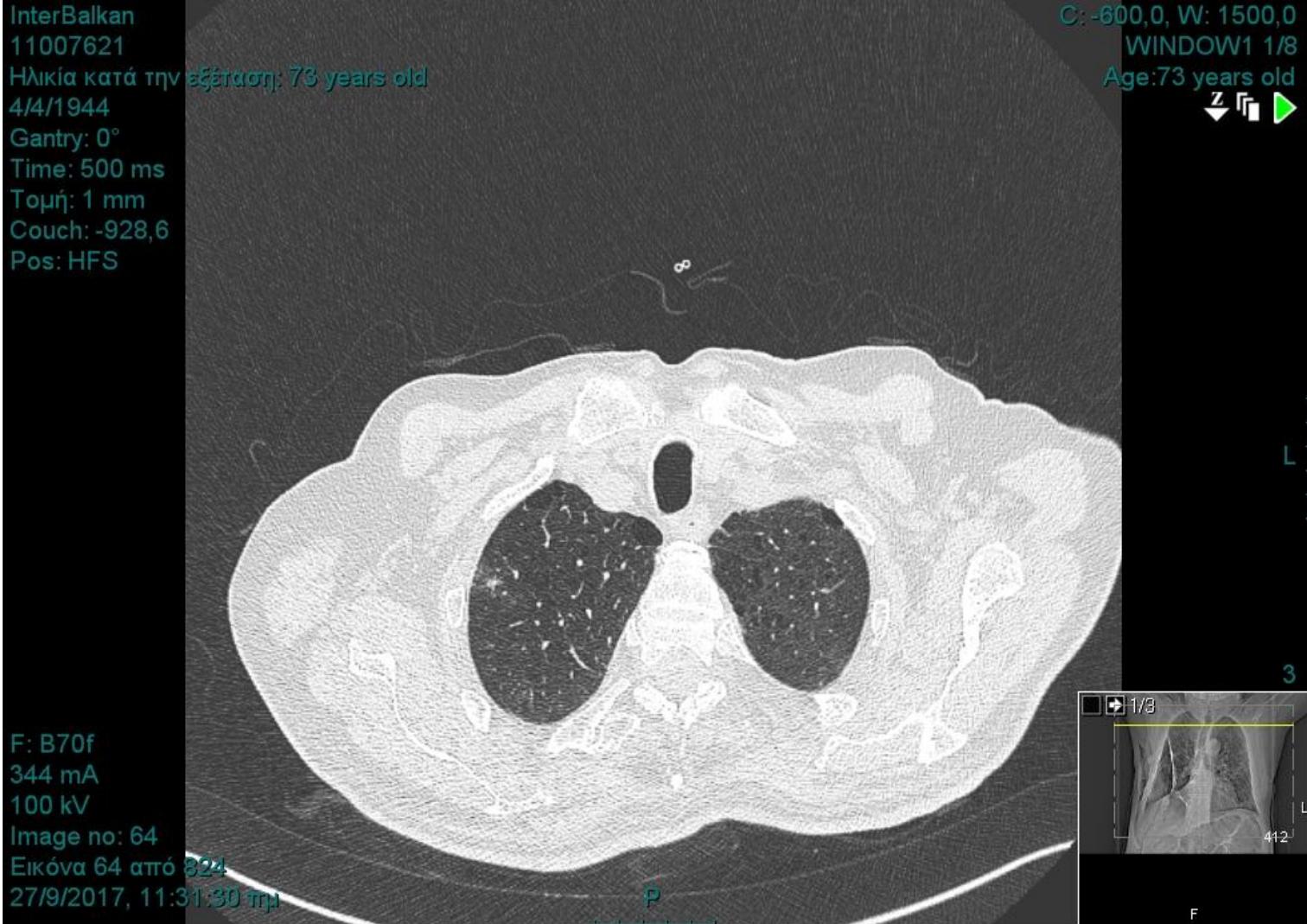
27/9/2017, 11:31:30 πμ



postOp (7 months) Chest CT Scan after thoracoplasty

C C C
a a a
s s s
e e e
1 2 3

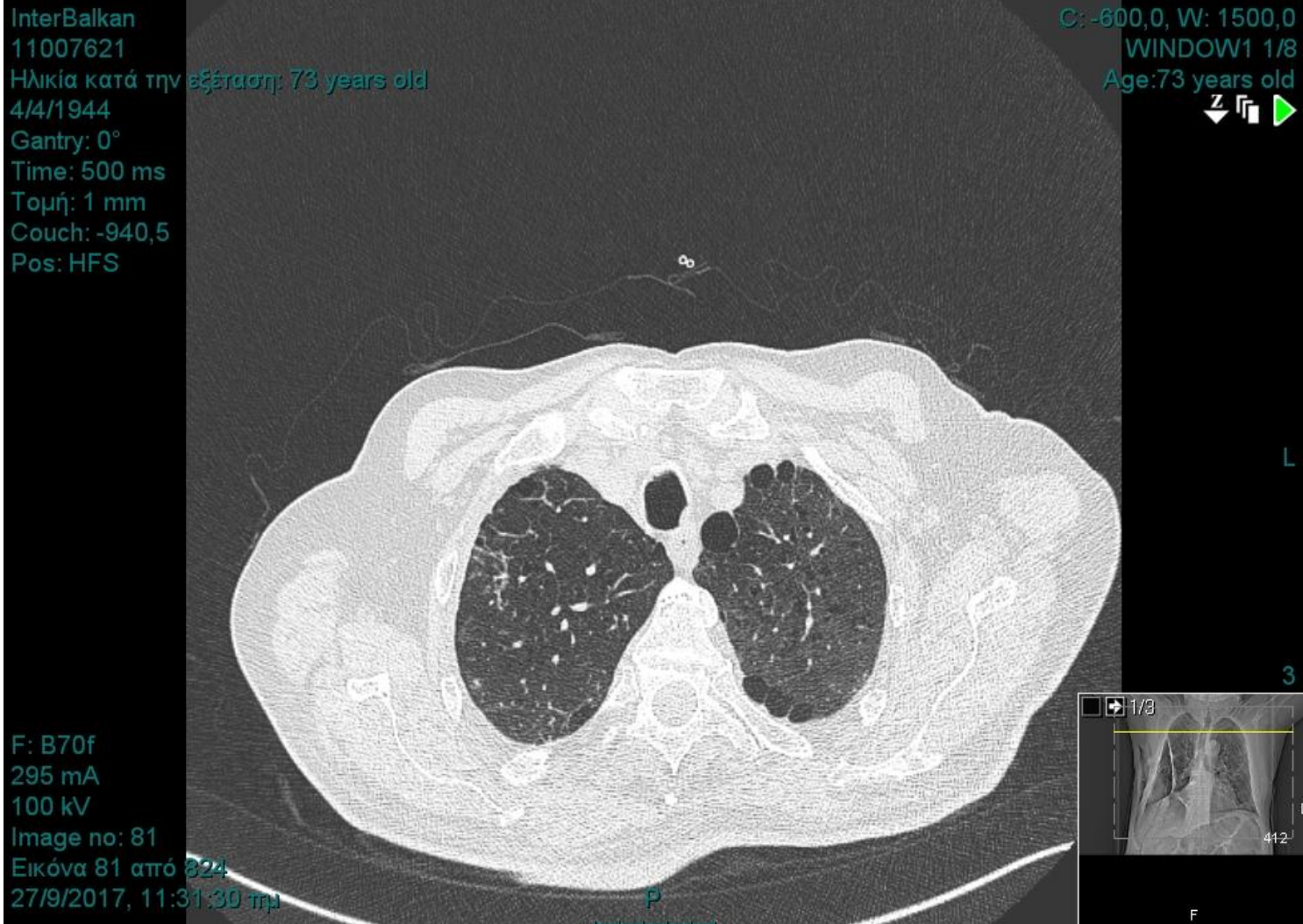
Case 2



postOp (7 months) Chest CT Scan after thoracoplasty

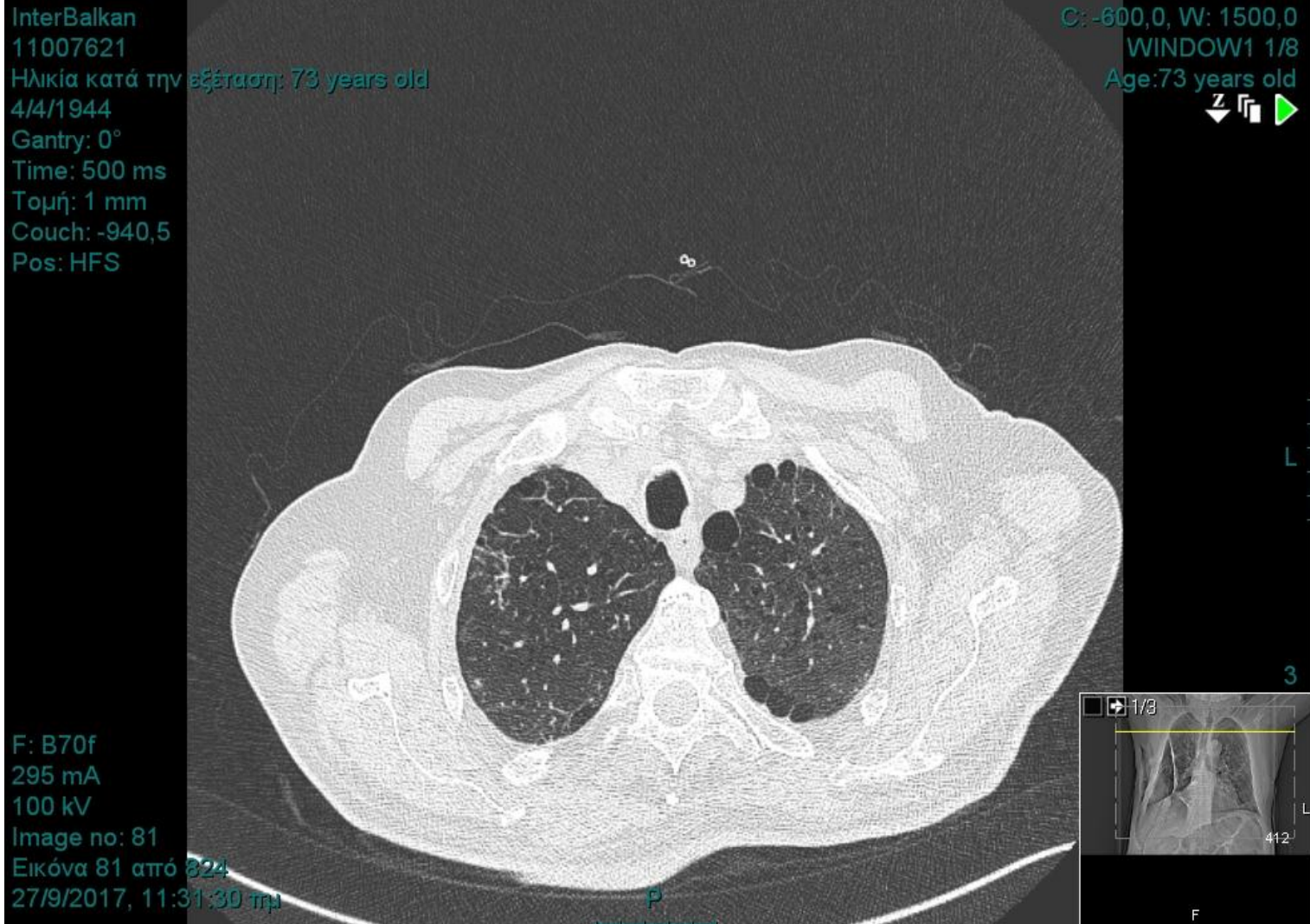
C C C
a a a
s s s
e e e
1 2 3

Case 2



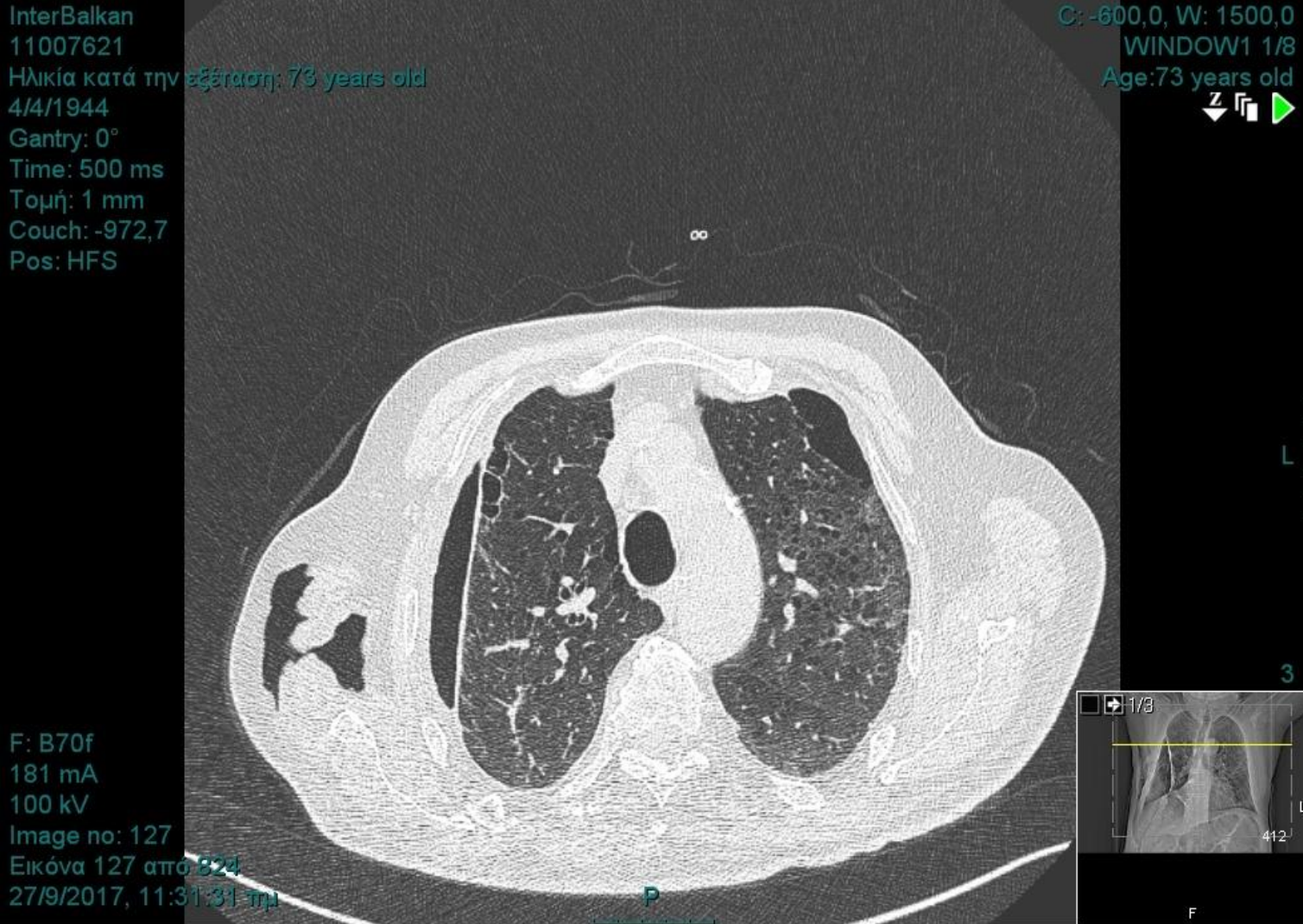
postOp (7 months) Chest CT Scan after thoracoplasty

Case 2



postOp (7 months) Chest CT Scan after thoracoplasty

Case 2



postOp (7 months) Chest CT Scan after thoracoplasty

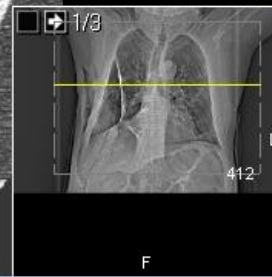
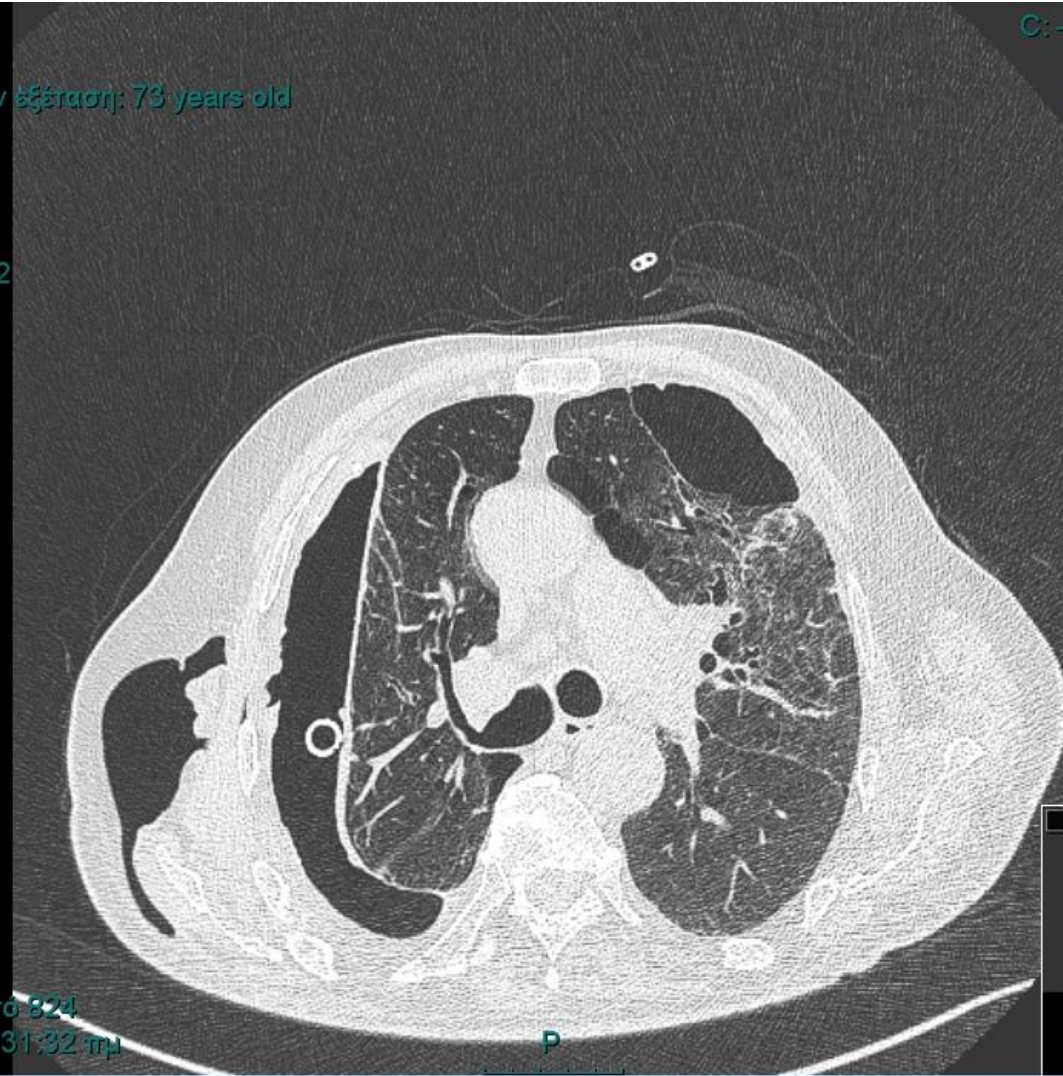
Case 2

InterBalkan
11007621
Ηλικία κατά την εξέταση: 73 years old
4/4/1944
Gantry: 0°
Time: 500 ms
Τομή: 1 mm
Couch: -1004,2
Pos: HFS

C: -600,0, W: 1500,0
WINDOW1 1/8
Age: 73 years old



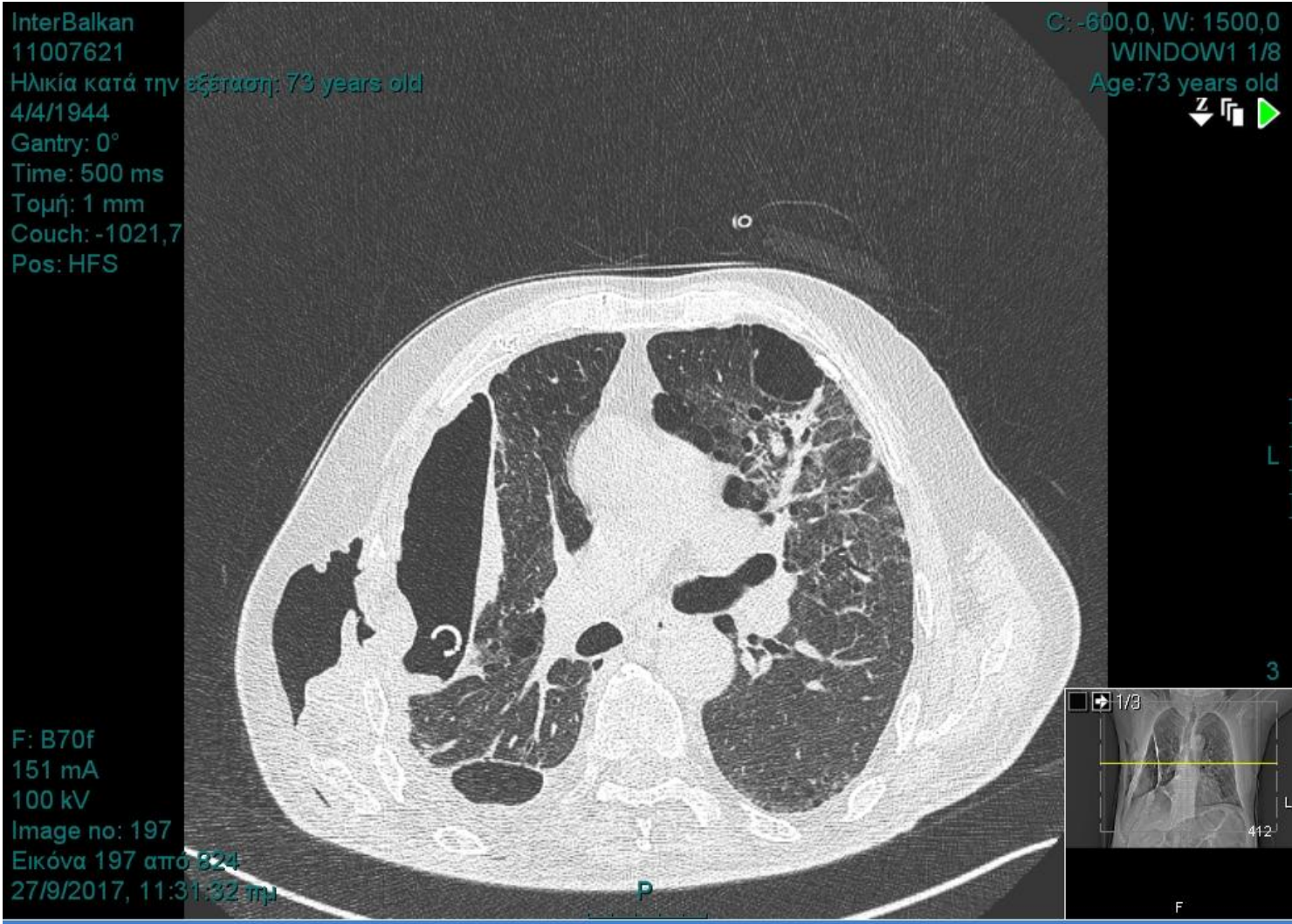
F: B70f
167 mA
100 kV
Image no: 172
Εικόνα 172 από 824
27/9/2017, 11:31:32 πμ



postOp (7 months) Chest CT Scan after thoracoplasty

C C C
a a a
s s s
e e e
1 2 3

Case 2



postOp (7 months) Chest CT Scan after thoracoplasty

C C C
a a a
s s s
e e e
1 2 3

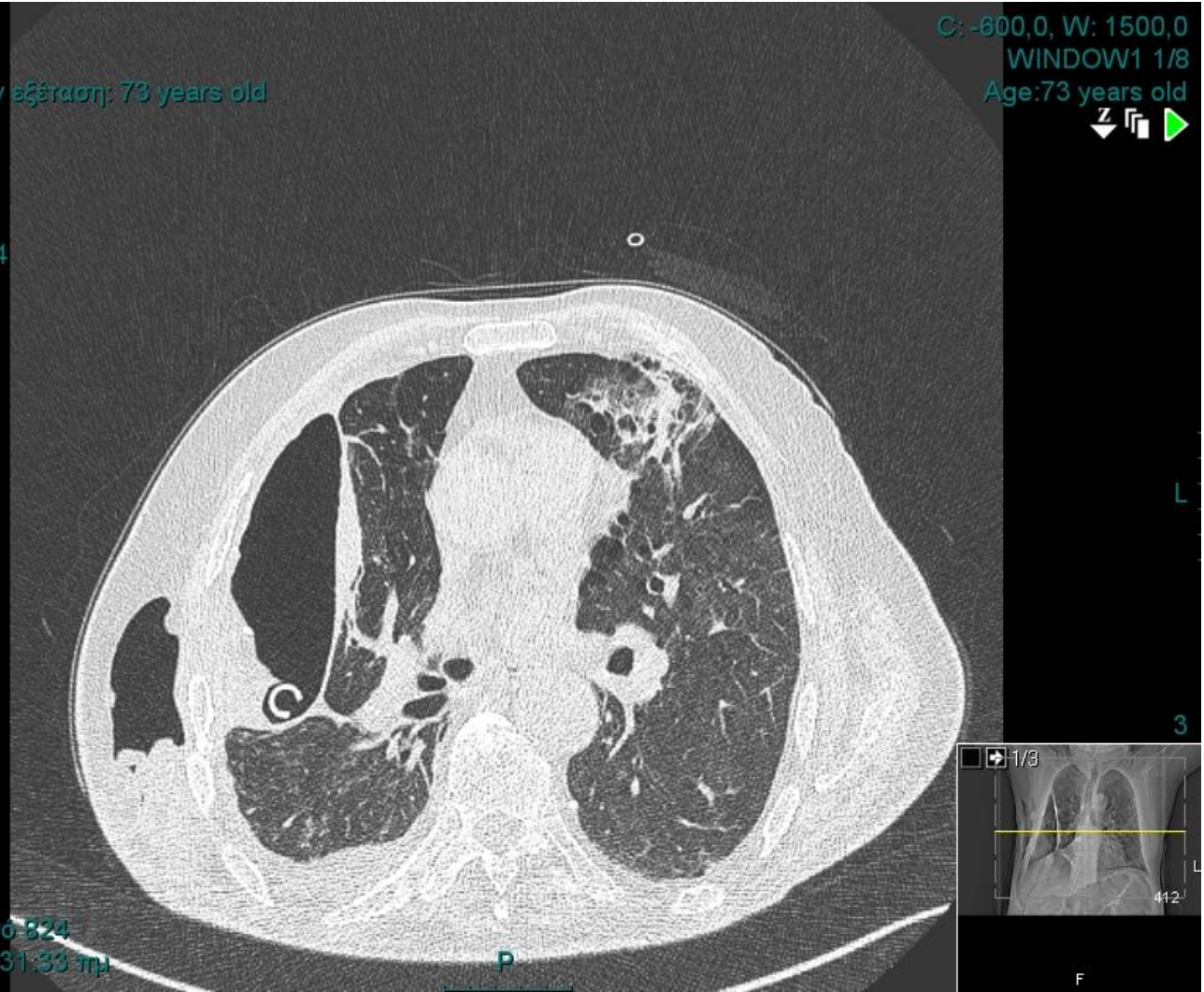
Case 2

InterBalkan
11007621
Ηλικία κατά την εξέταση: 73 years old
4/4/1944
Gantry: 0°
Time: 500 ms
Τομή: 1 mm
Couch: -1036,4
Pos: HFS

C: -600,0, W: 1500,0
WINDOW1 1/8
Age: 73 years old



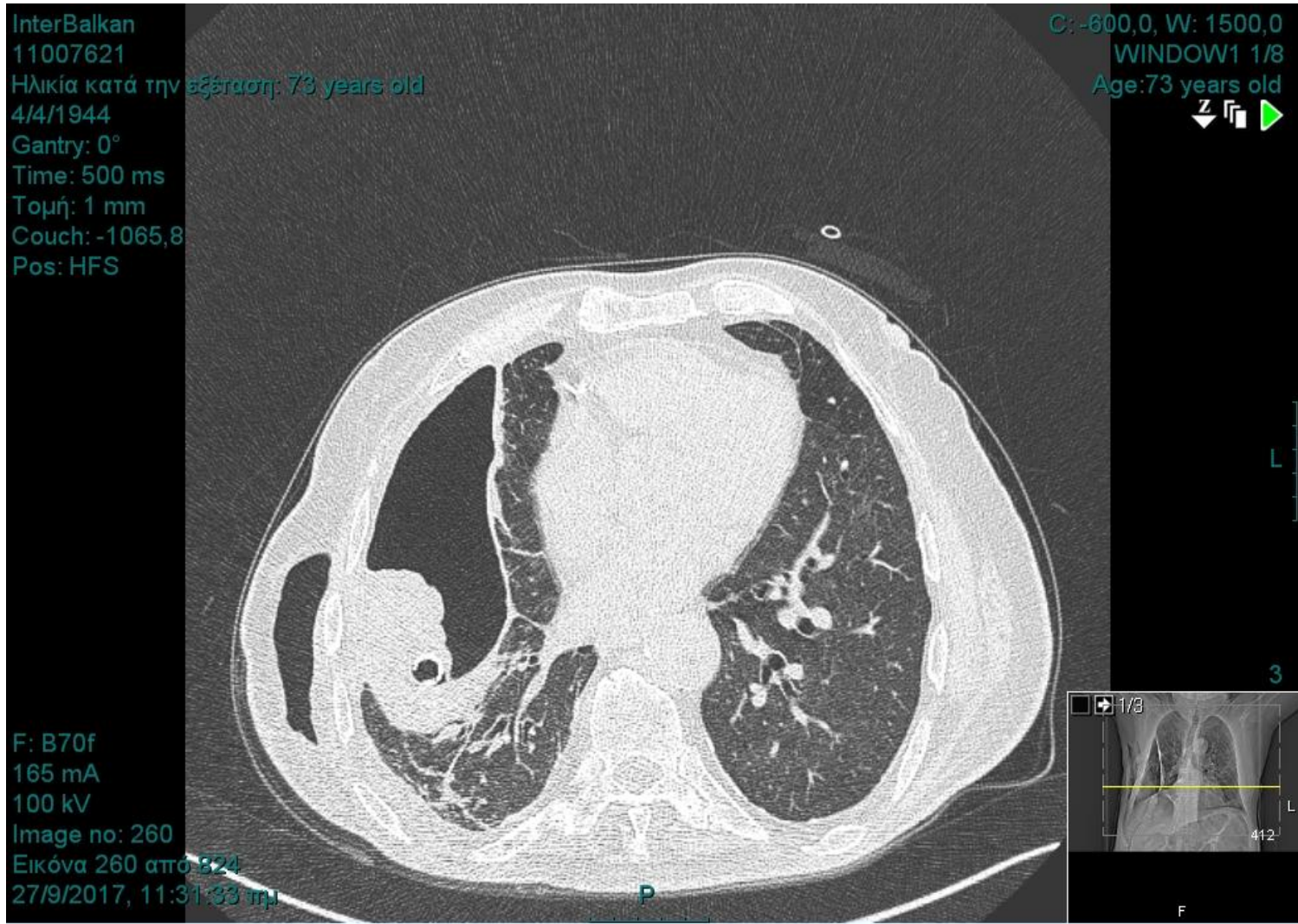
F: B70f
146 mA
100 kV
Image no: 218
Εικόνα 218 από 824
27/9/2017, 11:31:33 πμ



postOp (7 months) Chest CT Scan after thoracoplasty

C C C
a a a
s s s
e e e
1 2 3

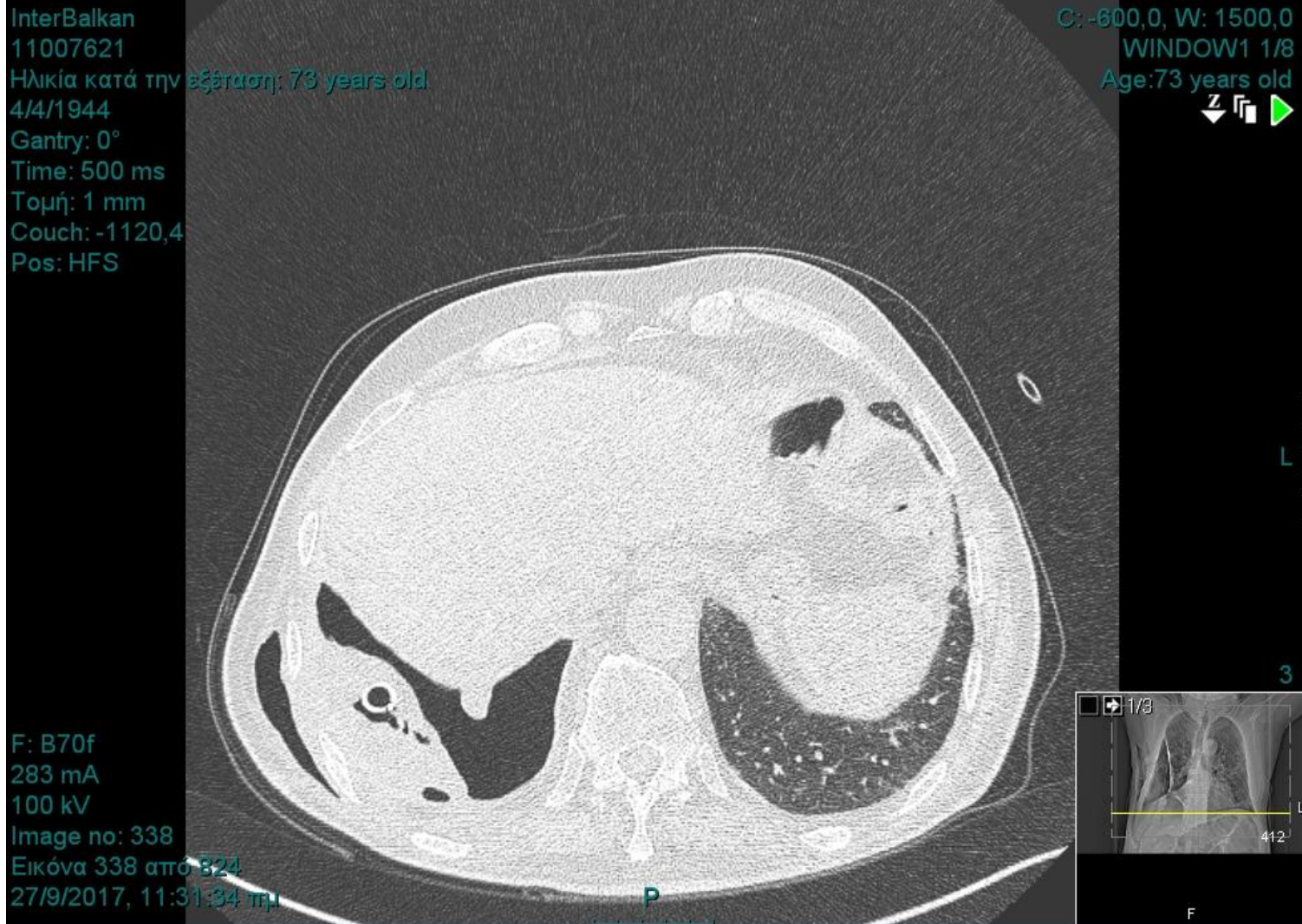Case 2



postOp (7 months) Chest CT Scan after thoracoplasty

C C C
a a a
s s s
e e e
1 2 3

Case 2



postOp (7 months) Chest CT Scan after thoracoplasty

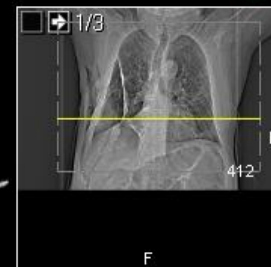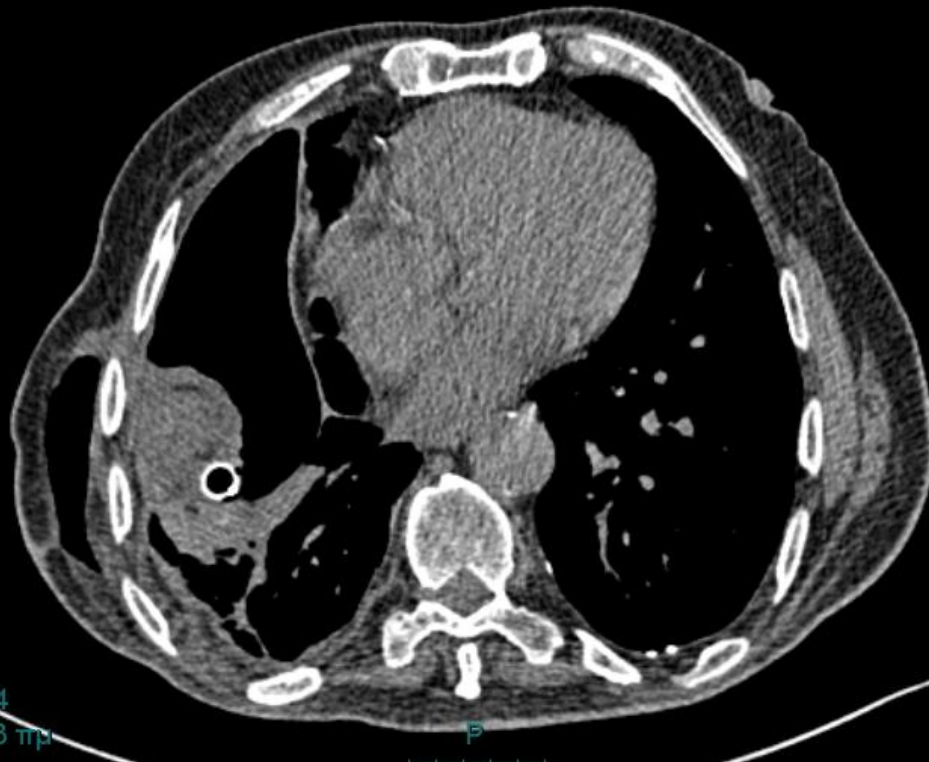Case 2

InterBalkan
11007621
Ηλικία κατά την εξέταση: 73 years old
4/4/1944
Gantry: 0°
Time: 500 ms
Τομή: 1 mm
Couch: -1071,4
Pos: HFS

C: 40,0, W: 400,0
WINDOW1 1/8
Age: 73 years old



F: B20f
170 mA
100 kV
Image no: 268
Εικόνα 268 από 824
27/9/2017, 11:31:33 πμ



postOp (7 months) Chest CT Scan after thoracoplasty

C C C
a a a
s s s
e e e
1 2 3

Case 2

What next?

- 1. Reoperation**
- 2. Antibiotics**
- 3. Voriconazole**
- 4. Re-Thoracoplasty**
- 5. Thoracostomy**

C C C
a a a
s s s
e e e
1 2 3

Case 2

What next?

1. Reoperation
2. Antibiotics
3. **Voriconazole**
4. Re-Thoracoplasty
5. **Thoracostomy**

C C C
a a a
s s s
e e e
1 2 3

Thank U for your attention!



Case 3

Female 62 y

Chief Complain:

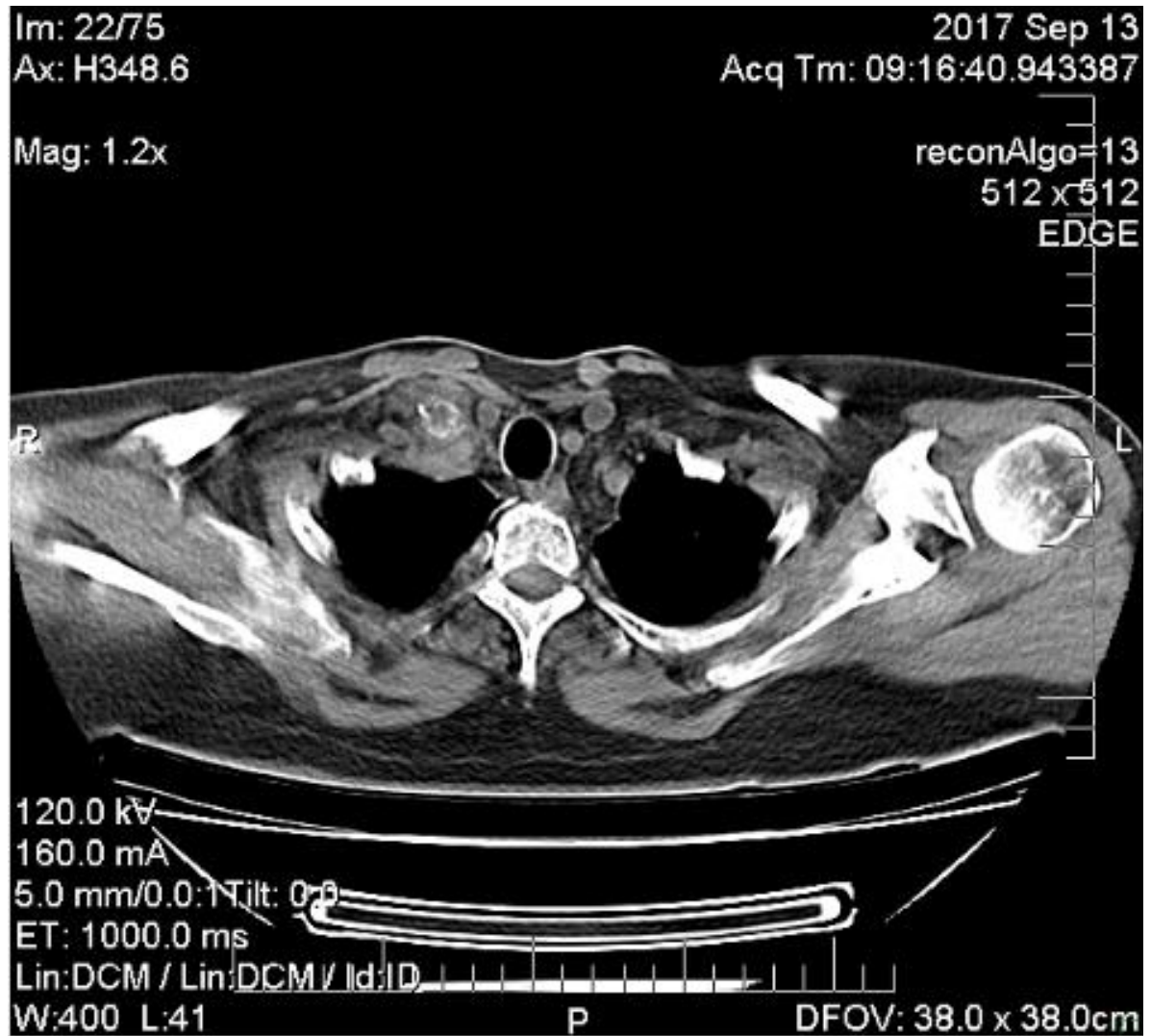- Unspecified chest pain
- Supraclavicular mass

Personal Medical History:

- Thyroid FNA: unspecified histology
- Hysterectomy (14y ago)
borderline ovarian Ca

C C C
a a a
s s s
e e e
1 2 3

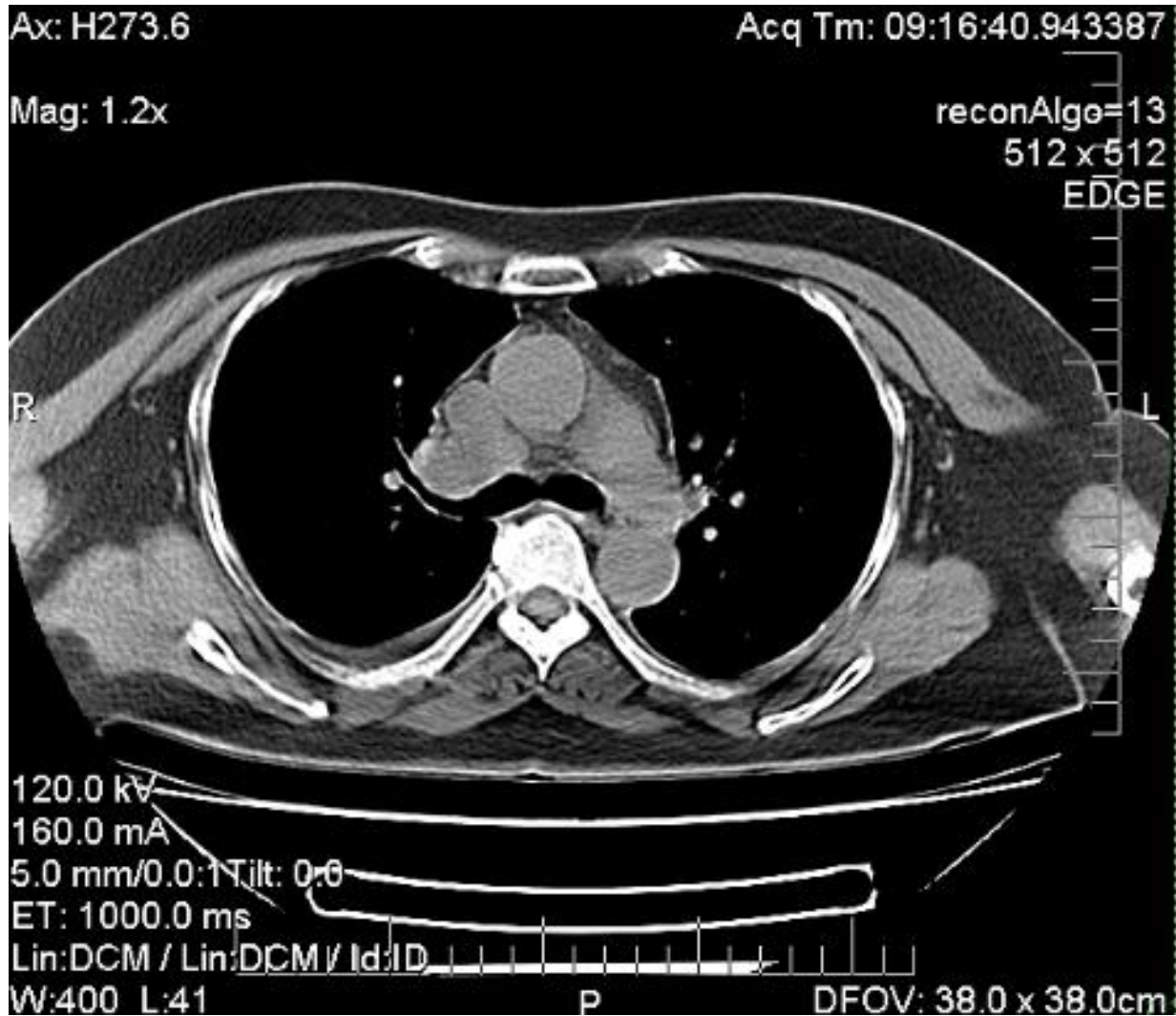
Case 3



preOp Chest CT Scan

C C C
a a a
s s s
e e e
1 2 3

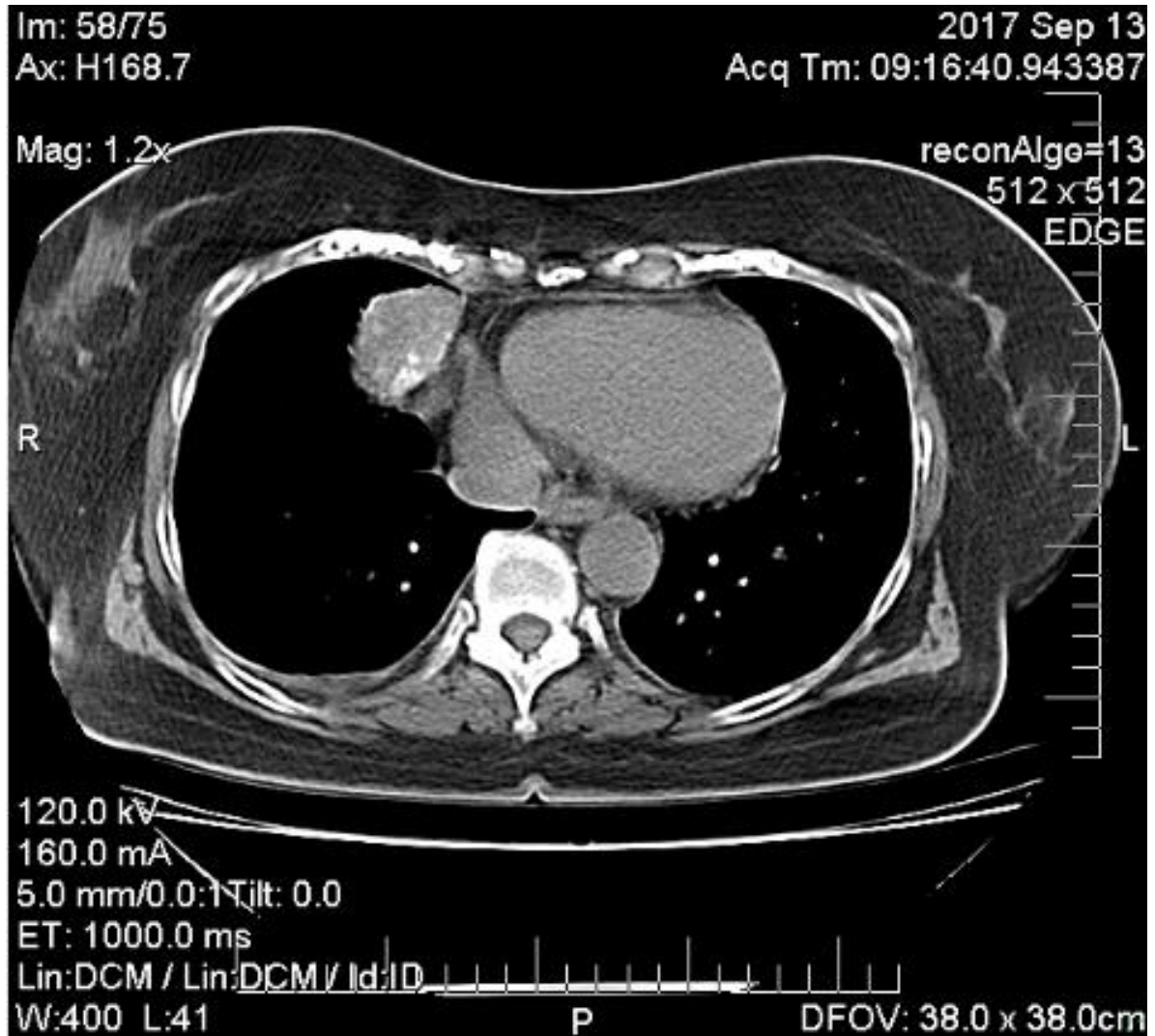
Case 3



preOp Chest CT Scan

C C C
a a a
s s s
e e e
1 2 3

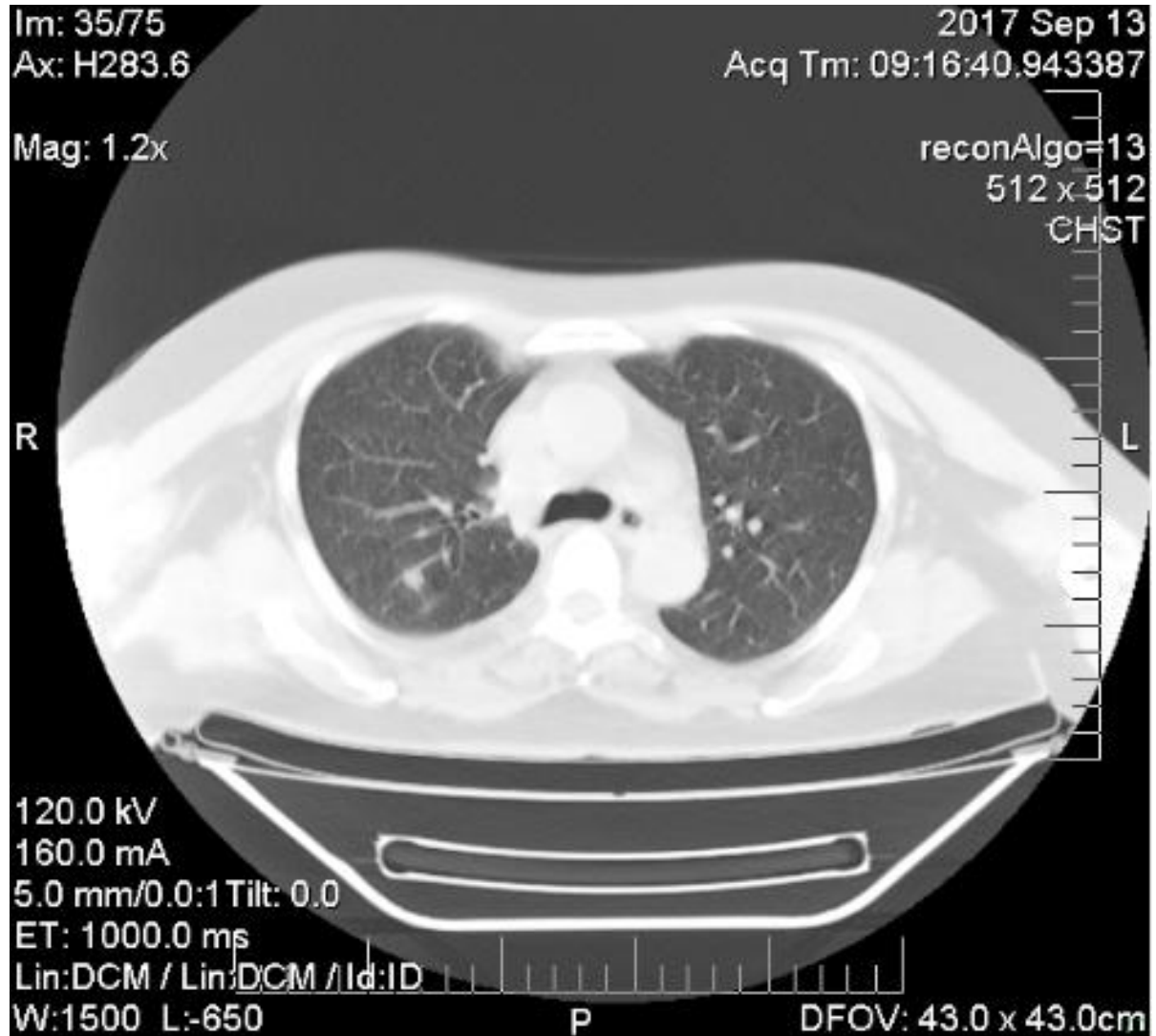
Case 3




preOp Chest CT Scan

C C C
a a a
s s s
e e e
1 2 3

Case 3



preOp Chest CT Scan



Case 2

Diagnostic Plan

1. PET-CT
2. Iodine Scan
3. Biopsy (which first?)

C C C
a a a
s s s
e e e
1 2 3

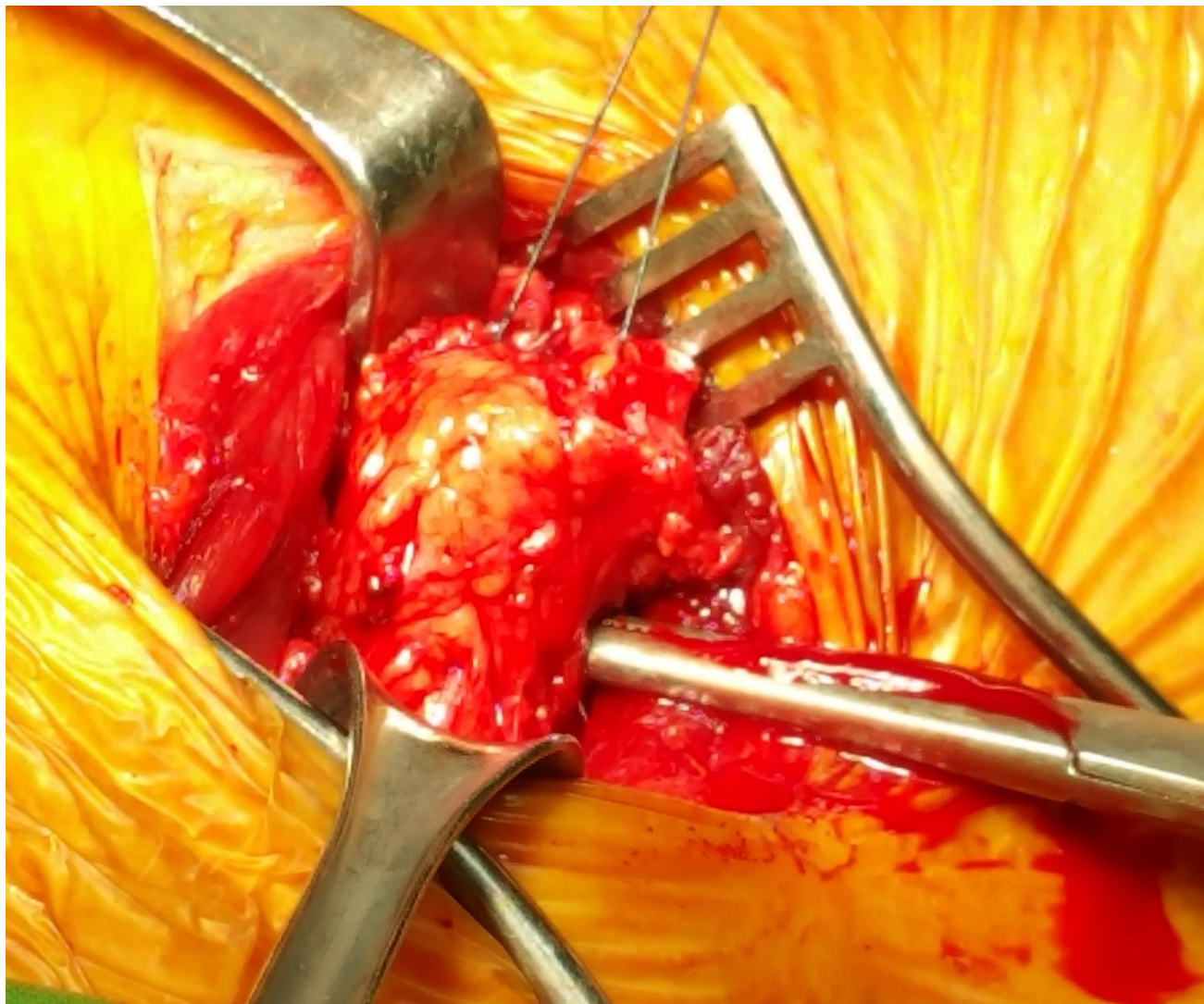
Case 2

Diagnostic Plan

1. **PET-CT**
2. Iodine Scan
3. **Biopsy (Supraclavicular mass)**

C C C
a a a
s s s
e e e
1 2 3

Case 3



Surgical field

C C C
a a a
s s s
e e e
1 2 3

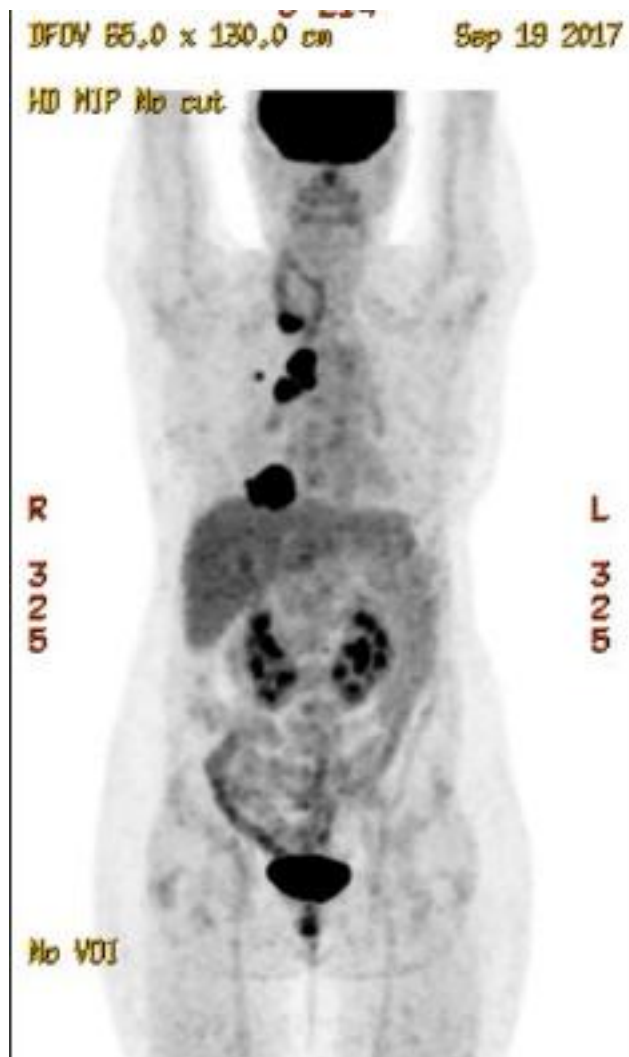
Case 3

C C C
a a a
s s s
e e e
1 2 3

Histology

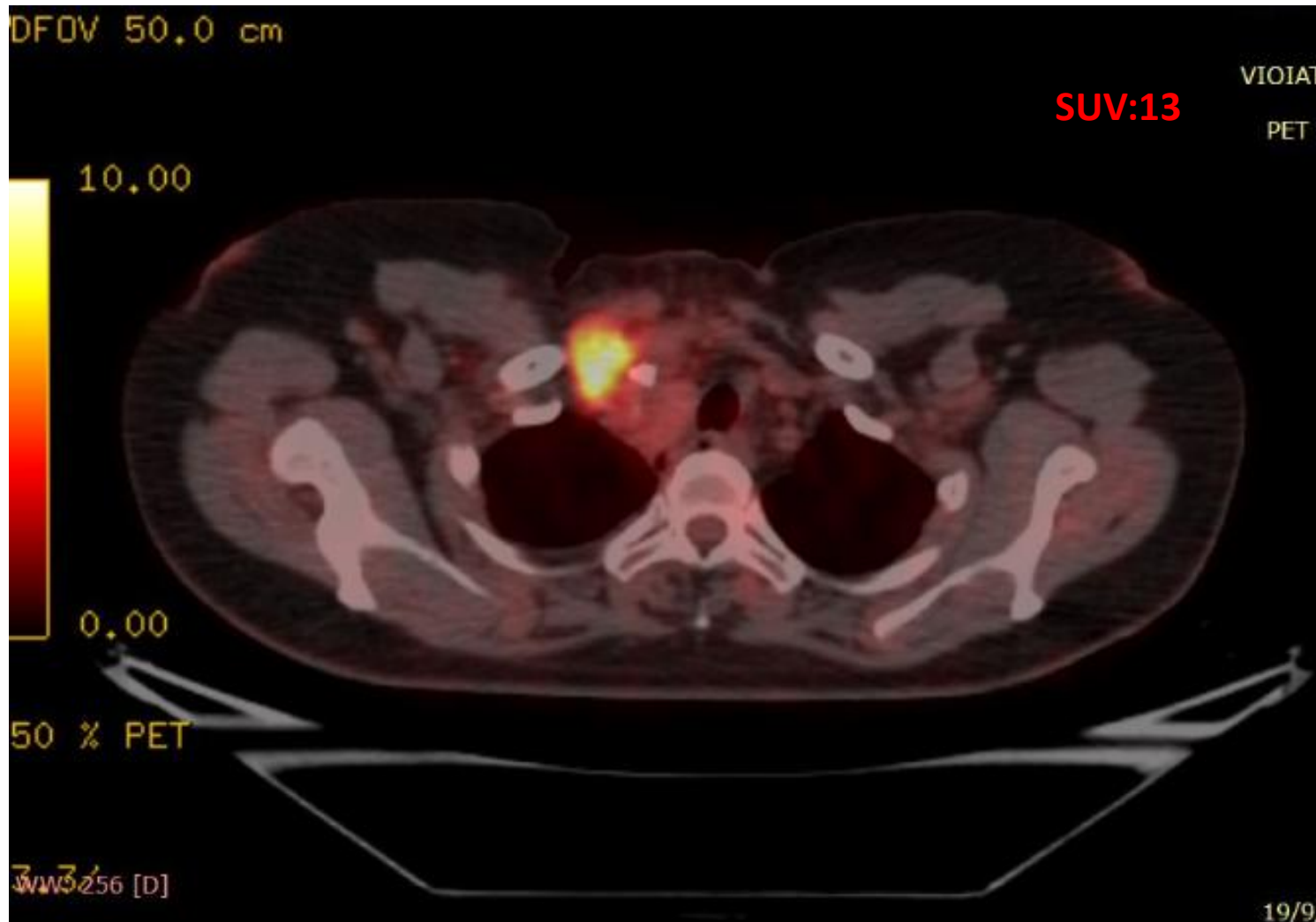

**Low grade
Metastatic ovarian cancer**

Case 3



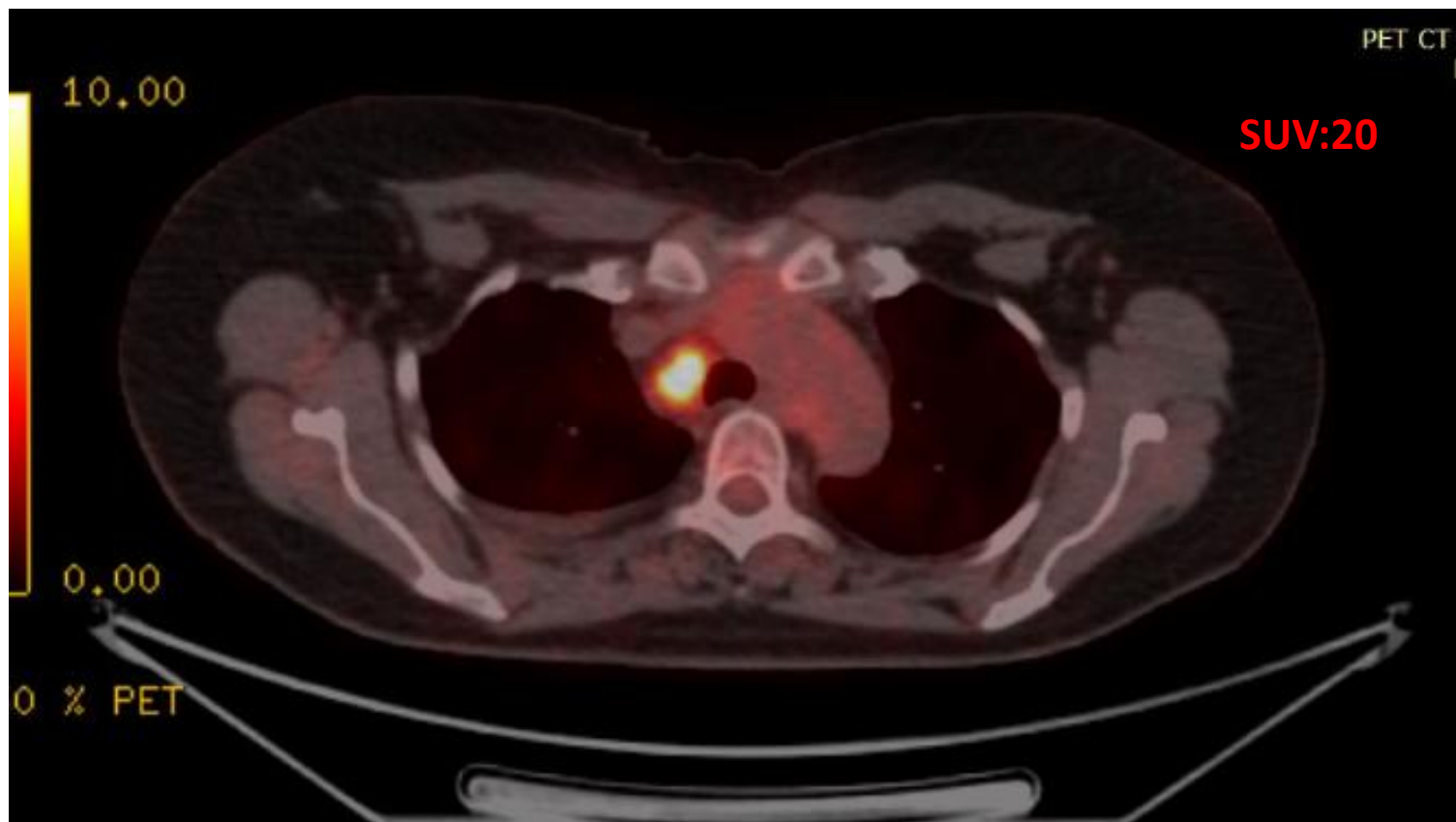

preOp PET-CT Scan

Case 3



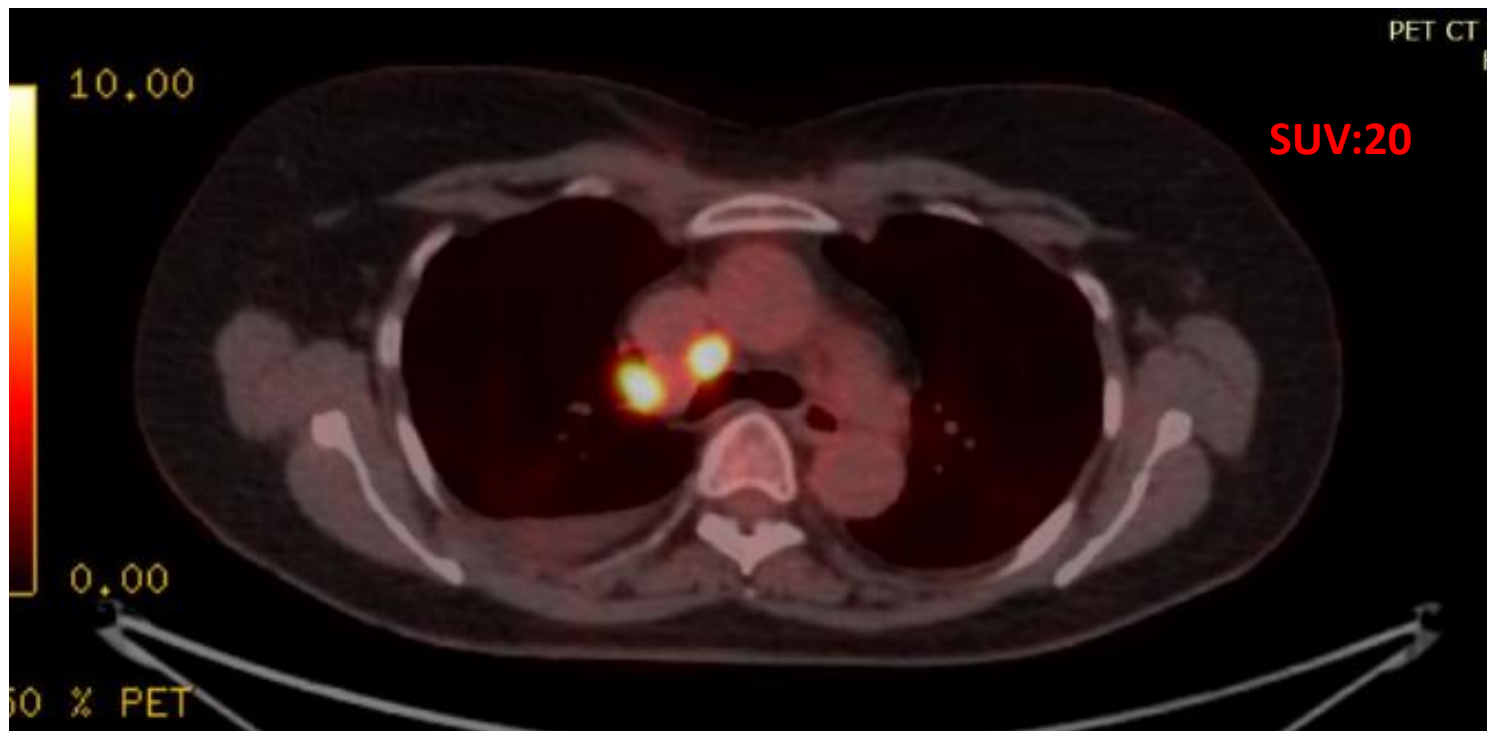

preOp PET-CT Scan

Case 3



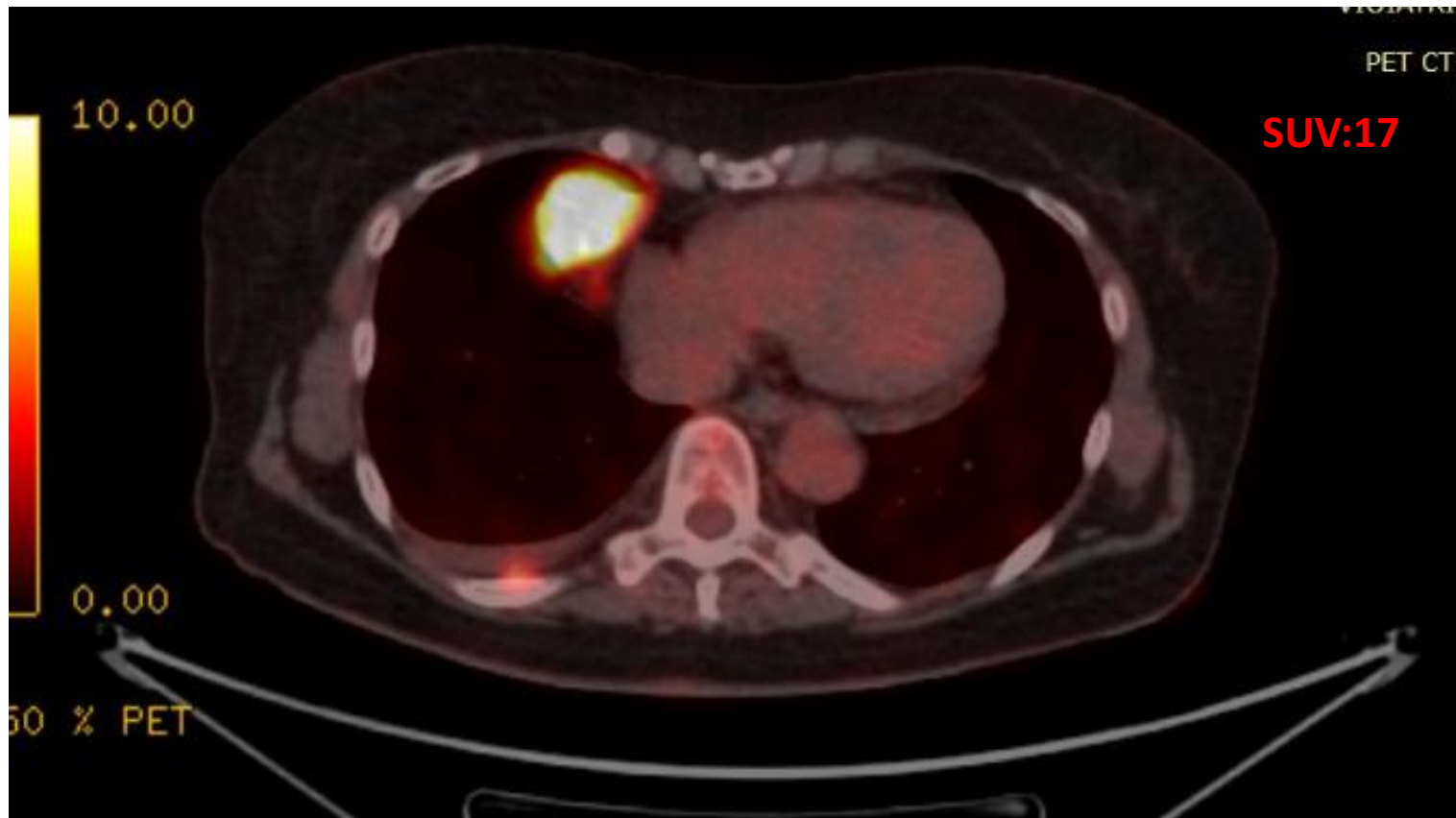

preOp PET-CT Scan

Case 3




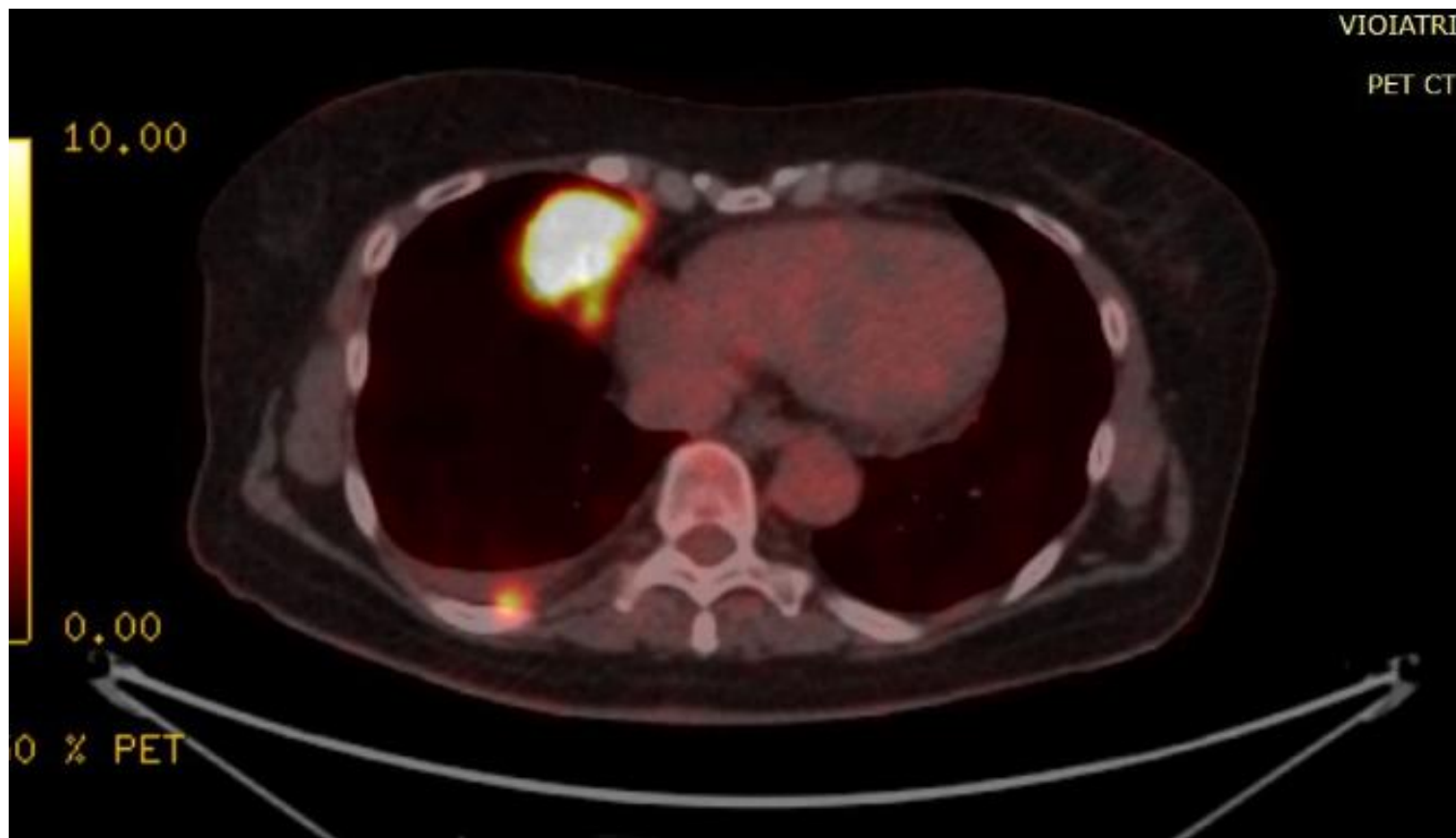
preOp PET-CT Scan

Case 3



preOp PET-CT Scan

Case 3



preOp PET-CT Scan

Case 2

Treatment Plan

1. Chemotherapy
2. Surgery
3. HITHOC
4. Radiotherapy
5. Anosotherapy

C C C
a a a
s s s
e e e
1 2 3

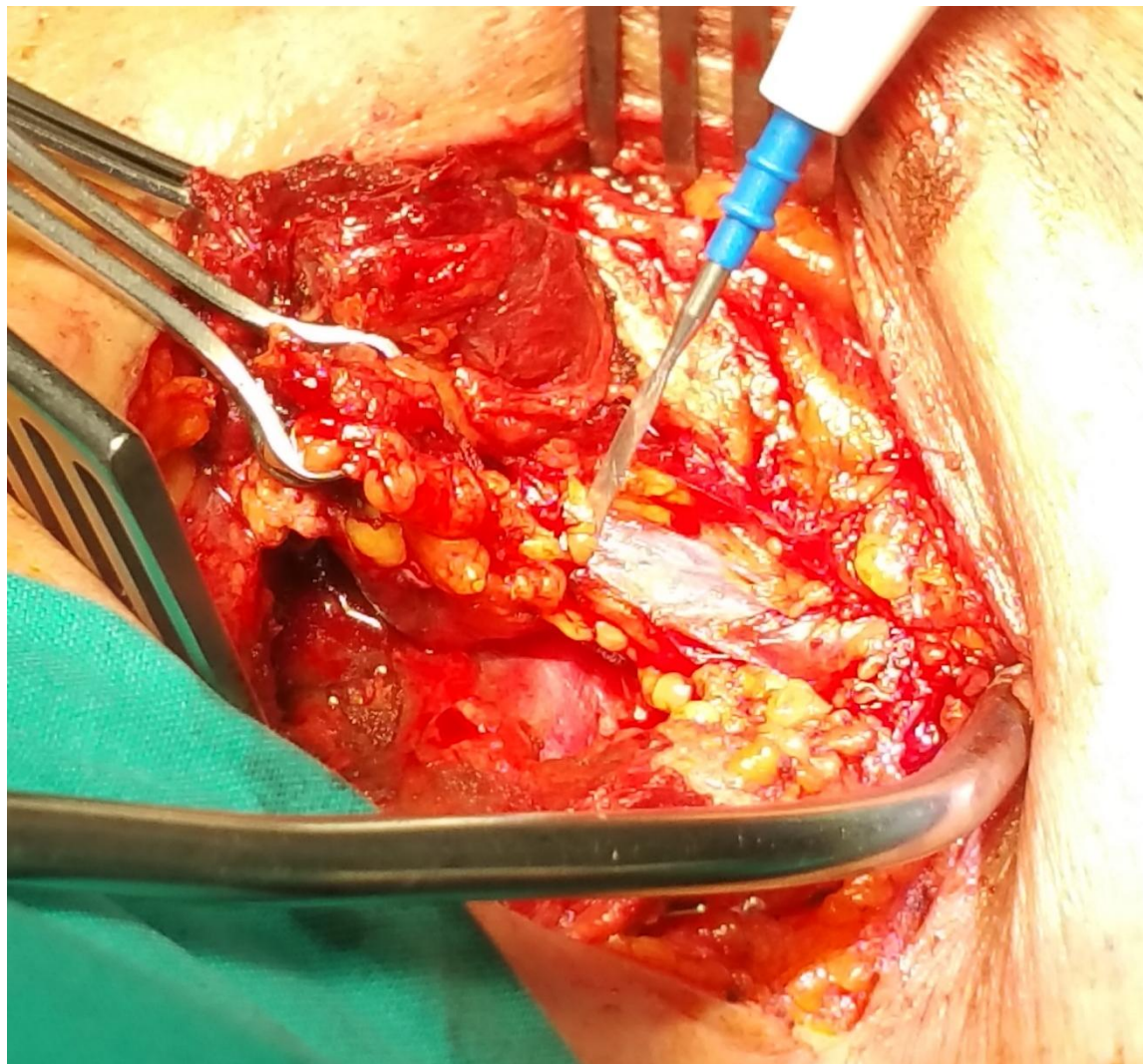
Case 2

Treatment Plan

1. Chemotherapy
2. Surgery
3. **HITHOC**
4. Radiotherapy
5. Anosotherapy

C C C
a a a
s s s
e e e
1 2 3

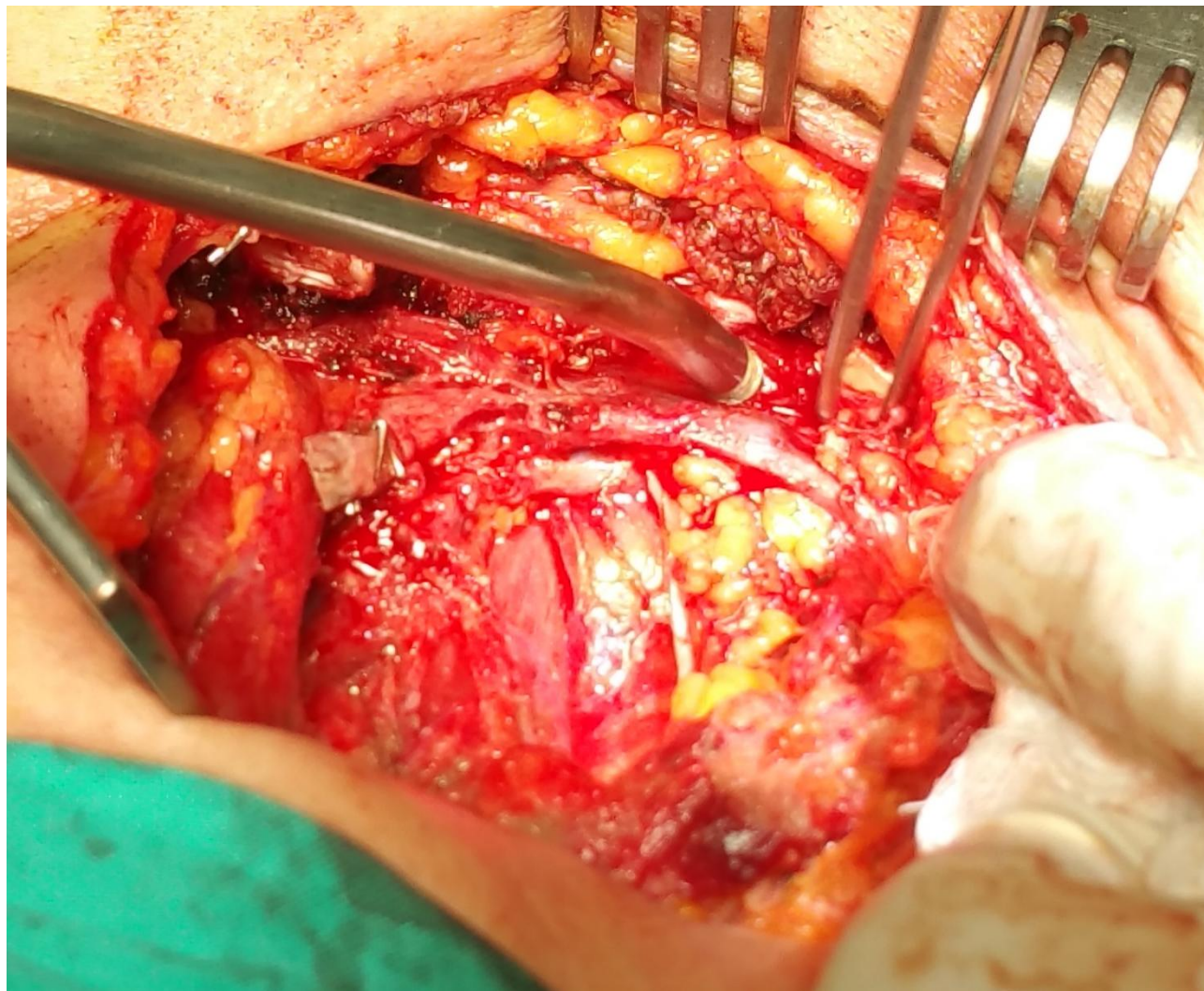
Case 3



Surgical field

C C C
a a a
s s s
e e e
1 2 3

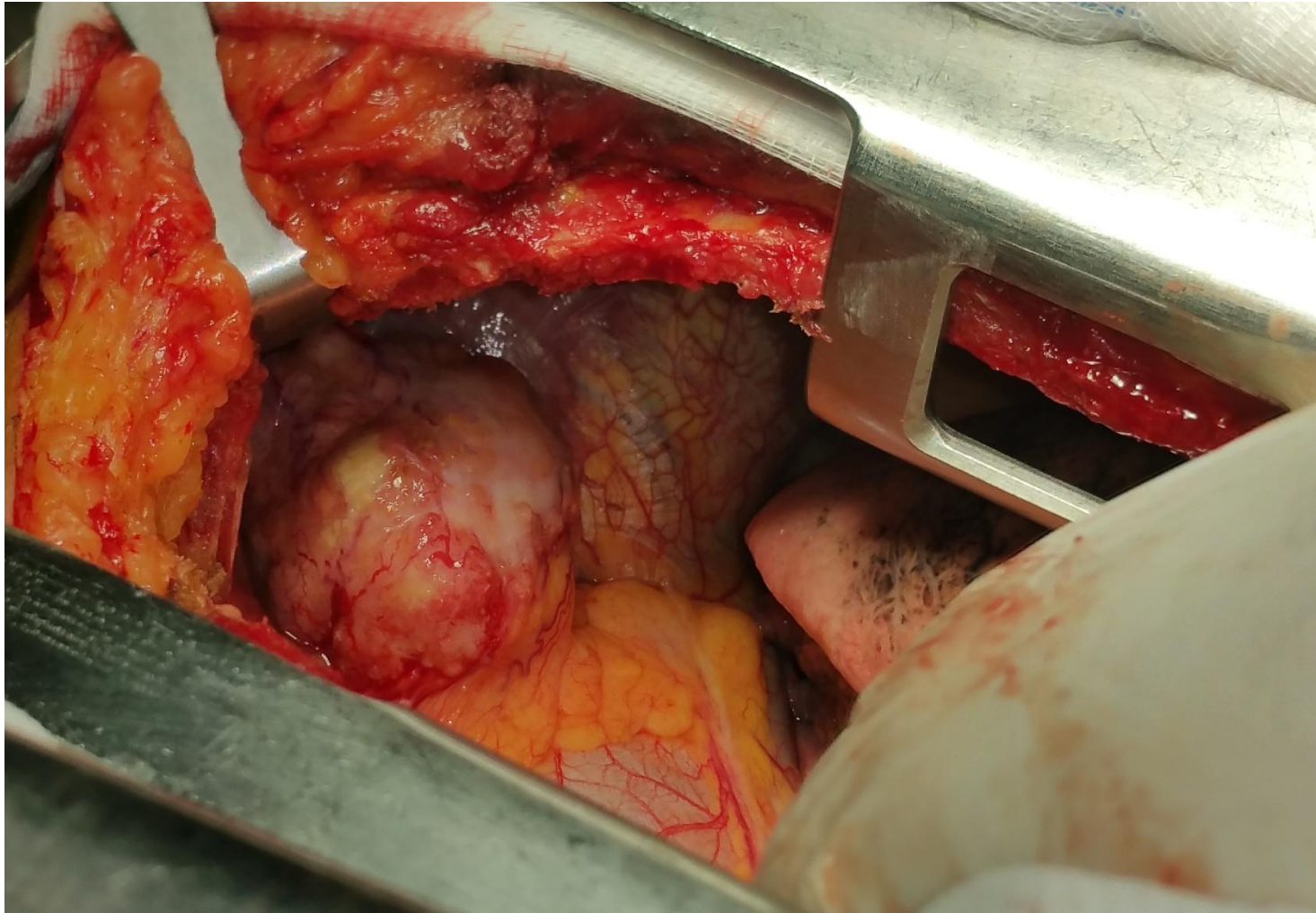
Case 3




Surgical field

C C C
a a a
s s s
e e e
1 2 3

Case 3




Surgical field



C C C
a a a
s s s
e e e
1 2 3

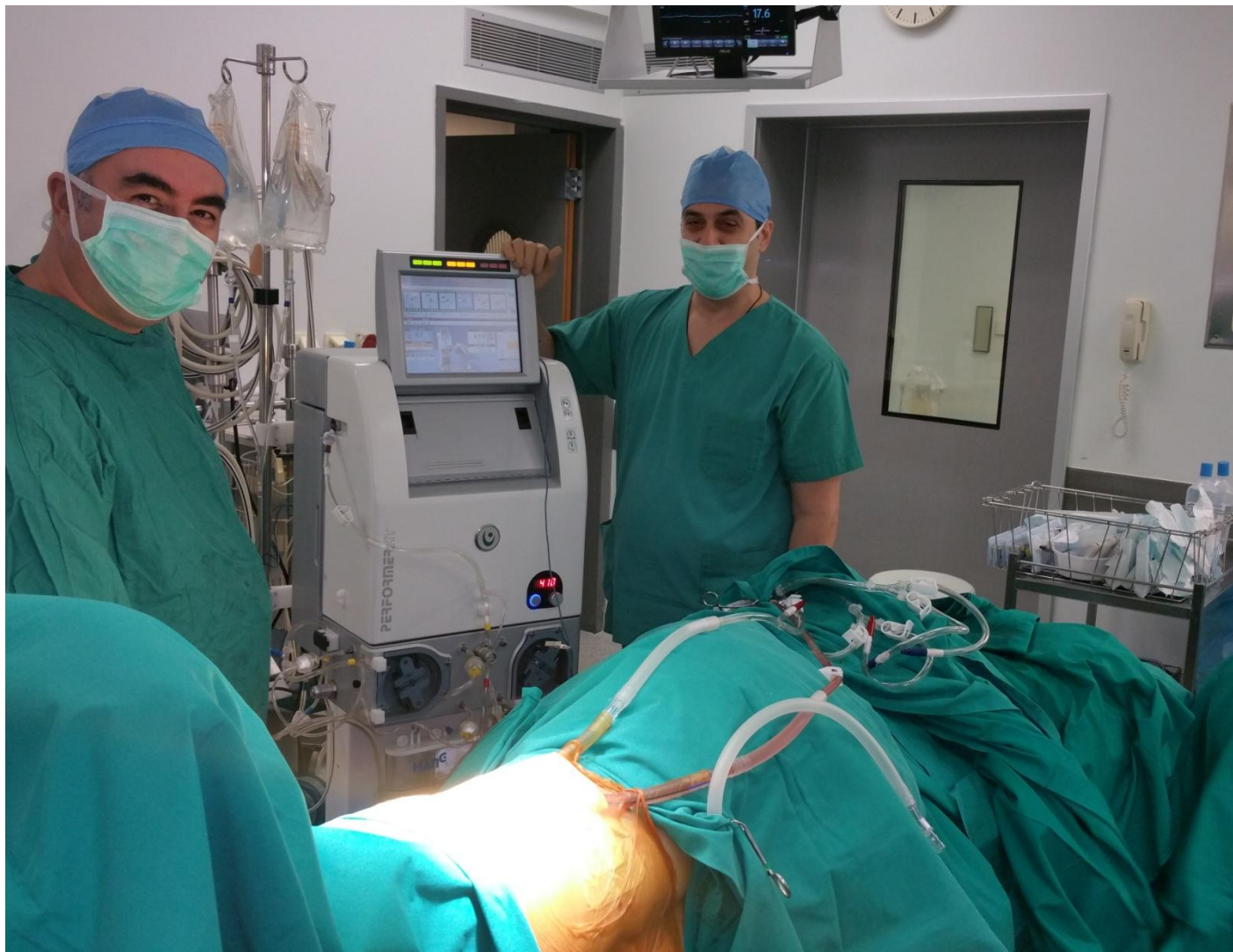Case 3



Surgical field

C C C
a a a
s s s
e e e
1 2 3

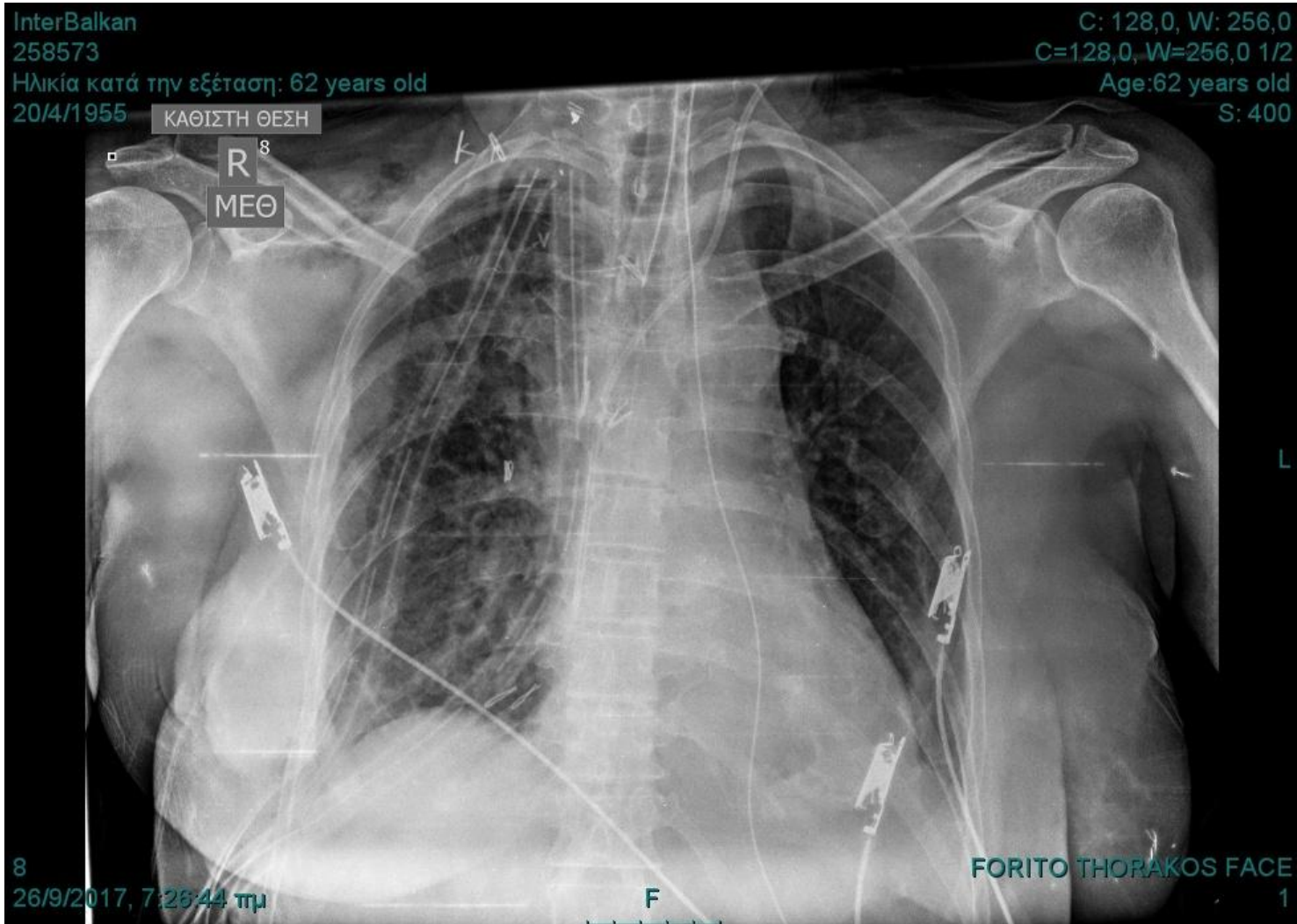
Case 3



Surgical field

C C C
a a a
s s s
e e e
1 2 3

Case 3

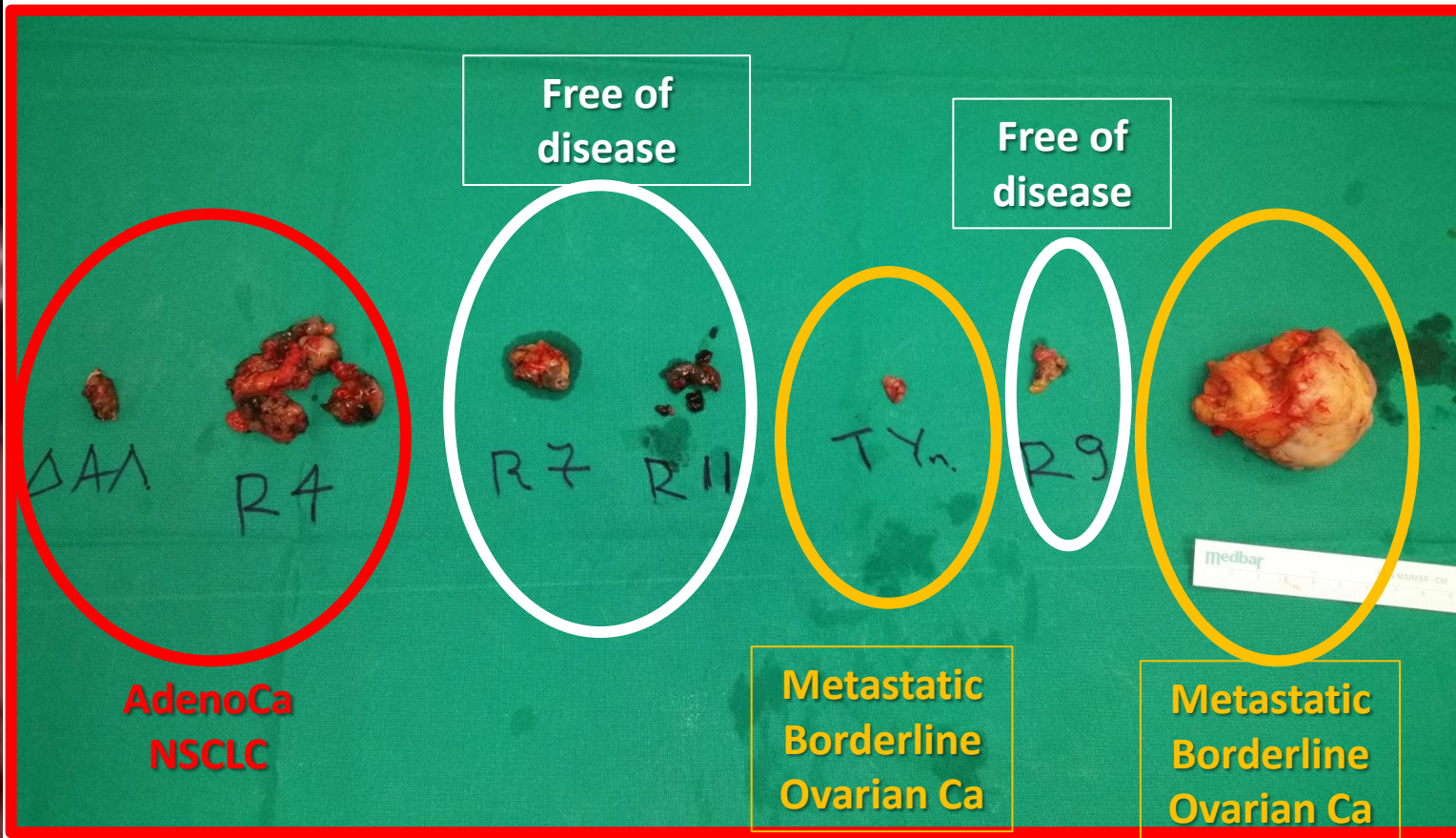


postOp Chest x-ray

C C C
a a a
s s s
e e e
1 2 3

Case 3

C C C
a a a
s s s
e e e
1 2 3



AdenoCa
NSCLC

Free of
disease

Free of
disease

Metastatic
Borderline
Ovarian Ca

Metastatic
Borderline
Ovarian Ca

Surgical field

Case 2

What next?

- 1. Chemotherapy**
- 2. Radiotherapy**
- 3. Immunotherapy**

C C C
a a a
s s s
e e e
1 2 3

Thank U for your attention!

